

Outcome of management of congenital diaphragmatic hernia

AK Saha¹, MB Ali², SK Biswas³

Abstract

Congenital Diaphragmatic Hernia (CDH) is a defect in the dome of diaphragm, more often in left and postero-lateral that permits the herniation of abdominal contents into the thorax. The lungs hypoplasia, pulmonary hypertension and persistent foetal circulation are important determinant of survival. The incidence is <5 in 10,000 live-births. Antenatal diagnosis is often made and this may be helpful in postnatal management. Treatment after birth requires all the refinements of critical care prior to surgical correction. The best hospital series report 80-100% survival. Advances in surgical management include delayed surgical approach that enables preoperative stabilization, improved prenatal diagnosis, introduction of minimal invasive surgery and application of extracorporeal membrane oxygenation in addition to the standard open repair. In our short series survival was 100% where surgical correction was made on selective 12 cases of left sided CDH in a non-ICU set-up.

Bang Med J Khulna 2014; 47 : 12-15

Introduction

Congenital Diaphragmatic Hernia (CDH) is defined by the presence of an orifice in the diaphragm that allows passage of the abdominal viscera into the thorax. The prevalence of congenital diaphragmatic hernia (CDH) ranges between 1:2000 and 1:4000 live births; it accounts for 8% of all major congenital anomalies. Approximately 90% of diaphragmatic defects are posterolateral and 80% are left-sided.¹ The mediastinum is displaced to the contralateral side. The severity of the condition varies widely, the degree of pulmonary hypoplasia and pulmonary hypertension largely determining outcome. Respiratory and cardiovascular functions are severely compromised at birth and this, together with the frequently associated malformations, cause considerable mortality and morbidity. CDH was described many years ago but survival after repair was not achieved until the 20th century.² Gross first reported a series of successful repairs in 1946.³ Increasing knowledge of the pathophysiology of this condition and better perioperative management, several centres are now reporting survival rates >80%.^{4,5}

The aetiology of congenital diaphragmatic hernia is unclear, although 2% is familial and 15% of patients have chromosomal abnormalities. Experimental evidence suggests that pulmonary hypoplasia is the primary defect in congenital diaphragmatic hernia.⁶ Failure of separation of the thoracic and abdominal compartments of the body by closure of embryonic pleuroperitoneal canal during eighth week of gestation results

congenital diaphragmatic hernia (Bochdalek's type).

The affected lung is intrinsically abnormal. The lung is obviously hypoplastic on the side of the hernia, but the contralateral one is also affected to

a variable extent. All stages of lung development will be affected. Lungs with CDH have underdeveloped airways, abnormal differentiation of type II pneumocytes, and a reduced number of pulmonary arteries per unit lung volume. Intrapulmonary arteries become excessively muscularized during gestation with thickened adventitia and media. These pulmonary vessels display an abnormal response to vasoactive substances.⁷

CDH can be detected during fetal life when screening ultrasonography demonstrates herniation of the intestine and/or the liver into the thorax. Polyhydramnios due to kinking of gastroesophageal junction may help to antenatal diagnosis in some severe cases.⁸ Respiratory distress within 24 hours of birth should always be suspicious. Classically these infants have scaphoid abdomen and an asymmetric funnel chest. On auscultation of the lungs reveals poor air entry and shift of the mediastinum to the opposite side.

Diagnosis can be established by a plain X ray of chest with presence of the stomach or loops of bowel within the thoracic cavity along with mediastinal shift away from the side of the lesion.

1. Amar Kumar Saha MS(Ped), Associate Professor of Pediatric Surgery, Khulna Medical College, Khulna

2. Md Barkat Ali DCH, Assistant Professor of Pediatrics, Gazi Medical College, Khulna.

3. Sunil Kumar Biswas DA, Consultant Anaesthetist, General Hospital, Khulna

Right sided defects are more difficult to diagnose. In case of confusion, diagnosis can be confirmed by placing a nasogastric tube in the stomach which also gives symptomatic relief to the patient and contrast GIT series X ray. Computed tomography of the chest also demonstrates diaphragmatic defect. Routine blood examination, blood grouping and cross matching and frequent blood gas analysis are necessary for management.

Extracorporeal membrane oxygenation (ECMO) has been used both as a rescue therapy in those with severe hypoxia after surgical repair and in the stabilisation of infants before and during surgery. Several institutions have reported improvements in survival associated with the use of ECMO, but equally good survival also occurs in centres that do not use ECMO. A recent large UK study, showed that infants who had received ECMO for CDH had a significant mortality in the first year of life, and there was long-term physical and neurodevelopmental morbidity in the majority of survivors.⁹

Surgical repair of CDH was treated as a neonatal emergency until the 1980s. However, repair of the defect does not result in an improvement in gas exchange, and thoracic compliance and PaCO₂ tend to deteriorate in the immediate postoperative period. Most centres now delay surgery for at least 24-48 hours after admission, to allow for a period of clinical stabilization and a fall in pulmonary vascular resistance.¹⁰ Repair is usually achieved via an abdominal incision with gentle reduction of the abdominal viscera from the thorax. The diaphragmatic defect is either closed by primary repair or, in the case of a large defect, using a prosthetic patch through standard open procedure or by minimal invasive surgery.⁴

Postoperatively ventilation should be provided according to the need. Previous concept of routine placement in ICU and ETT ventilation postoperatively resulted in increasing chance of infection and mortality. Some of the pediatric surgical centre in home and abroad successfully repaired (tension free) the defect primarily without post-operative ventilatory support in ICU.⁵ So, aim of this reporting was to share our experience that surgical repair of the pre-operative cardiorespiratory stable patient of CDH can be done in non-ICU setup with hopeful outcome.

Materials and methods

This retrospective study was done in Khulna Shishu Hospital and a private clinic over a period of 6 years from January 2008 to December 2013. Data were collected from patients' hospital records and analysed for age, sex, clinical features, diagnosis, surgical procedure performed, complications and their outcome. Total of 12 patients with congenital diaphragmatic hernia were referred from pediatric practitioners to

surgical unit. All patients got resuscitation after admission, nasogastric suction and prophylactic broad-spectrum antibiotics preoperatively and blood was ready for transfusion prior to surgery. Their ages ranged from 2 days to 2 years and 6 months. All clinically suspected cases were diagnosed preoperatively by abdominal radiology. Only stable patients who are acyanotic with or without traditional nasal tube oxygen inhalation and left sided defect was planned for surgical correction. The hernia was explored per abdominally through left subcostal incision after adequate counseling. Diagnosis was confirmed, defect was identified and isolated. All the herniated abdominal contents were reduced from thoracic to abdominal cavity. Diaphragmatic defects were closed by interrupted prolene stitches. No water-seal drainage or abdominal stretching was done in any case. Oral feeding was started after bowel movement on 2nd or 3rd POD. Plain X ray abdomen and thorax was done on 4th or 5th post-operative day to assess lung expansion. Postoperative followup was given at one week and one month after discharge.

Results

Among 12 cases of CDH, all were posterolateral (Bochdalek's type) and on left side. Age ranges from 2 days to 2 years and 6 months (Table 1). Among them, 8 were males and 4 were females. Male-female ratio was 2:1. Presenting symptom in all cases were respiratory distress except two whose presenting feature was recurrent abdominal distension and vomiting and presentation was late at 2 years 6 months and 8 months.

Table I
Patient profiles

Sl No	Age at present	Side of CDH	Major association	Main symptom
1	7 d	left	Nil	Respi distress
2	2 y 6 m	left	Nil	Recur upper GIT obstruc
3	3 d	left	Nil	Respi distress
4.	8 d	left	Cleft lip	Respi distress
5.	25 d	left	Nil	RTI
6	12 d	left	lipomenin-goccele	Respi distress
7	2 d	left	Nil	Prenatal diagnosis
8	12 d	left	Nil	Respi distress
9	2 d	left	Nil	Respi distress
10	8 m	left	Omphalocele major	Acute intestinal obstruc
11	2 d	left	Nil	Respi distress
12	4 d	left	Nil	Respi distress

The diaphragmatic defect was complete and found on left side in all cases except one where the defect was covered by a thin membrane. Associated congenital anomaly was present in 3 cases. Post operatively oxygen was given to all patients through nasal catheter for 24 hours to 72 hours

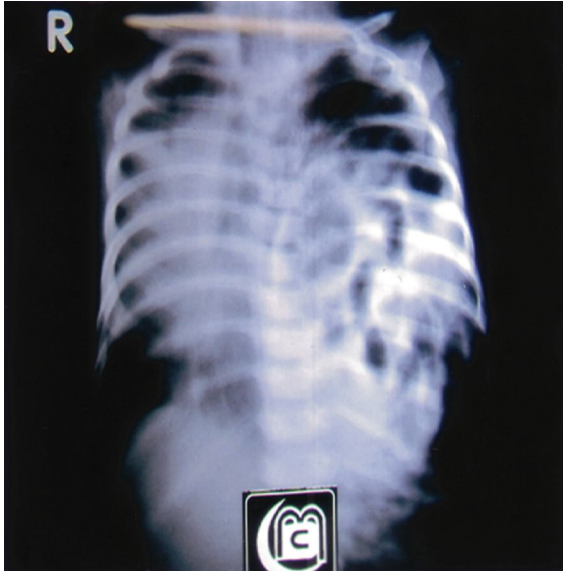


Fig-1. Plain X ray abdomen and Chest showing intrathoracic intestine and mediastinal shifting

but one baby needed additional assisted ventilation with ETT (endo-tracheal tube) and AMBU (artificial manual breathing unit) bag for 24 hours after an transient attack of cyanosis. All babies tolerate feeding well postoperatively after bowel movement.

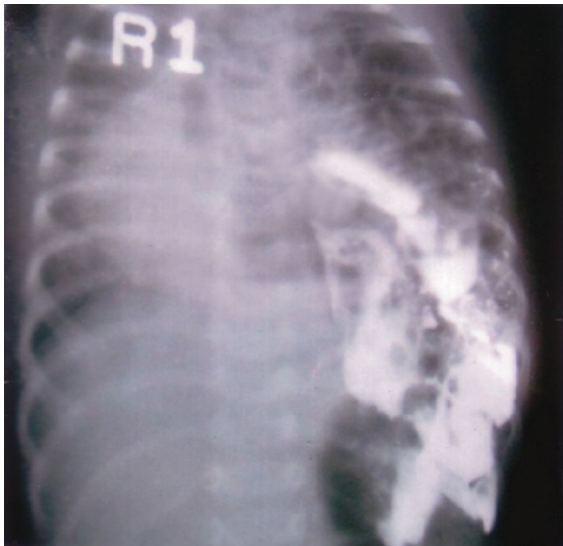

Fig-2. Contrast GIT X ray showing intrathoracic intestine.

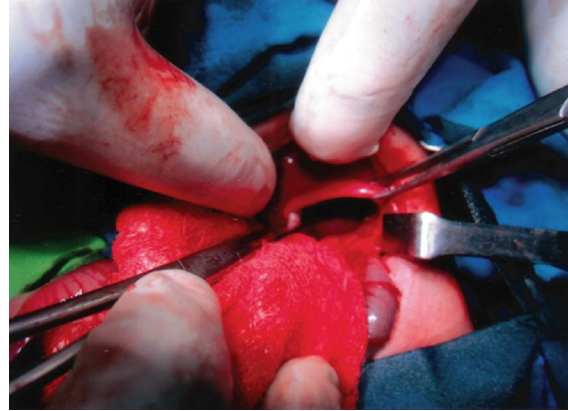


Fig-3. Per-operative view of defect in left dome of diaphragm

Postoperative X-ray showed good lung expansion, correction of mediastinal shifting and no evidence of any pleural effusion. All study cases (n=12) of CDH survived. So survival rate was 100%. No wound complication was reported. During follow-up weight gaining was smooth and uneventful.

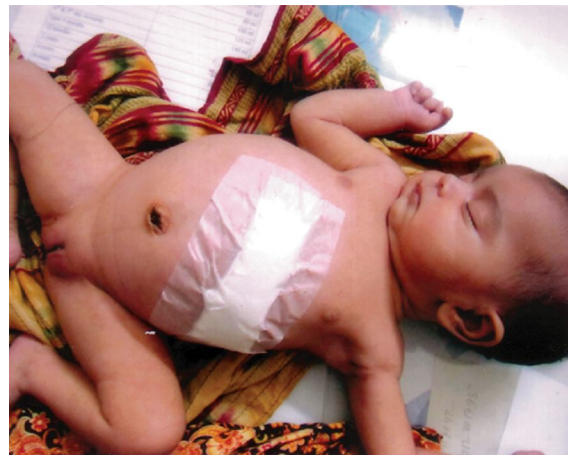

Fig-4. Baby, 5 days after operation

Discussion

Posterolateral (Bochdalek's type) variety is the commonest type of congenital diaphragmatic hernia. Most of the large series reported that 85-90% of CDH were Bochdalek's type and 80-90 % were in left side. All of our cases were this type because we were selectively dealing with left sided CDH. Right sided CDH repair is technically difficult due to presence of liver under right dome. The diaphragmatic defect may be covered by membrane in 10-15% cases. We also detected a CDH with membrane. CDH is more frequent among male. Age of presentation varies from antenatal diagnosis to late childhood or even in

adult. Respiratory distress is the common presenting symptom in neonate. Earlier the presentation, severe the disease & worse will be the prognosis. Late presentation is frequently atypical. In our study two children of 2 year 6 months and 8 months presented with features of recurrent upper GIT obstruction and acute intestinal obstruction respectively. Diagnosis was confirmed all but one cases by plain X ray abdomen and thorax (Fig 1). Atypical presentation may create diagnostic confusion and needs special investigation. Our late presenting case was also diagnosed by upper GIT contrast (Fig 2) series.

Most important preoperative determinant is respiratory stability. The baby should be acyanotic with or without assisted ventilation. The choice of peroperative approach either thoracic or abdominal depends on surgeon but perabdominal approach is preferable. Our approach was perabdominal through left subcostal incision (Fig-4). The diaphragmatic defect (Fig-3) may be closed directly or by prosthesis. We closed the defect directly by interrupted prolene suture. CDH commonly associated with other major anomaly. We found 3 (25%) cases where major anomaly was lipomeningocele, cleft lip and omphalocele major. Most of the long series also reported that this association was 15%-25%.⁵⁻⁷ Post operatively assisted respiration should be provided according to the need. These may vary from oxygen inhalation to artificial ventilation to ECMO. In our series only one baby needed overnight artificial respiration with ETT and AMBU after a transient attack of cyanosis. Oxygen inhalation with traditional nasal tube was given for 24 to 48 hours post operatively in all other cases. No other complication was noted in postoperative period and survival was 100%.

Conclusion

CDH is a surgical disease. But it is a medical rather than surgical emergency. Surgical repair of CDH used to be in the past a life-saving emergency. It is presently accepted that it should

be undertaken only after cardio-respiratory functions are stable. Good prognosis is expected after repair of the defect on a stable patient even in non-ICU setup.

Reference

1. Hannah King, Peter D Booker: Congenital diaphragmatic hernia in the neonate. Continuing Education in Anaesthesia, Critical Care & Pain 2005, 5: pp 171-4
2. Golombek SG: The history of congenital diaphragmatic hernia from 1850s to the present. J Perinatol 2002, 22: 242-6.
3. Gross RE. Congenital hernia of the diaphragm. Am J Dis Child 1946; 71: 579-92.
4. Tovar J A. Congenital Diaphragmatic Hernia- Orphanet Journal of Rare Diseases 2012; 7: 1-15
5. Hanif A, Hasina K, Alam MM: Congenital Diaphragmatic Hernia (CDH): Profile of 21 cases in Dhaka Medical College Hospital. Bangladesh Medical Journal 2010, 39: 32-5
6. Keijzer R, Liu J, Deimling J, Tbbol R, Post M. Dual-hit hypothesis explains pulmonary hypoplasia. in the nitrofen model of congenital diaphragmatic hernia. Am J Pathol 2000; 156: 1299-306.
7. Schnitzer JJ: Control and regulation of pulmonary hypoplasia associated with congenital diaphragmatic hernia- Semin Pediatr Surg 2004,13: 37-43.
8. Sinha CK Islam S, Patel S, Nicolaidis K Greenough A, Davenport M: Congenital diaphragmatic hernia: prognostic indices in the fetal endoluminal tracheal occlusion era. J Pediatr Surg 2009, 44: 312-6.
9. Pandey A, Tandon RK, Kureel SN, Wakhlu A, Rawat J. Evaluation of congenital diaphragmatic hernia in a tertiary health center of a developing country- management and survival. Hemia 2008; 12: 189-92.
10. Charlton A, Bruce J, Davenport M: Timing of surgery in congenital diaphragmatic hernia: low mortality after preoperative stabilization. Anaesthesia 1991, 46: 820-3.
11. Sridhar AV, Nichani S. Late presenting congenital diaphragmatic hernia: Emerg Med J 2004; 21: 261-2.