

Postoperative Perfluoro-N-Octane tamponade for complex retinal detachment surgery

Reza Ali T

*Department of Ophthalmology (Vitreoretina), Bangabandhu Sheikh Mujib Medical University
Shahbag, Dhaka. Email: tariqreza@yahoo.com*

Abstract

Aim: To study outcomes after using perfluoro-n-octane (PFO) as a short-term postoperative vitreous substitute in eyes undergoing primary vitrectomy with or without sclera buckling for complex rhegmatogenous retinal detachments with inferior/multiple breaks or giant retinal tears (GRTs) or retinal detachment with extensive proliferative vitreoretinopathy (PVR). **Methods:** A prospective study was carried out where in 43 patients (Group 1) PFO was exchanged with silicon oil in the same surgical procedure and in 22 patients (Group 2) PFO was kept for 3 days and then exchanged with silicon oil by a separate surgical procedure. The respective surgeon took the decision whether to exchange PFO on the same day or after 3 days. The patients were followed up for 6 months to analyze the anatomical attachment rates, visual acuity gain, and postoperative complications in both the groups. **Results:** There were 33 male and 10 female patients in group 1 and 18 male and 4 female patients in group 2. Mean age distribution in group 1 was 38.88 years ($SD\pm 21.45$) and in group 2 was 38.09 years ($SD\pm 16.36$). Mean preoperative best corrected visual acuity in group 1 was 2.02 ± 0.58 and in group 2 was 2.01 ± 0.53 logarithm of the minimum angle of resolution (LogMAR). The LogMAR Visual acuity in group 1 improved to 1.76 ± 0.43 after 1 month ($P=0.01$, paired t test) and to 1.62 ± 0.62 after 6 months ($P=0.01$, paired T test). This visual acuity in group 2 improved to 1.85 ± 0.42 after 1 month ($P=0.24$, paired T test) and 1.90 ± 0.72 after 6 months ($P=0.49$, paired T test). There was no difference regarding visual improvement in between two groups after 1 month and 6 months of follow-up ($P=0.125$, independent sample T test). The retina was detached in 6 patients (14%) in group 1 and in 7 patients (31%) in group 2 after 6 months of follow-up. There was no statistically significant difference in between two groups regarding final attachment of retina ($P=0.109$, Fisher exact test). There was also no significant complication like increased posterior capsular opacification or glaucoma found after retaining PFO for 3 days. **Conclusion:** Perfluoro-n-octane is efficacious and safe as a short-term vitreous substitute in primary rhegmatogenous retinal detachment repair cases with inferior/multiple breaks or GRTs or with extensive PVR. But keeping perfluoro-n-octane for 3 days does not significantly reduce the risk of re-detachment with complex rhegmatogenous retinal detachment cases.

Introduction

Perfluorocarbon liquid (PFCL) is colourless and odourless, and has a high density and low viscosity. The intraoperative use of PFCL in vitreoretinal surgery was introduced in 1987 by Chang for the treatment of giant retinal tears, retinal detachments with proliferative vitreoretinopathy (PVR), and traumatic retinal detachments.¹⁻⁴ Recently, PFCL has also been used to reposition dislocated crystalline lenses and implanted intraocular lenses (IOLs).⁵⁻⁶ PFCL has also been used when a sub-retinal haemorrhage is removed during surgery for complicated age related macular degeneration.⁷⁻⁸

Initially designed for use as a blood substitute due to their high oxygen-carrying capacity, perfluorocarbon fluids have also been investigated for use in liquid ventilation in preterm infants with

respiratory complications and in adults with acute respiratory distress syndrome. Perfluorocarbon liquids possess a number of characteristics that make them quite useful in vitreoretinal surgery. They have a high specific gravity (1.6-2.1) relative to saline, which results in their excellent retinal tamponade effect. They have a high interfacial tension that makes them cohesive enough to remain as a single large bubble. They are optically clear fluids with refractive indices only slightly different than saline. This slight difference in refractive index allows for easy visibility of the different fluid interfaces. Their boiling point is greater than saline such that endophotocoagulation can be performed without resulting in intraocular vaporization. And they also have low viscosity allowing for easy injection and removal with microsurgical instruments.⁹

A number of commercial perfluorocarbon liquids are available for use in vitreoretinal surgery. Perfluoro-n-octane (Perfluoron, Alcon, Fort Worth, Texas) and perfluoroperhydrophenanthrene (Vitreon, Vitrophage, Lyons, Ill) are 2 perfluorocarbon liquids that have been tested in separate multicenter clinical trials and have been shown to be safe and effective. In a study in which the 2 were compared to each other, the efficacy in terms of retinal reattachment and final visual outcome was similar; however, postoperative retention was found to be greater in the Vitreon group compared with the Perfluoron group.⁹ Although Perfluoron is the perfluorocarbon liquid most commonly used in the United States, Vitreon is also available and has been used with success.

The use of perfluoro-n-octane (PFO) during pars plana vitrectomy (PPV) has improved the anatomical success rate for repair of complex retinal detachments.¹⁰ By facilitating surgical maneuvers, intraoperative PFO is helpful in cases with giant retinal tear (GRT) or proliferative vitreoretinopathy (PVR).¹¹⁻¹²

Although considered to be biologically inert, PFO has not been recommended as a long-term postoperative vitreous substitute because of its potential to compress and disorganize the retina.¹³ This "toxicity" is a physical effect rather than chemical toxicity and depends on the amount of PFO injected. Perfluoro-n-octane is not tolerated in the anterior chamber (AC) and causes corneal edema within 2 or 3 days at the site of contact.¹⁴ Other reported side effects of PFO include intraocular lens opacification, secondary glaucoma, and subretinal migration.¹⁵⁻¹⁶ Recently, there has been some interest in PFO as a postoperatively retained short-term tamponading agent in retinal detachment surgery.¹⁷⁻²⁰

We wanted to find out the probable complications of PFO in terms of visual acuity and retinal re-detachment if it was kept for 3 days and also wanted to compare these effects with similar cases where PFO was exchanged with silicon oil in the same surgical procedure.

Materials and Methods

Eligibility Criteria: This preoperative study was approved by the institutional review board of Ispahani Islamia Eye Institute and Hospital. It was carried out between January 2011 to March 2012. The cases were included according to the following inclusion criteria:

Inclusion criteria:

1. At least 6 months of follow-up was documented.
2. The retinal breaks comprised any of the following:
 - i) A Giant Retinal Tear (a break ≥ 3 retinal clock hours)
 - ii) Breaks of any size or number, so long as at least 1 is located in the inferior retina (between the 5- and 7-o'clock position)
 - iii) ≥ 2 breaks of any size (if not in the inferior retina) located at least ≥ 3 retinal clock hours away from one another (breaks in multiple retinal quadrants).
3. Pars plana vitrectomy with postoperative PFO retention was performed as the primary (initial) retinal reattachment procedure.

Exclusion criteria:

Cases with rhegmatogenous retinal detachments repaired by PPV with postoperative PFO within this time period were excluded if:

1. Macular disease (macular degeneration, diabetic maculopathy, etc.) before retinal detachment was clinically evident or had been previously documented.
2. The case involved either endophthalmitis or a penetrating eye injury.
3. A previous vitrectomy was performed in the study eye for any indication.

So long as the above inclusion and exclusion criteria were met, cases were included in this study regardless of their lens status, refractive error status, presence of PVR, or macular detachment status.

Eyes that had undergone a combined PPV and scleral buckling procedure with postoperative PFO retention were permitted. Surgery was performed by four trained vitreo-retina surgeons. In 43 patients (Group 1) PFO was exchanged with silicon oil in the same surgical procedure and in 22 patients (Group 2) PFO was kept for 3 days and then exchanged with silicon oil by a separate surgical procedure. The respective surgeon took the decision on the operation table whether to exchange PFO on the same day or after 3 days. The patients were followed up for 6 months to analyze the anatomical attachment rates, visual acuity gain, and postoperative complications in both the groups.

Surgical Technique and Postoperative Period:

Eyes underwent a standard 3-port 20-gauge vitrectomy with 360° belt buckle placement. Belt buckle was placed with 5-0 Dacron or passed through a scleral tunnel. Anterior, mid and posterior vitrectomy was done. A posterior vitreous detachment, if not already present, was created using aspiration with the vitrectomy hand piece or

extrusion cannula. High-speed vitreous cutting rates (2,500 cuts per minute) with low vacuum settings were applied using the Accurus Surgical System (Alcon, Inc, Fort Worth, TX) and DORC machine. Vitreous base shaving using a wide-angle viewing system was done in all cases. Subretinal fluid was removed by aspiration through a posterior drainage retinotomy, through the break itself or with the assistance of intraoperative PFO according to surgeon preference. All pre-retinal and subretinal bands were tried to remove. PFO was put to produce a 90% to 99% PFO vitreous cavity fill (Fig. 1, 2). After the retina was flattened, breaks were treated with adequate endolaser photocoagulation (Fig. 3). The sclerotomies and conjunctiva were sutured with 6-0 or 8-0 vicryl. The surgeon decided on the table which cases PFO would be exchanged with the silicon oil on the same day and which cases the PFO would be kept for 3 days (Fig. 4, 5). The cases where PFO was exchanged on the same day were grouped in Group 1 and the others were grouped in Group 2. PFO was exchanged directly with silicon oil; oil was put by the assistant through the infusion cannula after switching off the fluid (Ringer's lactate) flow. All the PFO was removed by back-flush (Flute) needle. Postoperatively these patients (Group 1) were asked to have face down (strict prone) position for 7 days. Patients in Group 2 were instructed to posture on their back for next 72 hours. In these cases, a staged second PPV to remove the PFO was performed after 72 hours with the same procedure described earlier. In few cases additional endolaser was performed to cover the skipped areas. In all SO replacement cases, 1,000-cs silicon oil was used. Care was taken to ensure that all PFO was removed from the eye. An AC paracentesis with cannula aspiration of PFO was performed in all cases with AC PFO migration.




Fig. 1: A case of giant retinal tear Fig. 2: Retina was attached by injecting PFCL

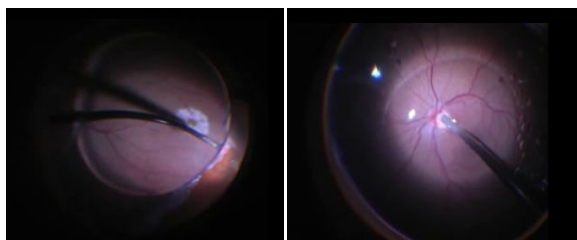


Fig. 3: Adequate laser done Fig. 4: PFCL was replaced by silicon oil

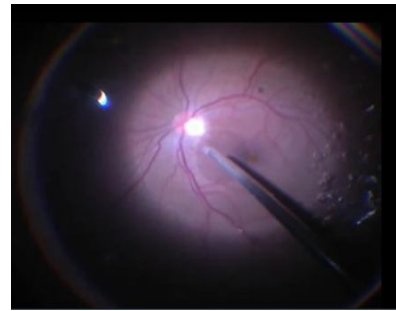


Fig. 5: Last drop of PFCL is being taken out and retina became settled with silicon oil

The preoperative data included the patient's best-corrected visual acuity (BCVA), age, lens status, refractive error status, presence of PVR (Grade B or higher according to the procedure recommended by Machemer et al),²¹ number, size, and position of breaks, and macular detachment status. The postoperative data collected in both groups included whether the retina successfully reattached the length of follow-up, the final documented BCVA, and the development of any complications related to PFO. Postoperative complications assessed included hypotony, increase in intraocular pressure (IOP), cataract progression, intraocular inflammation out of proportion to what was expected from PPV with or without scleral buckling, deposits on the posterior capsule, epiretinal membrane formation, development of cystoid macular edema, PFO migration into the AC or under the retina, and corneal decompensation related to PFO in the AC. The maximum follow-up considered was 19 months.

Outcome Measures:

The primary outcome measure of this study was the BCVA in both the groups at preoperative and postoperative at 1 month and 6 months follow-up. The BCVA was also studied in between the groups after 6 months of follow-up. The secondary outcomes included the anatomical success or reattachment rate after 6 months follow-up from PFO removal in both the groups and occurrence of complications related to PFO use. Anatomical success was defined as complete retinal reattachment at all times during and after the staged primary and secondary procedures without further tertiary vitreoretinal procedures, including additional barrier retinopexy or intraocular gas injections.

Statistical Analysis:

Statistical analysis was performed using SPSS (v16; SPSS, Inc, Chicago, IL). Preoperative and postoperative BCVA in logarithm of the minimum angle of resolution (logMAR) were compared using paired t-test. Binomial categorical variables were compared using the Fisher exact test while other

categorical variables were compared using the chi-square test with Yates correction for continuity. All tests of significance were performed 2-tailed, and a P value, 0.05 was considered statistically significant. Multivariate analyses were attempted only when significance was noted on univariate analyses. Snellen visual acuity was converted into logMAR values as developed by Ferris et al.²² The logMAR values of hand movements visual acuity was assigned +3.0 logMAR and counting fingers visual acuity was assigned +2.0 logMAR according to methods published by Holladay.²³

Results

There were 33 male and 10 female patients in group 1 (Total 43) and 18 male and 4 female patients in group 2 (Total 22). Mean age distribution in group 1 was 38.88 years (SD±21.45) and in group 2 was 38.09 years (SD±16.36) (Fig. 6). 11 of the 43 (25%) eyes in group 1 and 7 of the 22 (31%) in group 2 had high myopia (>6 diopters of myopia). Lens status was noted as: 25 of 43 (58%) in group 1 and 9 of 22 (41%) in group 2 were phakic, 15 of 43 (34%) in group 1 and 11 of 22 (59%) in group 2 were pseudophakic and 3 of 43 (7%) in group 1 and 2 of 22 (9%) in group 2 were aphakic (Table-I). A macula-on RRD was noted in 2 of 43 (4%) eyes in group 1, while no eye in group 2 was found as macula-on.

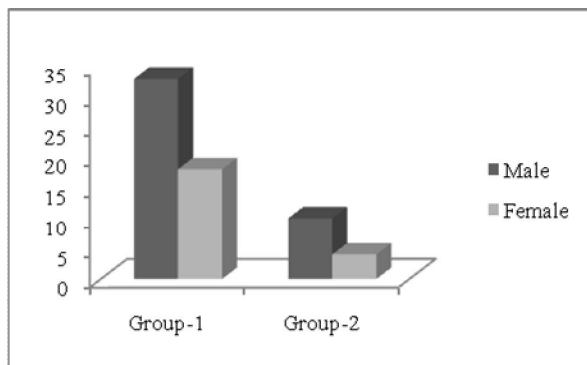


Fig. 6: Shows the sex distribution in two groups

Table I: Baseline evaluation in two groups

Baseline evaluation of participants	Group I (Total 43) Silicon oil exchanged in same surgical procedure	Group II (Total 22) Silicon oil exchanged 3 days after primary surgery
Male	33	18
Female	10	4
Mean age	38.88 years (SD±21.45)	38.09 years (SD±16.36)
Phakic	25 (58%)	9 (41%)
Pseudophakic	15 (34%)	11 (50%)
Aphakic	3 (7%)	1 (9%)

Mean preoperative best corrected visual acuity in group 1 was 2.02±0.58 and in group 2 was 2.01±0.53 logarithm of the minimum angle of

resolution (LogMAR) which was counting finger close to face in Snellen. The logMAR Visual acuity in group 1 improved to 1.76±0.43 after 1 month (1/60 on Snellen, P= 0.55) and to 1.62±0.62 after 6 months (3/60 on Snellen, P=0.12). This visual acuity in group 2 improved to 1.85±0.42 after 1 month (1/60 on Snellen, P=0.65) and 1.90±0.72 after 6 months (<1/60 on Snellen, P=0.12). There was no difference regarding visual improvement in between two groups after 1 month and 6 months of follow-up (P=0.125, paired T test) (Table II & Fig. 7).

Table II: Mean pre and postoperative best corrected visual acuity (BCVA) in two groups:

BCVA	Group I (Total 43) Silicon oil exchanged in same surgical procedure	Group II (Total 22) Silicon oil exchanged 3 days after primary surgery	Statistical analysis
Mean pre-operative BCVA	2.02 (±0.58) logMAR	2.01 (±0.53) logMAR	
Mean post-operative BCVA after 1 month	1.76 (±0.43) logMAR 1/60 on Snellen's Chart	1.85 (±0.42) logMAR 1/60 on Snellen's Chart	P=0.65 Paired t test
Mean post-operative BCVA after 6 month	1.62 (±0.62) logMAR 3/60 on Snellen's Chart	1.90 (±0.72) logMAR 1/60 on Snellen's Chart	P=0.12 Paired t test

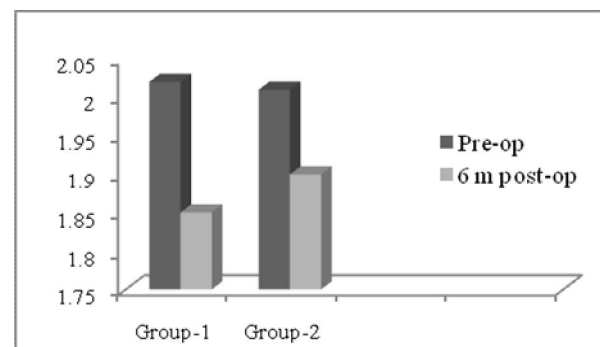


Fig. 7: Preoperative and 6 months postoperative mean logMAR Visual acuity in two groups

The retina was detached in 6 patients (14%) in group 1 and in 7 patients (31%) in group 2 after 6 months of follow-up. There was no statistically significant difference in between two groups regarding final attachment of retina (P=0.109, Fisher exact test). There was also no significant complication like increased posterior capsular opacification or glaucoma found after retaining PFO for 3 days (Table III & Fig. 8).

Table III: Status of the retina after final follow up in two groups:

Status of retina	Group I (Total 43) Silicon oil exchanged in same surgical procedure	Group II (Total 22) Silicon oil exchanged 3 days after primary surgery	Statistical analysis
Detached retina after 6 months	6 (14%)	7 (3%)	P=0.109 Fisher exact test

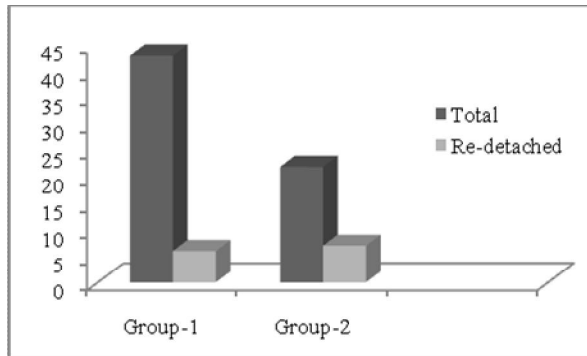


Fig. 8: Rate of retinal redetachment in two groups after silicon oil removal (6 months follow up).

Discussion

Retinal re-detachment after retinal reattachment surgery in eyes with a GRT, extensive PVR, multiple breaks in more than one retinal quadrant, and/or inferior breaks may be attributed in some instances to inadequate or unidirectional (superiorly directed) retinal tamponade with SO or gas, especially when a stringent continuous posturing regimen is not adhered to. In most cases with retinal break configurations as mentioned above, strict facedown posturing for the first few days is considered mandatory. If fluid is permitted to seep back under the edge of the tear before laser/cryoretinopexy has developed into a firm chorioretinal adhesion, the tear may reopen in the postoperative period. Because most patients are able to tolerate postoperative supine posturing better than facedown posturing, perfluorocarbon liquids offer the advantage over both SO and gas in tamponading multiple breaks in more than one retinal quadrant, particularly when an inferior break exists. Other theoretical advantages of postoperative tamponade with perfluorocarbon liquids over SO includes a much higher tamponading force because of its high specific gravity (PFO, 1.76) and its lower viscosity, making it easier to remove from the eye. However, an advantage of postoperative tamponade with SO over perfluorocarbon liquids includes better long-term tolerability. Postoperative tamponade with gas offers an advantage over both SO and perfluorocarbon liquids by not requiring an additional surgical procedure to remove it.

Retinal re-detachment rates of 15% to 45% with or without scleral buckling have been reported in cases with a GRT and/or multiple quadrant breaks when intraoperative PFO with postoperative SO or perfluorocarbon gas tamponade was used.^{10,24} Retinal re-detachment rates of 6% to 22% with or without sclera buckling have been reported in GRT cases when postoperative PFO was retained for 5–14 days.¹⁸⁻¹⁹ In another study showed 22.5% re-detachment after silicon oil exchange in ≥ 4 retinal

break cases.²⁰ Re-detachment rates have varied from 10% to 37.5% when perfluorocarbon liquids other than PFO have been used as postoperative short-term tamponading agents.²⁵

Proliferative vitreoretinopathy has been reported to occur more frequently in cases with a GRT and multiple breaks presumably because of increased vitreous exposure to areas of bare retinal pigment epithelium.²⁶ Researchers have proposed that retinal pigment epithelial cells and mediators of cellular proliferation tend to become concentrated in the residual aqueous fluid around the tamponading agent, which in the upright position lies inferiorly and in the supine position lies in close proximity to the entire retinal surface. Perfluoro-n-octane and other “heavy” liquids should theoretically float these cells and mediators anteriorly off the retinal surface with supine posturing. It is unknown whether postoperative PFO retention clinically reduces the risk of PVR development/progression, as retention is limited only to the short term. A recent retrospective study of 17 eyes with inferior PVR retinal detachments reported an anatomic success rate of 76% (13 of 17) after short-term postoperative PFO retention (3–11 days) with a mean follow-up of 14 months.²⁷ The previous study compared favorably to this report, demonstrating a 91.6% (11 of 12) anatomic success rate in those cases which had PPVR retinal detachments. The high anatomical success rate demonstrated by these studies suggests that PFO could have a protective role. A larger controlled study is necessary to clarify this suggestion.

Our study is the first study which compared the efficacy of PFO if exchanged after the surgery or if exchanged after 3 days. We used only silicon oil in both the situations. Re-detachment was apparently higher (31% vs 14%) in the second group though it was not statistically significant. But the cases where PFO were kept for three days, were supposed to have more PVR than cases where PFO was exchanged on that day. There may be some biasness in this issue. Even though we tried to get the idea whether keeping PFO for few more days brought any long term benefit and if there was any effect on final visual acuity. The re-detachment was higher in second group probably because these cases were more difficult cases to reattach, as previously described.

The safety of postoperative PFO tamponade and its superiority to other perfluorocarbon liquids including perfluoroperhydrophenanthrene and perfluorodecalin has been confirmed by previous studies.^{11,13} However, PFO retained in rabbit eyes was found to induce observable histologic changes including outer plexiform layer thinning and a mild

inflammatory response in the form of macrophages filled with oil-like vacuoles at 1 week in a few of the study eyes. These changes were more commonly seen after 1 or 2 months of PFO retention and were attributed by the investigators to a mechanical effect.¹³ The functional consequences of this mechanical effect remain unascertained (electroretinograms were not performed), and it is uncertain whether this observation can be applied to human subjects. Our study showed that visual acuity improved in both the groups after surgery. The improvement was more obvious and statistically significant in group 1 than 2. Rather in group 2, the vision deteriorated after 6 months than 3 months of follow-up. Again we thought that these were directly not related with PFO retention, rather preoperative 'worse' situation in group 2 may be responsible for this final visual deterioration. There were lots of works regarding the safety of PFO in human eyes. These studies compared final visual acuity preoperatively and postoperatively, suggesting that the mechanical effects of PFO in humans even with a complete fill may not be clinically relevant at least in the short term.

Postoperative intraocular inflammation was managed in all cases with topical anti-inflammatory therapies alone, and there were both groups which the intraocular inflammation was felt to exceed the usual amount of postvitrectomy/scleral buckling inflammation. Postoperative IOP rises were managed in all cases with topical medications alone. Another finding in our study was that PFO retention for 3 days significantly increased macrophage deposits on the lens capsule. Because no difference in redetachment rates was noted between the two groups, the long term usefulness of retention of PFO is not beyond debate, though on the table it gives a better impression to keep the retina attached than exchange in the same sitting.

Recommendation

Our study showed statistically significant improvement of visual acuity if PFO was exchanged on the same day during same surgical procedure. It failed to yield any significant result regarding gaining significant postoperative visual acuity and reducing the risk of postoperative retinal redetachment after 6 months if PFO was exchanged 3 days after the primary surgery. Even, in cases with complex retinal detachment with GRT or inferior detachment or with extensive PVR, the surgeons can decide to keep the PFO for 3 days to avoid the stormy situation of retinal redetachment at the table during silicon oil exchange in the same sitting.

References

1. Chang S. Low viscosity liquid fluorochemical in vitreous surgery. *Am J Ophthalmol* 1987; 103: 38-43.
2. Chang S, Lincoff H, Zimmerman NJ, et al. Giant retinal tears: surgical techniques and results using perfluorocarbon liquid. *Arch Ophthalmol* 1989; 107:761-6.
3. Chang S, Ozmert E, Zimmerman NJ. Intraoperative perfluorocarbon liquid in the management of proliferative retinopathy. *Am J Ophthalmol* 1988; 106:668-74.
4. Chang S, Reppucci V, Zimmerman NJ. Perfluorocarbon liquid in the management of traumatic retinal detachment. *Ophthalmology* 1989; 96:785-92.
5. Lui K, Peyman GA, Chen M, et al. Use of high-density vitreous substitutes in the removal of posteriorly dislocated lenses or intraocular lenses. *Ophthalmic Surg* 1991; 22:503-7.
6. Shapiro MJ, Resnick KI, Kim SH, et al. Management of dislocated crystallin lens with a perfluorocarbon liquid. *Am J Ophthalmol* 1991; 112:401-5.
7. Kamei M, Tano Y, Maeno T, et al. Surgical removal of submacular hemorrhage using tissue plasminogen activator and perfluorocarbon liquid. *Am J Ophthalmol* 1996; 121:267-75.
8. Desai UR, Peyman GA, Chen CJ, et al. Use of perfluoroperhydrophenanthrene in the management of suprachoroidal hemorrhage. *Ophthalmology* 1992; 99: 1542-7.
9. Loewenstein A, Humayun MS, de Juan E Jr, Campochiaro PA, Haller JA. Perfluoroperhydrophenanthrene versus perfluoro-n-octane in vitreoretinal surgery. *Ophthalmology* 2000; 107:1078-82.
10. Scott IU, Murray TG, Flynn HW Jr, et al. Outcomes and complications associated with perfluoro-n-octane and perfluoroperhydrophenanthrene in complex retinal detachment repair. *Ophthalmology* 2000; 107:860-65.
11. Scott IU, Murray TG, Flynn HW Jr, et al. Perfluoron Study Group. Outcomes and complications associated with giant retinal tear management using perfluoro-n-octane. *Ophthalmology* 2002; 109:1828-33.
12. Scott IU, Flynn HW Jr, Murray TG, Feuer WJ. Perfluoron Study Group. Outcomes of surgery for retinal detachment associated with proliferative vitreoretinopathy using perfluoro-n-octane: a multicenter study. *Am J Ophthalmol* 2003; 136:454-63.
13. Chang S, Sparrow J, Iwamoto T, et al. Experimental studies of tolerance to intravitreal perfluoro-n-octane liquid. *Retina* 1991; 11:367-74.
14. Peyman GA, Schulman JA, Sullivan B. Perfluorocarbon liquids in ophthalmology. *Surv Ophthalmol* 1995; 39:375-395.
15. Prasad PS, Oliver SC, Gonzales CR. Midlenticular optic opacification of a hydrophobic acrylic intraocular lens in association with retained perfluorocarbon liquid following vitreoretinal surgery. *Ophthalmic Surg Lasers Imaging* 2010; 9:1-2.

16. Toffoli D, Arbour JD, Harasymowycz P. Retained perfluoron postvitrectomy surgery causing secondary open-angle glaucoma. *Can J Ophthalmol* 2008; 43:372.
 17. Lai JC, Postel EA, McCuen BW 2nd. Recovery of visual function after removal of chronic subfoveal perfluorocarbon liquid. *Retina* 2003; 23:868-70.
 18. Rofail M, Lee LR. Perfluoro-n-octane as a postoperative vitreoretinal tamponade in the management of giant retinal tears. *Retina* 2005; 25:897-901.
 19. Sirimaharaj M, Balachandran C, Chan WC, et al. Vitrectomy with short term postoperative tamponade using perfluorocarbon liquid for giant retinal tears. *Br J Ophthalmol* 2005; 89: 1176-1179.
 20. Rush R, Sheth S, Surka S, et al. Postoperative perfluoro-n-octane tamponade for primary retinal detachment repair. *Retina* 2012; 32: 1114-20
 21. Machemer R, Aaberg TM, Freeman HM. An updated classification of retinal detachment with proliferative vitreoretinopathy. *Am J Ophthalmol* 1991; 112: 159-65.
 22. Ferris FL, Kassoff A, Bresnick GH, Bailey I. New visual acuity charts for clinical research. *Am J Ophthalmol* 1982; 94:91-6.
 23. Holladay JT. Proper method for calculating average visual acuity. *J Refract Surg* 1997; 13: 388-91.
 24. Verstraeten T, Williams G, Chang S, et al. Lens-sparing vitrectomy with perfluorocarbon liquid for the primary treatment of giant retinal tears. *Ophthalmology* 1995; 102:17-20.
 25. Millsap CM, Peyman GA, Mehta NJ, et al. Perfluoroperhydrophenanthrene (Vitreon) in the management of giant retinal tears: results of a collaborative study. *Ophthalmic Surg* 1993; 24: 759-62.
 26. Bottoni F, Bailo G, Arpa P, et al. Management of giant retinal tears using perfluorodecalin as a postoperative short-term vitreoretinal tamponade: a long-term follow-up study. *Ophthalmic Surg* 1994;25:365-73.
 27. Drury B, Bourke RD. Short-term intraocular tamponade with perfluorocarbon heavy liquid. *Br J Ophthalmol* 2011; 95: 694-98.
-