

## Triple-phase Multidetector Computed Tomography: An Evaluation of Hepatic Space Occupying Lesion in Cirrhotic Patients

Hasinuzzaman RTM<sup>1\*</sup>, Roy SK<sup>2</sup>, Hossain MS<sup>2</sup>, Paul FN<sup>3</sup>, Akter M<sup>4</sup>, Barua S<sup>5</sup>

<sup>1</sup>Rangpur Medical College Hospital, Rangpur, Bangladesh

<sup>2</sup>Sir Salimullah Medical College & Mitford Hospital, Dhaka, Bangladesh

<sup>3</sup>250 Bedded TB Hospital Shaymoli, Dhaka, Bangladesh

<sup>4</sup>Upazila Health Complex, Dohar, Dhaka, Bangladesh

<sup>5</sup>Chattogram Medical Collage, Chattogram, Bangladesh

### Abstract

Hepatocellular carcinoma (HCC) is a common tumor with an incidence of 1 - 6 % among cirrhotic patients. Dysplastic nodule often occurs within regenerative cirrhotic nodules. They can show low or high grade dysplasia. MRI best differentiates this iso or hypo intense lesion from hyper intense HCC. The current study was designed to assess the usefulness of Triple-phase multiphasic multidetector computed tomography (MDCT) in evaluation of hepatic space occupying lesion in cirrhotic patients. This cross sectional study was carried out in the Radiology and Imaging department in collaboration with Hepatology and Hepatobiliary surgery department, of Bangabandhu Sheikh Mujib Medical University, Dhaka during July 2014 to June 2016. A total of 62 cirrhotic patients with hepatic space occupying lesion were included in this study. MDCT was done in all these patients and they were followed-up from the admission up to post operative tissue diagnosis of hepatic space occupying lesion in respective pathology departments to assess the histopathological correlation. Patients with suspected hepatic space occupying lesion diagnosed by clinical and ultrasonography and having high serum  $\alpha$ -fetoprotein level were enrolled. The mean age was 50.0 $\pm$ 13.6 years with ranged from 25 to 79 years. Male female ratio was 2.3:1. In MDCT, a total of 54 malignant cases were to be found, out of which 49(79.0%) patients had HCC, 4(6.5%) had metastases and 1(1.6%) had dysplastic nodule. In benign tumor group, 6(9.7%) patients had cirrhotic nodule, 1(1.6%) had hepatic adenoma and 1(1.6%) had haemangioma. In histopathology, a total 53 malignant cases were found, out of them 48(77.5%) patients had HCC, 3(4.8%) had metastases and 2(3.2%) had dysplastic nodule. Triphasic MDCT in diagnosis of hepatic space occupying lesion in cirrhotic patients revealed a sensitivity of 98.1%, specificity of 77.8%, accuracy 95.2%, positive predictive values 96.3% and negative predictive values 87.5%. While the same diagnostic tool showed a sensitivity 95.8%, specificity 78.6%, accuracy 91.9%, positive predictive values 93.9% and negative predictive values 84.6% in identification of HCC. In evaluation of metastasis MDCT had a sensitivity of 100.0%, specificity 98.3%, accuracy 98.4%, positive predictive values 75.0% and negative predictive values 100.0%. In evaluation of dysplastic nodule MDCT had sensitivity 50.0%, specificity 100.0%, accuracy 98.4%, positive predictive values 100.0% and negative predictive values 98.4%. So, MDCT can be an ideal diagnostic tool for detecting as well as characterizing the hepatic space occupying lesion (SOLs) in cirrhotic patients.

**Keywords:** Multidetector computed tomography, Hepatic space, Hepatocellular carcinoma

### Introduction

Cirrhosis refers to a progressive, diffuse, fibrosing, nodular condition that disrupts the entire normal architecture of the liver.<sup>1</sup>

Hepatocellular carcinoma (HCC) is a common tumor with an incidence of 1-6 % among cirrhotic patients.<sup>2</sup> Risk factors include cirrhosis, alcohol, HBV, HCV, metabolic liver diseases, environmental carcinogens, hormonal treatments

and smoking.<sup>3</sup> About 90-95% of HCC arise in cirrhotic livers. Autopsy studies indicate that 20 - 40% of patients with cirrhosis have HCC.

Dysplastic nodule often occurs within regenerative cirrhotic nodules. They can show low or high grade dysplasia. A progression from regenerative nodule with low grade dysplasia, high grade dysplasia, well differentiated and poorly differentiated HCC is possible. MRI best differentiates this iso-or hypo intense lesion from hyper intense HCC.<sup>4</sup>

Although, liver metastasis is a rare finding in cirrhosis, on CT-scan, colorectal metastases appear as low attenuation lesions, often with irregular margins and necrotic centres. During the early vascular phase of dynamic CT, metastasis appears with increased enhancement. The sensitivity of CT (85%) can be augmented by CT arterial portography.<sup>5</sup>

Among the benign lesions haemangioma is found in 20% of the general population, more commonly in women.<sup>6</sup> Contrast enhanced CT or MRI is the best modalities for the diagnosis. Other very rare benign tumors in cirrhosis includes: hepatobiliary cyst adenoma, bile duct adenoma (cholangioma), biliary papillomatosis, lipomas, myolipomas, angiomyolipomas, schwannomas, neurofibromas and chondromas, inflammatory pseudotumor and pseudo-lesions.

Nodularity, irregularity, increased echogenicity, and atrophy are ultrasonographic hallmarks of cirrhosis. The discovery of hepatic nodules via ultrasonography warrants further evaluation because benign and malignant nodules can have similar ultrasonographic appearances.<sup>7</sup> A study using high-resolution ultrasonography in patients with cirrhosis confirmed with biopsy or laparoscopy found a sensitivity and specificity for cirrhosis of 91.1 and 93.5 percent, respectively, and positive and negative predictive values of 93.2 and 91.5 percent, respectively.<sup>8</sup>

CT and magnetic resonance imaging (MRI) generally are poor at detecting morphologic changes associated with early cirrhosis, but they can accurately demonstrate nodularity and lobar atrophic and hypertrophic changes, as well as ascites and varices in advanced disease. CT portal phase imaging can be used to assess portal vein patency, although flow volume and direction cannot be determined accurately.<sup>9</sup>

A study reported that MRI can accurately diagnose cirrhosis and provide correlation with its severity.<sup>10</sup> Despite the potential of MRI and MRA in the diagnosis and evaluation of patients with cirrhosis, their widespread use is limited by their expense and by the ability of routine ultrasonography with Doppler to obtain adequate information for the diagnosis of cirrhosis and

presence of complications. Ultrasound contrast agents and MRI using iron or gadolinium contrast better detect smaller lesions, satellite lesions or distant metastasis.<sup>11</sup> FDG PET CT scan is not very useful for HCC and therefore is not the best imaging modality to distinguish benign from malignant lesions.<sup>12</sup>

The gold standard for detection and location of focal lesions in cirrhosis is enhanced MRI or triple phase dynamic spiral CT. Conventionally a triple phase CT scan includes unenhanced, arterial and venous phases. The fourth phase is a delayed venous scan (quadruple phase multi detector computed tomography).<sup>13</sup> This is only required for small lesions thought to be HCC or cysts and hemangiomas. Radiographic characteristics favoring hepatocellular carcinoma include the presence of a lesion with different densities, arterial hyper vascularisation and venous wash-out.

With the improvement of imaging modalities recently triple-phase MDCT scan has emerged as a highly sensitive non-invasive method to diagnose hepatic space occupying lesion in cirrhotic patients in developed countries. However, a very few studies have been conducted in our country to observe the ability of this method to detect HCC despite high prevalence of the malignancy here. Due to ignorance of the patient's people are misguided by various types of diagnostic procedures. Maximum people of our country lives below the standard level of economical parameter. So, it needs try to formulate an affordable and available diagnostic procedure for them to evaluate the hepatic space occupying lesion in cirrhotic patients. This study will help the people to save their hard earnings as well as the policy makers to take proper action in such patients. The current study was designed to look at usefulness of Triple-phase multiphasic multidetector computed tomography (MDCT) in evaluation of hepatic space occupying lesion in cirrhotic patients.

## Materials and methods

This cross sectional study was carried out in the Department of Radiology and Imaging, Bangabandhu Sheikh Mujib Medical University (BSMMU), Dhaka in collaboration with

Department of Hepatology and Department of Hepatobiliary Surgery of the same university, during the period of July 2014 to June 2016. A total of 62 cirrhotic patients with hepatic space occupying lesion who underwent triple-phase multidetector computed tomography (MDCT). Prior to the commencement of the study, ethical clearance was obtained from the Institutional Ethical Committee of the BSMMU.

Cirrhotic patient with suspected hepatic space occupying lesion diagnosed by clinical and ultrasonography and having high serum  $\alpha$ -fetoprotein level were included in the study. Patients having diffuse liver disease, cardiac disease and pregnant women with suspected liver disease, iodinated contrast administration in the previous 48 hours, lithotripsy in the previous 72 hours and liver biopsy in the previous 24 hours; and with hypersensitivity to CT contrast agents and patients in whom CT is contraindicated due to any other reason. Patient nonavailable for follow-up were also excluded from the study.

All CT scan examination was performed with a 64 slice multidetector Hitachi Scenaria whole body scanner using standard technical parameters. Triple phase MDCT protocol was maintained. Renal function test was assessed before selecting them for post-contrast examination. Then both pre and post contrast scans was performed. At first a noncontrast scan was taken. Before giving IV contrast, the patient was given water soluble oral contrast medium (iodinated contrast medium of 370 strength). Then 1 mg/kg body weight (about 60-65 ml) of nonionic water soluble contrast medium (Inj Iopamiro, 370 strength) was injected in anticubital vein by dual head automated injector. The arterial phase of scanning began 10 secs after the start of bolus, second phase (portal venous phase or redistribution phase) 25 secs after the start of bolus & the last phase (hepatic venous) began at 60 secs (delayed images can be taken up to 10-15mins). 10 mm contiguous slices were obtained through the upper abdomen in craniocaudal direction during single breath hold.

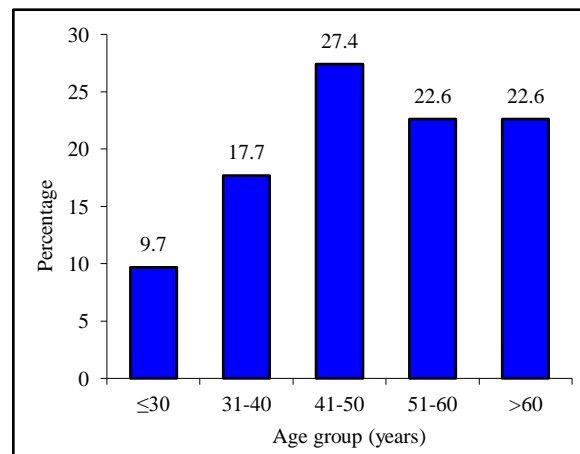
CT scans were reviewed to detect mass in cirrhotic liver as well as to characterize them into either benign or malignant by looking radiological signs. Histopathology was done in all cases and patients

were followed up to final diagnosis. Finally CT scan reports were compared with histopathological diagnosis.

CT findings were recorded in a pre-designed, structured data collection sheet. Histopathological diagnosis was recorded. Statistical analyses of the results were obtained by using window based computer software devised with Statistical Packages for Social Sciences (SPSS V.16.0). The results were presented in tables, figures, diagrams. For the validity of study outcome, sensitivity, specificity, accuracy, positive predictive value and negative predictive value of triple phase multidetector computed tomography (MDCT) in the diagnosis of hepatic space occupying lesions (SOL) were calculated. A *p* value <0.05 was considered as significant.

## Results

The mean age of cirrhotic patients with hepatic SOL was found  $50.0 \pm 13.6$  years with ranged from 25 to 79 years. More than one fourth (27.4%) patients belonged to age 41-50 years (figure-1).

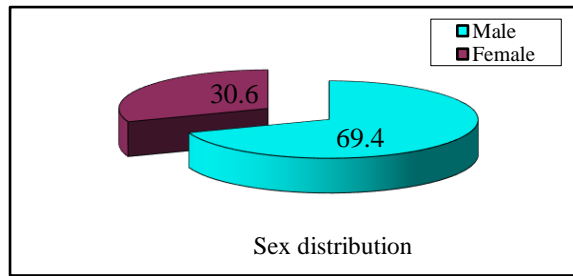


**Figure 1:** Age distribution of the patients.

The mean age was found  $50.0 \pm 13.6$  years with range from 25 to 79 years. More than two third (69.4%) patients were male and 19(30.6%) were female. Male female ratio was 2.3:1. Male female ratio was 2.3:1 (figure-2).

Triphasic MDCT as a tool in diagnosis of hepatic space occupying lesion in cirrhotic patients showed a sensitivity of 98.1%, specificity 77.8%, accuracy 95.2%, positive predictive values 96.3% and negative predictive values 87.5% (figure II)

More than two third (69.4%) patients were male and 30.6% were female.



**Figure 2:** Sex distribution of the patients

In triphasic MDCT diagnosis of the study patients, it was observed that in malignant tumor, 49 (79.0%) patients had HCC, 4 (6.5%) had metastases and 1 (1.6%) dysplastic nodule. In benign tumor, 6 (9.7%) patients had regenerative nodule, 1 (1.6%) hepatic adenoma and 1 (1.6%) had haemangioma (table I).

**Table I:** Distribution of the study population by triphasic MDCT diagnosis (n=62)

Triphasic MDCT diagnosis	Number of patients	Percentage
Malignant (n=54)		
HCC	49	79.0
Metastases	4	6.5
Dysplastic nodule	1	1.6
Benign (n=8)		
Regenerative nodule	6	9.7
Hepatic adenoma	1	1.6
Haemangioma	1	1.6

In this study, the lesions were hypodense in 40.3%, isodense in 27.4%, mixed in 21.0% and hyperdense in 11.3%. In arterial phase, hyperdensity was found in 75.8%, isodensity in 17.7% and hypodensity in 6.5%. Regarding enhancement in portal venous phase, hyperdensity was found in 61.3%, isodensity in 30.6%, hypodensity with enhancing rim in 4.8% and hypodensity in 3.2%. Enhancement in hepatic venous phase, lesions were hypodense in 83.9%, isodense in 11.3% and hyperdense in 4.8%. More than two third (69.4%) patients were found having hypervascular component in arterial phase and 59.7% patients showed interlesional contrast washout in portal venous phase. By triphasic MDCT, out of 62 patients a total 54 malignant cases were found, out of which 49(79.0%) patients had HCC, 4(6.5%), had metastases and 1(1.6%) dysplastic nodule. In benign tumor, 6(9.7%)

patients had cirrhotic nodule, 1(1.6%) hepatic adenoma and 1(1.6%) had haemangioma(table I). In histopathology, a total 53 malignant case was found, out of them 48(77.5%) patients had HCC, 3(4.8%) had metastases and 2(3.2%) dysplastic nodule. In benign tumor, 7(11.3%) patients had cirrhotic nodule, 1(1.6%) hepatic adenoma and 1(1.6%) had haemangioma(table II).

**Table II:** Distribution of the study patients by histopathological diagnosis (n=62)

Histopathological diagnosis	No. of patients	Percentage
Malignant (n=53)		
HCC	48	77.5
Metastases	3	4.8
Dysplastic nodule	2	3.2
Benign (n=9)		
Regenerative nodule	7	11.3
Hepatic adenoma	1	1.6
Haemangioma	1	1.6

Histopathological diagnosis of the study patients, it was observed that in malignant tumor, 48(77.5%) patients had HCC, 3(4.8%) had metastases and 2(3.2%) dysplastic nodule. In benign tumor, 7(11.3%) patients had regenerative nodule, 1(1.6%) hepatic adenoma and 1(1.6%) had haemangioma (table II).

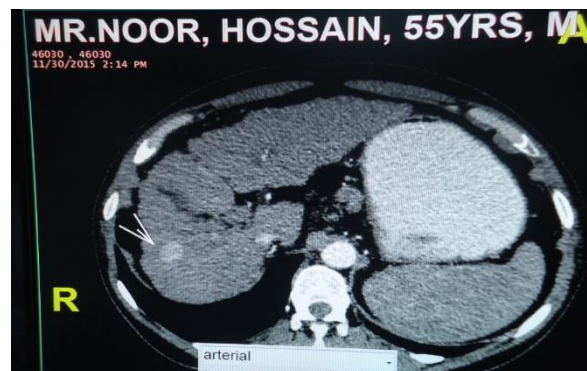


Figure 3a

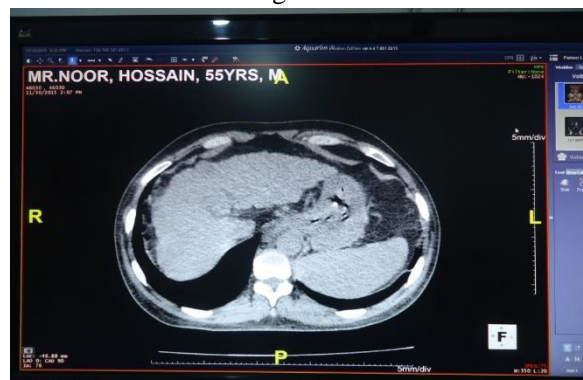

Figure 3b

**Figure 3:** Axial precontrast (IIIa) and postcontrast (IIIb) arterial phase MDCT scan showing hypervascular nodular lesion in right lobe of liver

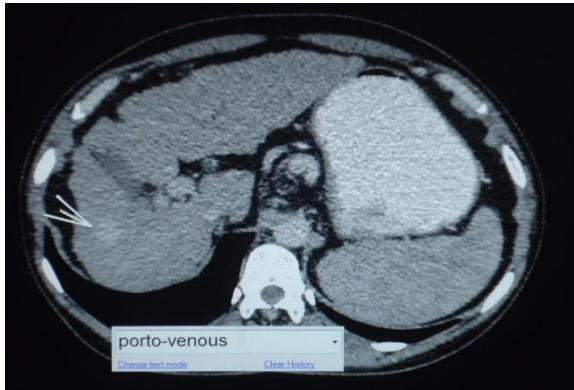

Figure 4a

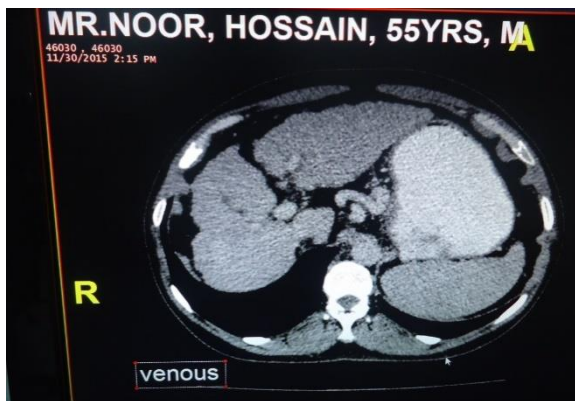
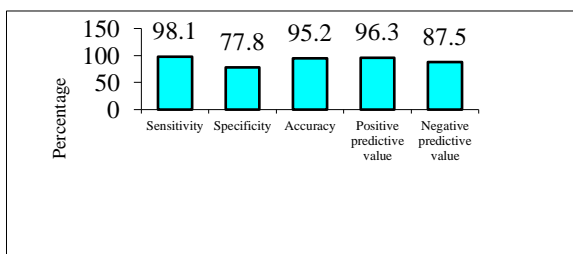


Figure 4b

**Figure 4:** Axial postcontrast portovenous (4a) and venous phase (4b) MDCT scan showing subsequent contrast washout from the lesion which highly suggestive of HCC.



**Figure 5:** Sensitivity, specificity, accuracy, positive and negative predictive values of the triphasic MDCT diagnosis evaluation for hepatic space occupying lesion in cirrhotic patients.

In case of identification of HCC in hepatic space occupying lesions in cirrhotic patients the sensitivity of triphasic MDCT was 95.8%, specificity 78.6%, accuracy 91.9%, positive predictive values 93.9% and negative predictive values 84.6%. In evaluation of metastasis, MDCT had sensitivity of 100.0%, specificity 98.3%,

accuracy 98.4%, positive predictive values 75.0% and negative predictive values 100.0%. In evaluation of dysplastic nodule MDCT had sensitivity of 50.0%, specificity 100.0%, accuracy 98.4%, positive predictive values 100.0% and negative predictive values 98.4%.

### Discussion

In this present study, it was observed that more than one fourth (27.4%) patients were in 5<sup>th</sup> decade. The mean age was found 50.0±13.6 years with ranged from 25 to 79 years. Similarly, Zaky et al found the mean age was 51 years with ranged from 40 to 70 years.<sup>14</sup> In another study, Hafeez et al observed the mean was 46.5 ± 13.4 years and all the patients of age over 18 years with suspected focal hepatic lesion.<sup>15</sup> On the other hand, Laghi et al found the age range varied from 48-77 years with mean age 61 years.<sup>16</sup> The higher mean age and age range maybe due to geographical variations, racial, ethnic differences, genetic causes, different lifestyle, and increased life expectancy may have significant influence on hepatic space occupying lesion in cirrhotic patients.

In this study, it was observed that more than two third (69.4%) patients were male and 30.6% were female. Male female ratio was 2.3:1. Hafeez et al found there were 68.3% males and 31.6% females, which is closely resembled with the present study. Similarly, Laghi et al and Zaky et al were also found male predominance in their respective studies.

Of the density of lesions, hypodense 40.3%, isodense in 27.4%, mixed in 21.0% and hyperdense in 11.3%. Li et al reported that most were isodense or hypodense in unenhanced scan with mostly hyperdense or isodense in arterial phase and mostly iso or hypodense in delayed portal venous phase.<sup>17</sup> In another study, Yaqoob et al found that 81.0% hyperattenuating, 15.0% isoattenuating and 3.5% hypoattenuating in arterial phase.<sup>18</sup> The portal venous phase images showed hyperattenuation 2.3%, isoattenuation 49.0% and hypoattenuation 48.0%. The above study findings closely resemble with the current study.

In this study, it was observed that in malignant tumor, 79.0% patients had HCC, 6.5% had

metastases and 1.6% dysplastic nodule. In benign tumor, 9.7% patients had cirrhotic nodule, 1.6% hepatic adenoma and 1.6% had haemangioma. Caturelli showed that 69% of new nodules in a cirrhotic liver are malignant.<sup>19</sup> Moreover, liver cell dysplasia is found in 60% of cirrhotic livers containing hepatocellular carcinoma and in only 10% of non-cirrhotic livers.<sup>20</sup>

In the present study, it was observed that in case of detection of HCC in cirrhotic patients triphasic MDCT showed a sensitivity of 95.8%, specificity 78.6%, accuracy 91.9%, positive predictive values 93.9% and negative predictive values 84.6%. In evaluation of Metastasis, MDCT had sensitivity 100.0%, specificity 98.3%, accuracy 98.4%, positive predictive values 75.0% and negative predictive values 100.0%. In evaluation of dysplastic nodule, MDCT had sensitivity 50.0%, specificity 100.0%, accuracy 98.4%, positive predictive values 100.0% and negative predictive values 98.4%. Laghi et al reported that the average sensitivity and positive predictive values, respectively, for the detection of HCC were 48.5% and 96.4% for early arterial phase images, 87.1% and 94.0% for late arterial phase images, 87.1% and 94.0% for images from both arterial phases, and 88.5% and 93.4% for images from all three phases. Hafeez et al reported in their study that triple phase CT scan has a sensitivity of 100.0%, specificity of 80.0%, positive predictive value 94.5%, negative predictive value 100.0% and diagnostic accuracy of 95.5% in differentiating benign from malignant liver lesion.<sup>14</sup> Dai et al evaluate the diagnostic value sensitivity 80.4% and specificity 97.9%, accuracy 88.4%. Giorgio et al. found sensitivity 91.9%. Snow et al found CT sensitivity 96.0%, specificity 86.0%, and accuracy 91.0%. So the validity parameter of this study is more or less very close to that of previous studies.

## Conclusion

Histopathological diagnosis of hepatic space occupying lesions in cirrhotic patients in this study is significantly well associated with triple-phase multidetector computed tomography (MDCT) assumption. It may be concluded that the triple-phase multidetector computed tomography (MDCT) is a useful, reliable, efficient as well as handy or affordable diagnostic

modality for the patients which enables characterization of a wide range of hepatic space occupying lesions in cirrhotic patients and can be used to plan the subsequent appropriate management in majority of cases. As the present study was conducted with a small sample size, a large scale multicentric study with more logistic support and adequate randomization is recommended.

## References

1. Friedman S, Schiano T. Cirrhosis and its sequelae. In: Goldman L, Ausiello D, eds. Cecil Textbook of Medicine. 22nd ed. Philadelphia, Pa.: Saunders, 2004: 936-44P
2. Sherman, M. Screening for hepatocellular carcinoma, Hepatology Research. 37,152-65.
3. Simonetti RG, Camma C., Fiorello F, Politi F, Amico G., Pagliaro L. Hepatocellular carcinoma. A worldwide problem and the major risk factors. Digestive Diseases and Sciences. 36:962-72.
4. Hussain, SM, Zondervan, PE, Schalm, SW, de Man RA, Krestin GP. Benign versus malignant hepatic nodules: MR imaging findings with pathologic correlation Radiographics. 2002; 22: 1023-36.
5. Schwartz L., Brody S, Brown K., Covey A, Tuorto S, Mazumdar M., Riedel E, et al. Prospective, blinded comparison of helical CT and CT arterial portography in the assessment of hepatic metastasis from colorectal carcinoma, World Journal of Surgery. 2006; 30: 1892-99.
6. Takagi H. Diagnosis and management of cavernous hemangioma of the liver, Seminars in Surgical Oncology, 1985; 1: 12-22.
7. American College of Radiology (2002), Expert Panel on Gastrointestinal Imaging. Liver lesion characterization, Reston, Va.: American College of Radiology. Simonovsky V. The diagnosis of cirrhosis by high resolution ultrasound of the liver surface, The British Journal of Radiology. 1999; 72:29-34.
8. Lomas D.J. The liver. In: Grainger RG, Allison DJ, eds. Grainger and Allison's Diagnostic Radiology: A Textbook of Medical Imaging. 4th ed. London. Churchill Livingstone. 2001, 1247-48P
9. Ito K., Mitchell DG, Hann HW, Kim Y, Fujita T, Okazaki H, et al. Viral induced cirrhosis: grading of severity using MR imaging, American Journal of Roentgenology. 1999; 173: 591-96.
10. Gandh SN, Brown MA, Won JG, Aguirre DA, Sirlin CB. MR contrast agents for liver imaging: what, when, how. Radiographics. 2006; 26: 1621-36.

11. Hori M, Murakami T, Kim T, Takahashi S, Oi H, Tomoda, K., Narumi, Y. et al. Sensitivity of double-phase helical CT during arterial portography for detection of hypervascular hepatocellular carcinoma, *Journal of Computer Assisted Tomography*. 1998; 22: 861-67.
12. Balci NC, Befeler AS, Leiva P, Pilgram TK, Havlioglu N. Imaging of liver disease: comparison between quadruple-phase multidetector computed tomography and magnetic resonance imaging. *Journal of Gastroenterology Hepatology*, 2008; 23: 1520-27.
13. Zaky IM, Bassiouni MI and Kamal TA. Triphasic Spiral CT in Hepatocellular Carcinoma Timing Optimization for Increasing Detectability, *Journal of the Egyptian Nat. Cancer Inst*, 2001; 13:49-56.
14. Hafeez S, Alam MS, Sajjad Z, Khan ZA., Akhter W and Mubarak F, Triphasic computed tomography (CT) scan in focal tumoral liver lesions, *Journal of the Pakistan Medical Association*, 2011; 61:571-75.
15. Laghi A, Iannaccone R, Rossi P, Carbone I, Ferrari R and Mangiapane F et al. Hepatocellular Carcinoma: Detection with Triple-Phase Multi-Detector Row Helical CT in Patients with Chronic Hepatitis, *Radiology*. 2003; 226:543-49.
16. Li CS., Chen RC, Tu HY, Shih LS., Zhang TA, Lii JM et al. Imaging well-differentiated hepatocellular carcinoma with dynamic triple-phase helical computed tomography, *The British Journal of Radiology*, 2006; 79:659-65.
17. Yaqoob J, Bari V, Usman MU, Munir K, Mosharaf F & Akhtar W. The evaluation of Hepatocellular Carcinoma with Biphasic Contrast enhanced Helical CT scan *JOMA*. 2004; 54:123-24.
18. Caturelli E, Biasini E, Bartolucci F, Facciorusso D, Decembrino F, Attino V et al. Diagnosis of hepatocellular carcinoma complicating liver cirrhosis: utility of repeat ultrasound-guided biopsy after unsuccessful first sampling *Cardiovasc Intervent Radiol*. 2002; 25: 295- 99.
19. Rapaccini GL, Pompili M, Caturelli E, Anti M, Aliotta A, Cedrone A, Amadei E et al. Focal ultrasound lesions in liver cirrhosis diagnosed as regenerating nodules by fine-needle biopsy. Follow-up of 12 cases. *Dig Dis Sci*. 1990; 35:422-27.

---

\*Correspondence: Reza Toufiq Md Hasinuzzaman, Radiologist, Department of Radiology and Imaging, Rangpur Medical College Hospital, Rangpur, Bangladesh, e-mail: tuhin6747@gmail.com