

## RESEARCH PAPER

## Ultrasonographic Assessment of Dengue Fever and its Correlation with Platelet Count

Kamrun Nahar<sup>1</sup>, Mahmood-uz-jahan<sup>2</sup>, Shamima Akhter<sup>3</sup>, Saikat Barua<sup>1</sup>, Dilara Begum<sup>4</sup>, Mohammed Kamrul Hasan<sup>5</sup>

<sup>1</sup>Department of Radiology & Imaging, Bangladesh Medical College, Dhaka, Bangladesh; <sup>2</sup>Bangladesh Medical Research Council, Dhaka, Bangladesh; <sup>3</sup>Department of Radiology & Imaging, Suhrawardy Medical College, Dhaka, Bangladesh; <sup>4</sup>Department of Radiology & Imaging, National Institute of ENT, Dhaka, Bangladesh; <sup>5</sup>Directorate General of Health Services, Dhaka, Bangladesh

### Abstract

**Background:** Dengue virus infections are a significant threat to human populations particularly in the tropical and subtropical regions. This is mainly transmitted by *Aedes aegypti* mosquito from humans to humans. The main pathological mechanisms associated include thrombocytopenia, haemorrhagic diathesis with haemoconcentration. Ultrasonography is used because of its ability to detect plasma leakage signs and prediction of disease severity.

**Objective:** To evaluate the usefulness of ultrasonographic findings of dengue fever and its correlation with platelet count.

**Methods:** It was a prospective observational study, carried out in Bangladesh Medical College Hospital, Dhaka from May 2019 to August 2019. A total of 213 patients of suspected dengue fever during the epidemic were included in this study. All the cases were serologically diagnosed and evaluated with ultrasonographic findings. Platelet counts were estimated in all the cases and compared with findings recorded on ultrasonographic findings.

**Results:** The mean age of the study population was 28.7 years. The male female ratio was 1.7:1. The common features on ultrasonography were thickened and oedematous gall bladder wall, mild to moderate ascites, pleural effusion (unilateral and bilateral), and hepatosplenomegaly. Thickened and oedematous gall bladder wall were observed in 68.8%, mild to moderate ascites 65.3%, bilateral pleural effusion 58.2 %, unilateral pleural effusion 40.4%, hepatomegaly 34.3 % and splenomegaly 13.6 % Platelet counts were significantly lower in abnormal ultrasonographic findings ( $p=0.001$ ).

**Conclusion:** In a febrile patient with thrombocytopenia and positive dengue serology, ultrasonography of the abdomen is a useful tool to evaluate the severity of illness. Ultrasound findings of gall bladder wall oedema, ascites, and pleural effusion were correlated with the severity of thrombocytopenia. In epidemic scenarios, Ultrasonographic features may help in roughly estimating the platelet count even before serology and platelet results are available. Thus, it helps in treatment planning without waiting for the laboratory results.

**Keywords:** Dengue, Hepatosplenomegally, Ascites, Pleural effusion

### Introduction

Dengue is a mosquito-borne infection that has become a major national public health problem in Bangladesh.<sup>1</sup> It is transmitted by the female *Aedes aegypti* mosquito.<sup>2</sup> The dengue virus belongs to the genus *Flavivirus* family, which also includes other arthropod-borne viruses such as yellow fever, DENV-1, DENV-2, DENV-3, and DENV-4.<sup>3</sup> Among the different types of

DENV serotypes, DENV 2 and 3 are the most predominant ones.<sup>4</sup> (1) In the tropical regions such as the Pacific region islands and South-East Asia, dengue fever was first identified over a century ago.<sup>5</sup> It is recognized as an endemic disease in more than 100 countries of the world and threatens the health of 40% of the world's population<sup>6</sup>. It is more common during the rainy season due to the breeding of mosquitoes facilitated by water stagnation.<sup>6</sup> Dengue incidents increased rapidly over the last five years, due to the lack of appropriate hygienic lifestyle, increasing population, and suburbanization of the population.<sup>7</sup> Dengue is also known for its ability to spread rapidly to its nearby areas, and this is a major

\*Correspondence: Dr. Kamrun Nahar, Department of Radiology & Imaging, Bangladesh Medical College, Dhaka, Bangladesh; e-mail address: [knmili01@gmail.com](mailto:knmili01@gmail.com); ORCID: 0000-0002-5151-9115

concern globally, leading to the economic crisis in many affected countries including ours.<sup>4</sup> Dengue fever can present with various symptoms like fever, body ache, joint pain, rash, headache, and retro-orbital pain and may result in deadly complications like dengue hemorrhagic fever, dengue shock syndrome. For prompt management of dengue and to avoid the complications quick and available effective diagnostic tools are necessary.<sup>8</sup> The disease mainly occurs in two forms, the classic dengue which is a milder form of the illness, and the severe dengue haemorrhagic fever (DHF). Thrombocytopenia and haemo-concentration are seen in both forms of the disease. Thrombocytopenia is transient and asymptomatic but in a significant number of cases, there are bleeding manifestations. Spontaneous bleeding is noted in platelet count of <20000 in the majority of patients. Petechiae/purpura is seen in platelet count in the range of 20,000-40,000. This signifies the need to evaluate platelet count and the prevalence of dengue.<sup>9</sup> The severity of the disease is directly related to thrombocyte count and the findings are severe with falling platelet counts.<sup>1</sup> The diagnosis of dengue fever is based on clinical suspicion in endemic areas along with positive serology. Anti-dengue antibody appears only after 7 days of the onset of disease, thus delaying the diagnosis.<sup>10</sup> Ultrasonography is an economical, rapid, and widely available non-invasive imaging modality in the diagnosis of dengue fever. Several studies have proven that ultrasonography of the chest and abdomen can be an important adjunct to clinical profile in the early diagnosis of dengue fever.<sup>11</sup> Milder form of the disease shows mild hepatosplenomegaly and mild gall bladder wall thickening. A severe form of the disease is characterized by significant gallbladder wall edema, moderate ascites, moderate pleural effusion, and hepatosplenomegaly.<sup>12,13</sup> If left untreated, dengue virus can cause an increased mortality rate, as observed in a study where the mortality rate was 20% in the untreated cases and only 1% in the treated cases.<sup>7</sup> Early diagnosis and suitable supportive treatment can be the best method to decrease the mortality rates.<sup>14</sup> In early diagnosis, USG is a valuable method. Sonography is a transportable imaging technique that can detect plasma leakage and capillary permeability.<sup>4</sup> It is useful in recognizing the form of the disease, the stage of the disease, and the overall improvement of a patient. Using a USG machine, the diagnosis of dengue can be made within 3 days of initial signs and symptoms, which could be lifesaving.<sup>15</sup> The present study was conducted to evaluate the usefulness of ultrasonographic findings of dengue fever and its correlation with platelet count.

## Materials and Methods

This was a prospective observational study, carried out in a tertiary hospital (Bangladesh Medical College Hospital) in Dhaka, from May 2019 to August 2019. A total of 700 patients were selected and referred for the sonography at the initial selection. Patients diagnosed with dengue fever, irrespective of age were included in the study.

Patients with previously diagnosed comorbid conditions (excluding dengue) were excluded from the study. Finally, 213 were recruited for the study using the purposive sampling method. Prior to collecting data, written consent was taken from the participants, and also approval was taken from the ethical committee of Bangladesh Medical College Hospital. Standard sonographic techniques and age-based criteria were used for the assessment of organomegaly and fluid collections. A wall thickness of >5mm was considered as thickened irrespective of the prandial status. Dengue serology and sonographic findings were correlated with platelet counts. Data were analyzed using a statistical package for social science (SPSS) for windows version 20. Descriptive statistics and Chi-square tests were performed to find out the result.

## Results

This study shows the average age was 28.7 years. Out of 213 cases, 63.8% were male and female 36.2% were female. The male-female ratio was 1.7:1 (table I) In hepatomegaly cases, the *p*-value was 0.001 and in other normal USG findings, it was 0.297. In total, 144 patients were from the mild dengue category, while 46 were from severe dengue cases. a *p*-value of <0.1 was considered significant, which was the case for all the diagnoses except splenomegaly.

**Table I:** Demographic characters of the study subjects

Characteristics	Frequency	Percentage
Age in years		
≤20	62	29.1
21-30	65	30.5
31-40	47	22.1
41-50	16	7.5
51-60	23	10.8
Mean±SD	28.66±14.99	
Range	2-60	
Sex		
Male	136	63.8
Female	77	36.2
Male female ratio	1.7:1	

All of the participants had fever as a common symptom. Vomiting was present in 23.9%, 21.6% had abdominal discomfort, 13.1% had diarrhea, headache was present in 11.3% and 10.8% had joint pain and body ache (table II).

**Table II:** Clinical features of the study subjects

	Frequency	Percentage
Fever	213	100.0
Headache	24	11.3
Bodyache, joint pain, retro orbital pain	23	10.8
Nausea/vomiting	51	23.9
Abdominal discomfort	46	21.6
Diarrhoea	28	13.1

90.6% of the participants had tested positive for NS1 Antigen, and cross-examining with IgM and IgG tests, 54.9% and 45.5% tested positive respectively (table III).

**Table-III:** Distribution of NS1, IgG and IgM

	Frequency	Percentage
NS1Ag positive	193	90.6
IgG positive	97	45.5
IgM positive	117	54.9

The common features on ultrasonography were thickened & edematous gall bladder wall, mild to moderate ascites, pleural effusion (unilateral and bilateral) and hepatosplenomegaly (table IV).

**Table-IV:** Ultrasonographic findings

Ultrasonographic findings	Frequency	Percentage
Gall bladder wall oedema	145	68.8
Ascites	139	65.3
Bilateral pleural effusion	104	58.2
Unilateral pleural effusion	86	40.4
Hepatomegaly	73	34.3
Splenomegaly	29	13.6
Normal findings	23	10.8

Platelet counts were significantly lower in abnormal ultrasonographic findings ( $p=0.001$ ). Patients with edematous gall bladder had median platelet below 70000. The median platelet was below 80000 in ascites and bilateral pleural effusion cases, and hepatomegaly patients had median platelet less than 100000 (table V).

**Table-V:** Correlation of median platelet count and sonographic findings

Median platelet	Sonographic findings
<70000	Gall bladder wall edema
<80000	Ascites & bilateral pleural effusion
<100000	Hepatomegaly

Comparison of the USG findings between male and female participants showed us that for USG finding of gall bladder wall edema, the p-value was 0.666. for ascites, it was 0.501, for bilateral and unilateral pleural effusion, it was 0.496 and 0.679 respectively (table VI).

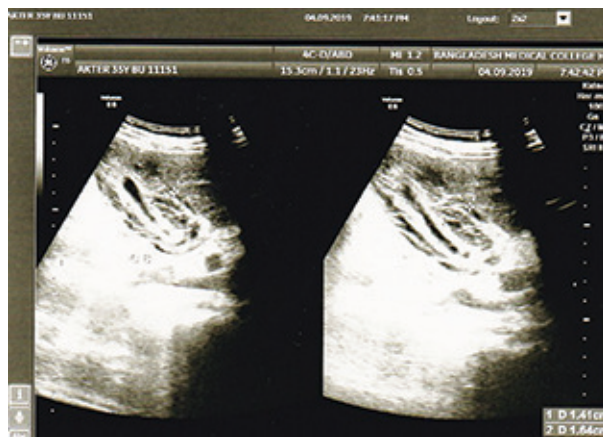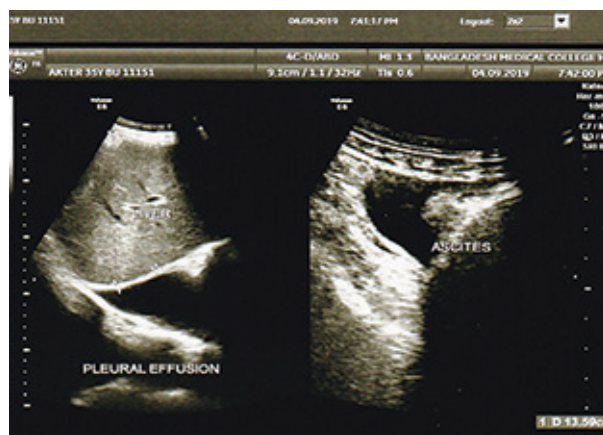
**Table-VI:** Comparison between clinical features according to sex

Ultrasonographic findings	Male(n=136)	Female(n77)	Chi-square	P value
Gall bladder wall edema	94	51	0.188	0.666
Ascites	91	48	0.454	0.501
Bilateral pleural effusion	75	49	0.617	0.496
Unilateral pleural effusion	53	33	0.437	0.679
Hepatomegaly	21	52	4.667	0.001
Normal findings	14	9	1.087	0.297

**Table-VII:** Distribution of USG findings according to severity (n=190)

Ultrasonographic findings	Mild (n=144)	Sever (n=46)	Chi-square	P value
Gall bladder wall edema	138	42	3.827	0.017
Ascites	102	43	4.891	0.007
Bilateral pleural effusion	60	44	19.627	0.001
Unilateral pleural effusion	49	37	2.967	0.003
Hepatomegaly	31	42	19.257	0.001
Splenomegaly	21	8	0.467	0.746

According to the USG findings, thickened & edematous gall bladder wall was observed in 68.8% (n = 145), ascites in 65.3% (n = 139), bilateral pleural effusion in 58.2 % (n = 104), unilateral pleural effusion in 40.4% (n = 86), hepatomegaly in 34.3 % (n = 73) and splenomegaly in 13.6 % (n = 29) (table VII)

**Figure 1:** Transabdominal ultrasonogram image demonstrating GB wall oedema**Figure 2:** USG Showing moderate pleural effusion (Rt) & ascites

## Discussion

Proper diagnosis and treatment of dengue can decrease the mortality rate of dengue by a lot. There are few methods to diagnose dengue in a patient, and among them, ultrasonography is widely used globally. It can detect dengue in less than 3 days after patients start showing symptoms, and makes it easier to observe the current situation and improvement of each patient.

In this study, we found that 30.5% of the patients were 21-30 years of age, followed by 29.1% who were of  $\leq 20$  years, 22.1% were from the age group of 31-40 years, 10.8% were from the age group of 51-60 years and 7.5% were between the age of 41-50 years. The average age was 28.6 years. Majorities were male (63.8%) and the rest (36.2%) were female. The male-female ratio was 1.7:1. A higher prevalence of dengue-infected patients was from the middle-aged population. Therefore, the findings of the study are well in agreement with the findings of the other research works.<sup>1</sup> However some of the studies reported a higher incidence of dengue fever during the 4<sup>th</sup> and 5<sup>th</sup> decade of life.<sup>16</sup> This difference can be attributed to the difference in lifestyle and habits between the localities of multiple studies. This study shows clinical dengue manifestations with sudden onset of high fever with a headache, body ache, joint pain, retro-orbital pain, nausea /vomiting, abdominal discomfort, and diarrhea. Previous studies reported that clinically, dengue manifests with a sudden onset of high fever with chills, muscle and joint pain, intense headache, retro-orbital pain, and backache. Fever usually lasts for about 5 days, but in rare cases, it can last for more than 7 days.<sup>17</sup> In the present study, serologically, 193 patients (90.6%) were positive for NS1 antigen and 97 patients (45.5%) were IgG positive. There is evidence that the

sensitivity of NS1 antigen detection is higher in a primary infection (> 90%). The presence of dengue nonstructural protein1 (NS1) antigen is consistent with acute phase infection with dengue virus. It may be negative if the specimen is collected immediately followed by dengue virus infection (< 24 to 48 hours) and rarely detectable following 9 to 10 days of infection.<sup>17</sup> Raman et al found in their study that serologically, 60 patients (20%) were positive for only NS1 antigen; 60 patients (20%) were IgG & IgM positive. Manam et al. reported serological tests are still the mainstay in the diagnosis of dengue fever and to differentiate from other causes of febrile illness like typhoid, malaria, and spotted fevers.<sup>18</sup> However, the availability of rapid diagnostic tests by determining the presence of NS1 antigen can help in the early diagnosis of dengue fever. Diagnostic modalities like ultrasonogram of the abdomen and chest can be sought for early diagnosis before the development of complications. The early findings which have been quoted in various pieces of literature include a combination of findings like the thickness of the gall bladder wall, pleural, pericardial effusion, and ascites. However, the degree of accuracy is quite variable in different studies. Hence this study was to evaluate the ultrasonographic findings during an epidemic and its correlation with platelet counts. Among the ultrasonographic findings reported, gall bladder wall edema was the commonest finding in this study with 68.8% followed nearby with ascites 65.3%, bilateral pleural effusion (58.2%), unilateral pleural effusion (40.4%). Hepatomegaly was seen in 34.3% and splenomegaly (13.6%). However, this finding was inconsistent with the findings of Setiawan who reported ascites as the most common ultrasonographic finding (76%) in cases of dengue fever followed by pleural effusion (68%) in their study.<sup>19</sup> Another study by Manam found that among the ultrasonographic findings reported, the thickness of the gall bladder wall was the commonest finding in their study with 65.08% followed nearby with Ascites with 62.70% and pleural effusion (49.21%).<sup>20</sup> In a similar study conducted by Venkata Sai et al GB wall thickening was the most common finding (100%), followed by pleural effusion (93.1%) and ascites (53.2%).<sup>5</sup> In a study conducted by Santhosh et al. out of 96 seropositive dengue cases, 66.7% of patients showed edematous GB wall thickening, 64.5% patients showed ascites, and 50% patients had pleural effusion.<sup>21</sup> In the study by Vedaraju, GB wall thickening was the most common finding (83.3%), followed by pleural effusion (59.8%), and ascites (53.9%).<sup>22</sup>

Rehman in their study had shown that GB wall edema was the most consistent finding (63%) on abdominal sonography in patients with dengue fever.<sup>8</sup> The thickened gall bladder wall was the most common feature in dengue patients in the studies conducted by Keng-Liang Wu.<sup>2</sup> In this study we found gall bladder edema median platelet count of 35000 with the lowest count of 10000 and the highest 70000/cumm. Cases with ascites & bilateral pleural effusion had a median platelet count of 46000 with the lowest count of 10000 and highest 80000/cumm. Cases with hepatomegaly had a median platelet count of 54000 with the lowest count of 50000 and the highest 10000/cumm. The study by Raman found moderate ascites had a median platelet count of 30000 with the lowest count of 27000 and the highest 60000/cumm.<sup>10</sup> Cases with bilateral pleural effusion had a median platelet count of 27000 with the lowest count of 18000 and highest 60000/cumm. Cases with unilateral pleural effusion had a median platelet count of 50000 with the lowest count of 33000 and highest 60000/cumm. Cases with GB wall edema, pleural effusion, and ascites had the lowest platelet count of 18000 and highest 60000 with a median platelet count of 27000/cumm. Cases with splenomegaly had no significant correlation with platelet counts.

## Conclusion

Common features on ultrasonography were thickened and oedematous gall bladder oedema, mild to moderate ascites, bilateral mild pleural effusion. Platelet counts were significantly lower in abnormal ultrasonographic findings. Limitation of this study was that it was conducted in a tertiary care hospital, the majority of the cases were referred cases after diagnosis and the follow-up findings of USG were not done to evaluate the time of resolution of findings. However, in an epidemic scenario, the findings of this study may help in roughly estimating the platelet count even before serology and platelet results are available. Thus, it helps in treatment planning without waiting for the laboratory results. This may save a lot of crucial time for handling the epidemic efficiently.

*Ethical Clearance:* Ethical Committee of Bangladesh Medical College Hospital, Dhaka.

*Conflict of interest:* There is no conflict of interest.

*Funding:* BMRC

*Submitted:* 16 October, 2019

*Final revision received:* 18 March, 2020

*Accepted:* 19 March, 2020

*Published:* 1 April, 2021

## References

- Bhargava S, Srivastava S, Gupta A. Ultrasonographic findings in dengue fever: a retrospective study. *J Int Med Sci Acad.* 2017;30:75-8.
- Wu KL, Changchien CS, Kuo CH, Chiu KW, Lu SN, Kuo CM, Chiu YC, Chou YP, Chuah SK. Early abdominal sonographic findings in patients with dengue fever. *Journal of clinical ultrasound.* 2004 ;32:386-8.
- Sharma S, Sharma SK, Mohan A, Wadhwa J, Dar L, Thulkar S, Pande JN. Clinical Profile of Dengue Haemorrhagic Fever in Adults during 1996-Outbreak in Delhi, India.
- Basawaraj NG, Dasan TA, Patil SS, Deepashri B. Role of sonography in the assessment of dengue fever with serological correlation. *Int J Res Med Sci.* 2015 ;3:3131-6.
- Santhosh VR, Patil PG, Srinath MG, Kumar A, Jain A, Archana M. Sonography in the diagnosis and assessment of dengue fever. *Journal of Clinical Imaging Science.* 2014;4.
- Venkata Sai PM, Dev B, Krishnan R. Role of ultrasound in dengue fever. *The British Journal of Radiology.* 2005;78: 416-8.
- Nimmagadda SS, Mahabala C, Bloor A, Raghuram PM, Nayak A. Atypical manifestations of dengue fever (DF)– where do we stand today?. *Journal of Clinical and Diagnostic Research: JCDR.* 2014 ;8:71.
- Krishna AR, Myreddy N, Uppara S. Assessment of Platelet Levels in Serum Samples of Dengue Patients Before and After Providing Papaya with Other Fruits. *Annals of International Medical and Dental Research.*;3:1.
- Pruthvi D, Shashikala P, Shenoy V. Evaluation of platelet count in dengue fever along with seasonal variation of dengue infection. *J Blood Disorders Transf.* 2012;3:1-4.
- Rahman M, Rahman K, Siddique AK, Shoma S, Kamal AH, Ali KS, Nisaluk A, Breiman RF. First outbreak of dengue hemorrhagic fever, Bangladesh. *Emerging infectious diseases.* 2002;8:738.
- Lutz HT, Gharbi HA, editors. *Manual of diagnostic ultrasound in infectious tropical diseases.* Springer Science & Business Media; December 2005.
- Wu KL, Changchien CS, Kuo CH, Chiu KW, Lu SN, Kuo CM, Chiu YC, Chou YP, Chuah SK. Early abdominal sonographic findings in patients with dengue fever. *Journal of clinical ultrasound.* 2004 ;32:386-8.
- Yousaf KR, Atiq SA, Sheikh QS, Nisar MS, Mansoor Z, Khalid S. Sonographic features of polyserositis as an adjunct to clinicopathological parameters in diagnosing and predicting the severity of dengue fever. *Pak J Med Health Sci.* 2011;5:184-9.
- Reddy K. Hepatic profile and platelet count as a prognostic indicator in Dengue fever, from a tertiary care hospital in south India.
- Chatterjee R, Mysore A, Ahya K, Shrikhande D, Shedabale D. Utility of sonography in clinically suspected Dengue. *Pediatric Infectious Disease.* 2012 ;4:107-11.
- Potts JA, Rothman AL. Clinical and laboratory features that distinguish dengue from other febrile illnesses in endemic populations. *Trop Med Int Health* 2008;13:1328-40.
- Gupta N, Srivastava S, Jain A, Chaturvedi UC. Dengue in India. *The Indian journal of medical research.* 2012 ;136:373.
- Manam G, Godavarthi RM, Baru R, Sunitha DG, Duddu GS. Evaluation of ultrasonographic findings in dengue fever cases during an outbreak at a tertiary care hospital of South India. *IJCMSR.* 2018;3:106-10.
- Setiawan MW, Samsi TK, Pool TN, Sugianto D, Wulur H. Gallbladder wall thickening in dengue hemorrhagic fever: an ultrasonographic study. *Journal of Clinical Ultrasound.* 1995;23:357-62.
- Venkata Sai PM, Dev B, Krishnan R. Role of ultrasound in dengue fever. *The British Journal of Radiology.* 2005;78: 416-8.
- Vedaraju KS, Kumar KR, Vijayaraghavachari TV. Role of ultrasound in the assessment of dengue fever. *International Journal of Scientific Study.* 2016;3:59-62.
- Bhatt S, Gething PW, Brady OJ, Messina JP, Farlow AW, Moyes CL, Drake JM, Brownstein JS, Hoen AG, Sankoh O, Myers MF. The global distribution and burden of dengue. *Nature.* 2011;496:504-7.