

## CASE REPORT

# A Rare Case of Rapidly Progressive Dementia- Creutzfeldt Jakob Disease: Case Report

Maftahul Jannat\*, Md. Shahidullah, Subash Kanti Dey,  
SK Mahub Alam, Abdullah Al Muzahid

Department of Neurology, Bangabandhu Sheikh Mujib Medical University (BSMMU)  
Dhaka, Bangladesh

## Abstract

**Background:** Creutzfeldt Jakob disease is a rare and usually fatal neurodegenerative disorder characterized by rapidly progressive dementia with other neuropsychiatric manifestations like pyramidal, extrapyramidal, cerebellar, visual and behavioral abnormalities. Here we report a case of clinically probable Creutzfeldt Jakob disease in a 55 years old service holder lady presented with rapidly progressive dementia.

**Objective:** The aim was to report a rare case of rapidly progressive dementia caused by Creutzfeldt Jakob disease.

**Methods:** The case was thoroughly evaluated clinically then probable diagnosis was made by characteristic generalized periodic discharges on EEG and cortical and basal ganglia hyperintensity on FLAIR and DWI sequences of MRI of brain in addition to the clinical features of rapidly progressive dementia, rigidity, myoclonus, akinetic mutism and behavioral abnormalities. Other causes of dementia were excluded.

**Result:** Finally probable diagnosis of Creutzfeldt Jakob disease was done according to CDC diagnostic criteria. The case could not be confirmed due to lack of available newer investigations in our country and refusal of autopsy by the patient's guardian.

**Conclusion:** Though rare, a suspicion of Creutzfeldt Jakob disease should be considered in patients with rapidly progressive dementia with complex neurological manifestations. Variable clinical presentation and rarity of the disease always delay the diagnosis. The disease is always fatal and no accepted treatment is available till date. So if early and accurate diagnosis is possible then the prognosis and plan of management could be explained to the caregiver properly.

**Keywords:** Creutzfeldt Jakob disease, generalized periodic discharges, rapidly progressive dementia.

## Introduction

Creutzfeldt-Jakob disease (CJD) is a rapidly progressive, invariably fatal human neurodegenerative disorder clinically characterized by rapidly progressive dementia, myoclonus, cerebellar, pyramidal, extrapyramidal, visual symptoms and various psychiatric manifestations. About 85% of cases of CJD are sporadic, 10%-15% are inherited, <1% are iatrogenic, and <1% are variant.<sup>1,2</sup> Sporadic Creutzfeldt-Jakob disease is the most common of the prion diseases affecting the human.<sup>3</sup> Prion diseases, a group of uniformly fatal neurodegenerative diseases, caused by conformational change of PrP<sup>c</sup> to abnormal PrP<sup>Sc</sup>

which cumulates in various regions of the brain resulting in spongiform degeneration and subsequent gliosis.<sup>4</sup> Normal cellular prion protein (PrP<sup>c</sup>) is found on cell membranes of the mammalian body. Disease-causing form of prion (PrP<sup>Sc</sup>) multiplies by binding to the normal cellular isoform PrP<sup>c</sup> and converts it into an abnormal, structurally altered disease-causing PrP<sup>Sc</sup>, which accumulates into the brain leading to spongiform neurodegeneration.<sup>1</sup> CJD occurs worldwide, but as systematic surveillance has only been undertaken in a minority of countries, the incidence in much of the world is currently unknown including Bangladesh. The early diagnosis of CJD may be obscured by its variable presentation and rarity. As far our knowledge goes in Bangladesh there was no previous report of cases of CJD till date. We herein present a case of a 55-year-old female who was admitted to Neurology department of Bangabandhu Sheikh Mujib Medical University with 2 months history of progressive dementia with mutism

\*Correspondence: Maftahul Jannat, Department of Neurology, Bangabandhu Sheikh Mujib Medical University (BSMMU), Dhaka, Bangladesh  
Email: dr.mj.swarna.26@gmail.com,  
ORCID : 0000-0002-7470-7936

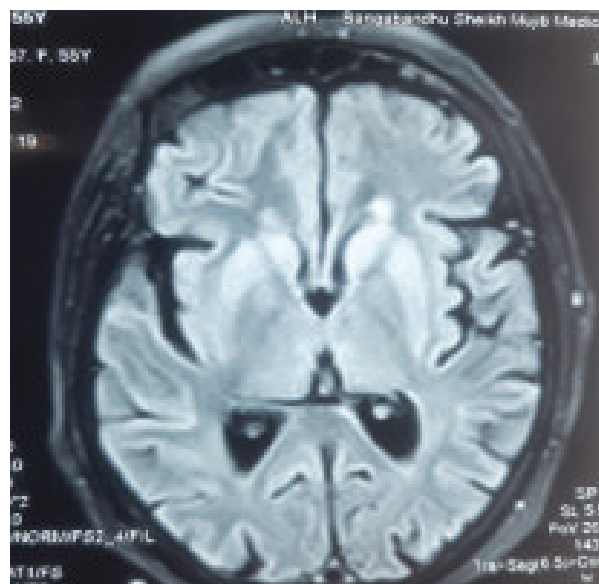
along with characteristic EEG and MRI changes. She was diagnosed as a case of clinically probable sporadic CJD, based on her clinical features of rapidly progressive dementia, characteristic electro-encephalogram (EEG) changes of generalized periodic discharges, and brain magnetic resonance imaging (MRI) imaging sequences according to the CDC criteria.<sup>5</sup>

### The case

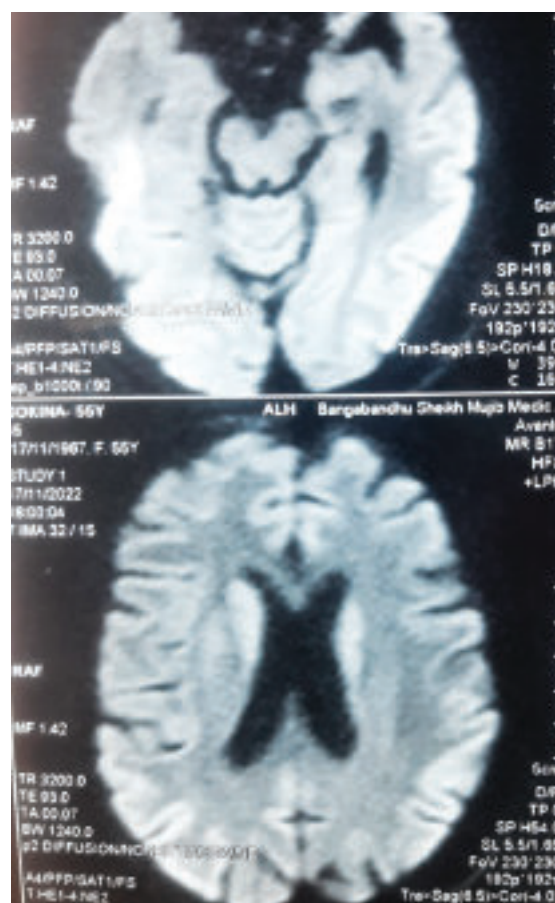
A 55-year-old female service holder was admitted to neurology department of a tertiary care Hospital of Bangladesh with 8 weeks history of rapid deterioration in her memory, mutism, reluctant to feed and subsequently bed bound. She had some psychiatric manifestations like excessive anxiety, talkativeness and some behavioral problems prior to the onset of dementia. Initially she was admitted to Psychiatry department and referred to Neurology department after psychiatric evaluation. She had history of fever with burning micturition at the time of admission to the neurology department. That time patient was diagnosed as urinary tract infection and treated accordingly. Her UTI was improved but cognition was deteriorating to such extent that she was totally unresponsive and mute. She is diabetic and hypertensive and taking anti-hypertensive and antidiabetic medications regularly. She had no prior cardiac problem or respiratory disturbances. She had no history of anoxia and head trauma.

General physical examination was normal except patient was unresponsive, mute and she did not follow any command. Her vital signs were within normal limits. Neurological examination showed significant cognitive impairment with rigidity and akinetic mutism. Motor and sensory functions were not completely evaluated due to lack of cooperation by the patient. Her deep tendon reflexes were normal and plantar response was flexor. She had occasional myoclonus that was observed during the hospital course. After clinical evaluation patient was thoroughly investigated to find out the cause of rapidly progressive dementia. To exclude other causes of dementia, thyroid function test, syphilis testing, vitamin B12 level, and human immunodeficiency virus screening was done and revealed no significant abnormalities. Routine CSF study was normal except mildly raised protein (73mg/dl). CSF for 14-3-3 protein was not done due to lack of availability of the test in our country.

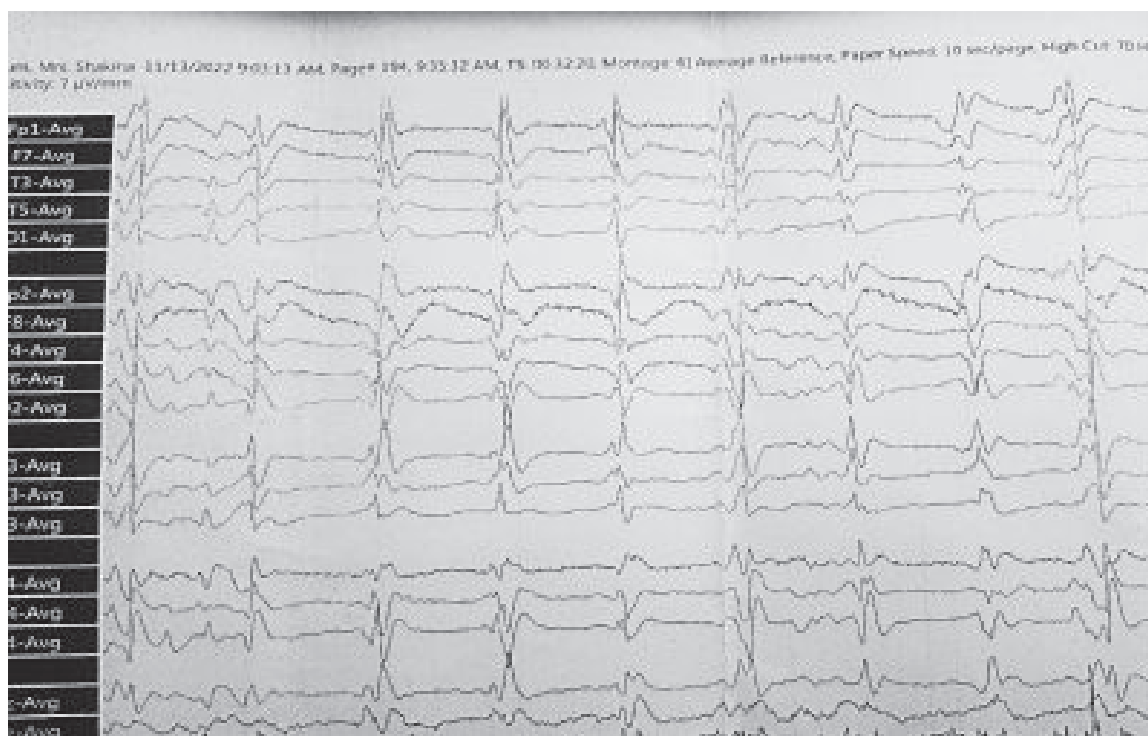
MRI was done twice and showed gyriform area of subtle cortical restricted diffusion involving the temporal and parietal lobe with basal ganglia and corresponding subtle T2 and FLAIR hyperintensity more marked on the left side (figure 1 and 2).



**Figure 1:** MRI of brain with FLAIR sequence showing hyperintensity of both basal ganglia (head of caudate nucleus and putamen).



**Figure 2:** Mild restricted diffusion is observed in both parietal and temporal lobe (left>right) on diffusion weighted imaging of brain MRI



**Figure 3:** Electroencephalogram showed generalized periodic sharp wave discharges occurring every one second interval

These changes were more marked in the 2<sup>nd</sup> MRI which was done 2 weeks after the 1<sup>st</sup> MRI, that indicate disease progression. There was no evidences of ventriculomegaly, tumor and infarct or subdural haematoma on imaging. The electroencephalogram showed repetitive generalized periodic 1 Hz sharp wave discharges recurring every 1-1.5 minutes and almost was symmetrical in distribution.

The classic EEG findings may be absent in the early stage. Considering the clinical course of rapidly progressive dementia with characteristic EEG findings and MRI changes the patient was diagnosed as clinically probable Creutzfeldt Jakob disease according to CDC criteria<sup>5</sup> after exclusion of other causes of dementia. During hospital course the patient had no significant improvement of her memory and other neurological condition. Subsequently patient was discharged by the request of the patient's guardian. She died after a month of discharge as informed by her younger son. Autopsy could not be done due to refusal from patient's guardian.

### Discussion

This patient was diagnosed as clinically probable CJD due to rapidly progressive dementia, akinetic mutism

and cortical myoclonus with classic EEG and MRI brain abnormalities, which is compatible with the diagnosis of CJD. Though the case could not be confirmed due to lack of availability of newer investigations in our country and refusal of consent for autopsy by the patients guardian. Finally the diagnosis was made according to CDC diagnostic criteria.<sup>5</sup> The patient initially presented with some psychiatric manifestations like depression, excess anger and some behavioral abnormalities prior to the onset of neurological manifestations. Which may be one of the reason for delayed diagnosis. Subsequently the patient developed progressive dementia, mutism and myoclonus. The diagnosis of CJD in the early stages is fairly challenging due to the rarity of the disease and highly varied initial symptoms. Sometimes early onset dementia may be masked by concomitant psychiatric symptoms and extrapyramidal signs. Twenty percent of patients may first manifest with behavioral symptoms such as agitation, irritability and depression in the early stages like that of the current case.<sup>6</sup> The myoclonus may be absent in the early presentation but usually appears in the advanced stages of CJD.<sup>7</sup> The current patient also developed myoclonus during the advanced stages of the disease.

Akinetic mutism is usually manifested at the end stage of CJD which was also found in this case.<sup>8</sup> Thus CJD should be considered in the differential diagnosis when rapidly progressive dementia is diagnosed on top of significant behavioral and psychiatric manifestations in addition to complex neurological features including both pyramidal and extrapyramidal system.

MRI of brain plays one of the important role in the diagnosis of CJD. The MRI is done not only to diagnose CJD but also to exclude other differentials. The classic MRI manifestations in CJD are hyper intensity in the basal ganglia and cerebral cortex on T2, and FLAIR sequences with restricted diffusion on DWI.<sup>9,10</sup> The current patient had subtle hyper intense signal changes on T2 and FLAIR sequence in the basal ganglia and parietotemporal lobe. The changes were asymmetrical and more marked in the left side. DWI showed mild restricted diffusion in the above mentioned area. Despite this MRI changes for sporadic CJD is highly sensitive and specific which is 96% and 93% respectively, many diseases show similar basal ganglia abnormalities, including Wilson's disease, cerebral hypoxia, and MELAS, vasculitis, or reversible posterior leukoencephalopathy.<sup>11</sup> But these diseases can be excluded by other relevant investigations and clinical presentation. A highly sensitive and specific test for diagnosing sCJD is 14-3-3 protein which is a marker for neuronal death, detected using Western blotting technology. This protein can be positive even in the early stages of sporadic CJD. Despite its value in the diagnosis of sporadic CJD, many other conditions may also produce 14-3-3 protein in CSF, but they can be easily and effectively excluded. These diseases include viral encephalitis, subarachnoid hemorrhage, hypoxic brain damage, metabolic/ toxic encephalopathy, glioblastoma, paraneoplastic encephalopathy, and corticobasal degeneration.<sup>11,12</sup> CSF 14-3-3 protein was not done in our case because the test is not available in our country. Typical EEG findings in sporadic CJD are repetitive pattern of bilateral synchronous periodic, biphasic, or triphasic sharp-wave complexes of 1-2 Hz. This periodic sharp wave complexes (PSWCs) have a sensitivity and specificity of 64%-66% and 74%-91% respectively.<sup>9</sup> However, these characteristic EEG appear only in the advanced stages of the disease.<sup>9</sup> The characteristic EEG is diagnostic of sporadic CJD in the correct clinical context. Some other causes of dementia, such as Alzheimer's disease, Lewy body

disease, AIDS dementia, multiple brain abscesses, MELAS syndrome, metabolic, and toxic encephalopathy, rarely have similar EEG findings.<sup>11</sup> But these can be easily differentiated by clinical and other relevant investigations. In our case we also found similar characteristic EEG abnormalities that are supportive of CJD. Finally patient was diagnosed as clinically Probable CJD based on clinical features of rapidly deteriorating dementia, akinetic mutism, occasional myoclonus with some psychiatric manifestations in addition to basal ganglia and cortical hyperintensity on MRI and generalized periodic discharges on EEG.

### Conclusion

Though rare, a suspicion of Creutzfeldt Jakob disease should be considered in patients with rapidly progressive dementia with complex neurological manifestations. Variable clinical presentation and rarity of the disease always delay the diagnosis. The disease is always fatal and no accepted treatment is available till date. So if early and accurate diagnosis is possible then the prognosis and plan of management could be explained to the caregiver properly.

*Conflict of interest:* There was no conflict of interest.

*Funding:* Not applicable

*Ethical approval:* Not applicable

*Submitted:* 12 June 2023

Final revision received: 06 November 2023

*Accepted:* 09 October 2023

*Published:* 01 December 2023

### References

1. Prusiner SB. Creutzfeldt-Jakob disease and scrapie prions. *Alzheimer Dis Assoc Disord.* 1989;3: 52-78. DOI: 10.1097/00002093-198903010-00007
2. Iwasaki Y. Creutzfeldt-Jakob disease. *Neuropathology.* 2017; 37:174-88. DOI: 10.1111/neup.12355
3. Brown P, Gibbs CJ Jr, Rodgers-Johnson P, Asher DM, Sulima MP, et al. Human spongiform encephalopathy: The National Institutes of Health series of 300 cases of experimentally transmitted disease. *Ann Neurol.* 1994; 35: 513-29. DOI: 10.1002/ana.410350504



4. Glatzel M, Ott PM, Linder T, Gebbers JO, Gmür A, et al. Human prion diseases: Epidemiology and integrated risk assessment. *Lancet Neurol.* 2003; 2: 757-63. DOI: 10.1016/s1474-4422(03)00588-x
5. Revised WHO Definition of CJD Subtypes (Incorporating the New Definition of Probable Sporadic CJD as Per Section 3.1. Available from: Link: <https://goo.gl/RNYMKO/brain/aws238>
6. Chen C, Dong XP: Epidemiological characteristics of human prion diseases. *Infect Dis Poverty.* 2016, 5:47. DOI: 10.1186/s40249-016-0143-8
7. Collins SJ, Sanchez-Juan P, Masters CL, et al.: Determinants of diagnostic investigation sensitivities across the clinical spectrum of sporadic Creutzfeldt–Jakob disease. *Brain.* 2006, 129:2278-87. DOI: 10.1093/brain/awl159
8. Nakatani E, Kanatani Y, Kaneda H, et al.: Specific clinical signs and symptoms are predictive of clinical course in sporadic Creutzfeldt-Jakob disease. *Eur J Neurol.* 2016, 23:1455-62. DOI: 10.1111/ene.13057
9. Kharel H. The first reported case of Creutzfeldt-Jakob disease from Nepal. *Clin Case Rep.* 2020;8:198-202. DOI: 10.1002/ccr3.2609
10. Fragoso DC, Barros BR, Littig IA, Nunes RH, Carlos A, Maia M. Imaging of Creutzfeldt-Jakob Disease : Imaging Patterns and Their Differential Diagnosis 1. *Radiographics.* 2017;37:234-57. DOI: 10.1148/rg.2017160075
11. World Health Organization. Global Surveillance, Diagnosis and Therapy of Human Transmissible Spongiform Encephalopathies: Report of a WHO Consultation; 1998.
12. Stoeck K, Sanchez-Juan P, Gawinecka J, et al. Cerebrospinal fluid biomarker supported diagnosis of Creutzfeldt-Jakob disease and rapid dementias: A longitudinal multicentre study over 10 years. *Brain.* 2012;135:3051-61. DOI: 10.1093/17.