

### ASKIN'S TUMOR

M Sayeed Hossain<sup>1</sup>, AKM Hamidur Rahman<sup>2</sup>, GM Faruque<sup>3</sup>, M Moarraf Hossen<sup>3</sup>, MA Bari<sup>4</sup>,  
Arunangshu Das<sup>5</sup>

#### Abstract:

Askin's tumor is a malignant small round cell tumor affecting thoracopulmonary region. Because of its neuroectodermal origin it is also known as Primitive neuroectodermal tumor. An 8 year-old female patient was admitted to our hospital with complaints of weight loss and upper abdominal mass. Skyagram of chest P/A view showed a well circumscribed mass in upper zone of the left lung. Diagnosis was made by fine needle aspiration cytology which showed malignant small round cell tumor. Clinical, radiological and cytological findings led to the definite diagnosis of Askin tumor.

Treatment in Askin tumor consists of radical surgery, neoadjuvant or adjuvant chemo-therapy and radiotherapy. Although a long survival is intended by multimodel therapy, prognosis is generally poor. Recently remission rate has improved from 26 % to 65% with aggressive chemotherapy.

Survival has been reported as 8 months after diagnosis. Since our case was inoperable and patient denied radiotherapy so, chemotherapy was planned.

**Key word:** Askin's Tumor, PNET, Chemotherapy.

(Bang. Onc. J. 2009; 4(2) : 82-85)

#### Introduction:

Primitive neuroectodermal tumors (PNETs) are a group of highly malignant tumors composed of small round cell tumors of neuroectodermal origin that affect soft tissue and bone. Batsakis et al (1996) divided PNET family of tumors into three group according to tissue of origin- CNS PNETs (Tumors derived from Central Nervous System), Neuroblastoma (Tumors derived from Autonomic Nervous System), Peripheral PNETs (Tumors derived from tissues outside the Central and Autonomic Nervous System)<sup>1</sup>.

Peripheral primitive neuroectodermal tumor/ Ewing's sarcoma (PNET/EWS) is the most

frequent chest wall tumor occurring in children and adolescents. The mean age for patients to develop the tumor is between 14 and 20 years, and there is a slight frequency seen in males<sup>2</sup>.

Askin's tumor is a very rare malignant small round cell tumor affecting the thoracopulmonary region<sup>3,4,5</sup>. Askin tumor has been defined by Askin and Rosai in 1979<sup>6</sup>. Histologic feature of Askin's tumor includes small round cells, which are often neuron-specific enolase (NSE)<sup>3,7,8,9</sup>.

#### Case Summary:

Asma, 8 years girl hailing from Board Bazar Gazipur, presented with pain in the upper abdomen and gradual weight loss for 4 months and upper abdominal lump for 2 months. The pain usually occurred at an interval of 4-5 days and persisted for 3-4 days, dull in nature, non radiating and had no aggravating or relieving factors. She also gave history of nausea, constipation and low grade fever. She also complained of anorexia and gradual weight loss for 4 months. For the last two months she noticed a mid upper abdominal lump which was gradually increasing in size. On general examination the patient was cachexic, mildly anaemic, nonicteric, pulse rate 80 per minute and temp 100°F. The Lymph Nodes of left anterior-posterior and right anterior cervical chains are enlarged (largest one is about 2x3 cm<sup>2</sup>), non-tender, discrete, firm in consistency, mobile and not fixed with the underlying structures, overlying skin is free.

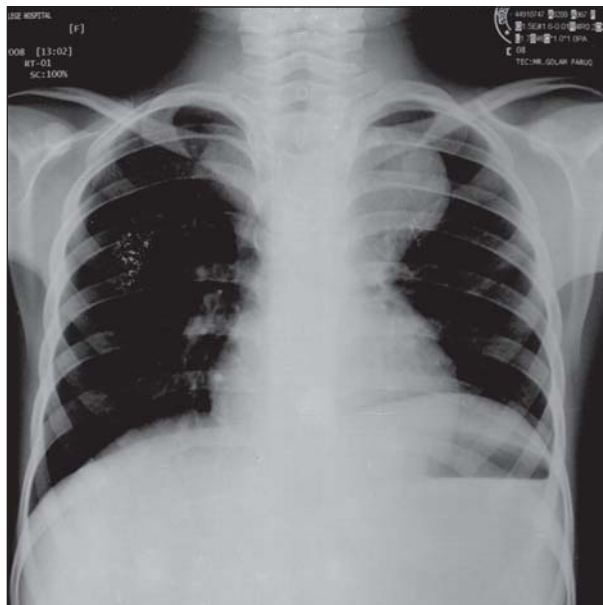
On examination of Gastrointestinal Tract (GIT) there was an epigastric lump measuring about 4x4cm<sup>2</sup> smooth surface, firm in consistency, non tender and fixed. Examination of other system revealed no abnormality.

Following Investigations were done- Complete Blood Count (on 13.2.2008) revealed Hb- 55%, ESR - 70 mm in 1<sup>st</sup> hour, other wise normal. Renal function tests on 13.02.2008: S. Creatinine - 0.72 mg/dl, Blood Urea - 13 mg/dl, MT test - 6 mm. Sputum for AFB -Negative. Liver Function Tests 13.02.2008: S. Bilirubin -

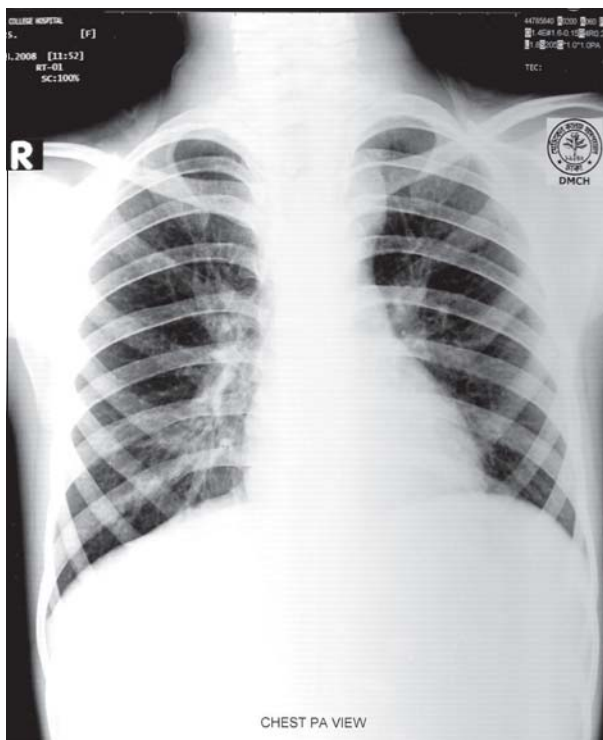
1. Registrar, Department of Radiotherapy, Dhaka Medical College Hospital.
2. Associate Professor, Department of Radiotherapy, Faridpur Medical College.
3. Associate Professor, Department of Radiation & Oncology, DMC.
4. Assistant Professor, Department of Oncology, BSMMU.
5. Honorary Medical Officer, Department of Radiotherapy, Dhaka Medical College Hospital.

**Address of Correspondence:** Dr. M Sayeed Hossain, Registrar, Department of Radiotherapy, Dhaka Medical College Hospital.

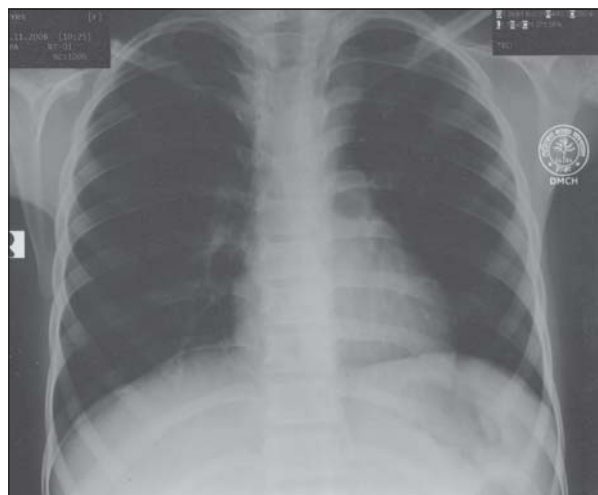
0.80 mg/dl, ALT-72 U/L, Alkaline Phosphatase 232 U/L. Biological Markers 15.02.2008:  $\beta$ -HCG- 2 mIU/ml,  $\alpha$ -Fetoprotein- 5 ng/ml, LDH- 100 IU/L, Urinary VMA - 330 ng/ 24 hours. USG of whole abdomen on 27.01.2008: Multiple solid hypo echoic masses in the upper abdomen (Lymph node ). E.C.G 13.02.2008 - Normal.



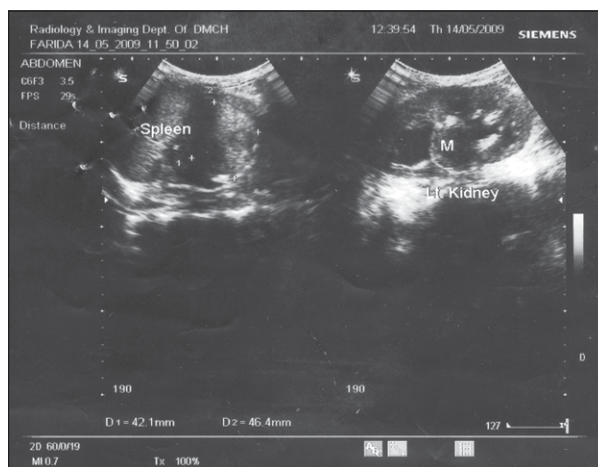
*Before Chemotherapy*



*After 3 cycle chemotherapy*



*After 6 cycle chemotherapy*



*Ultrasonography showing pelvic mass*

Biopsy from left cervical lymph node on 21.01.2008: Chronic non-specific lymphadenitis. FNAC from abdominal mass on 3.02.2008: Negative for malignant cell. X-ray chest P/A view (26.1.2008) shows a well circumscribed mass in upper zone of the left Lung. Final Diagnosis: Primitive Neuro-Ectodermal Tumor (PNET) (Askin's Tumor).

Treatment Plan: Neo-adjuvant Chemotherapy (up to 12 wks)  $\pm$  Surgery / Radiotherapy + Adjuvant Chemotherapy (up to 49 wks, Total 17 course).

Chemotherapy Schedule: *Course I:* Vincristin 2 mg/m<sup>2</sup> IV D-1, Doxorubicin 75mg/m<sup>2</sup> IV D-1, Cyclophosphamide 1200 mg/m<sup>2</sup> IV D-1, Actinomycin 1.25 mg/m<sup>2</sup> IV D-1.

*Altering with Course II:* Iphosphamide 1800 mg/m<sup>2</sup> IV D-1 to D-5, Etoposide 100 mg/m<sup>2</sup> IV D-1 to D-5. Every 3 weekly. Patients received chemotherapy irregularly due to financial constrain and completed cycle – 7 phase -2 chemotherapy on 29-04-2009. On the next subsequent follow up on 9-5-2009 patient complained of abdominal pain and distension with poor general condition. Follow up ultrasonography of whole abdomen was done on 14-5-2009 report revealed hypoechoic mass in the pelvis with huge intra-abdominal lymphadenopathy subsequently ultrasono guided FNAC done report revealed small round cell tumour, metastatic primary probabilities are PNET, nephroblastoma. Altered schedule chemotherapy given with exclusion of doxorubicin from 6-6-2009 to 8-6-2009 but the patients condition gradually worsen and patient refused further chemotherapy. Now patient general condition and performance status now do not permit any types of antimitotic treatment. The patient died on 27-06-2009.

#### **Discussion:**

Askin's tumor typically involves soft tissues of the thoracic wall and paravertebral structures. It rarely affects the pulmonary parenchyma, and it seems most commonly arise from intercostals nerves<sup>10,11</sup>. Askin's tumors are generally localized in the thoracopulmonary region<sup>12,13,14</sup>.

The differential diagnosis of Askin's tumor includes Ewing's sarcoma, rhabdomyosarcoma, neuroblastoma and lymphoma<sup>15</sup>.

Askin et al. reported that small round cell tumors of childhood and adolescence located in the thoracopulmonary region are more common in females and that the median age for these cases is 14.5 years<sup>16</sup>.

The diagnosis of Askin tumor rests on cytopathological investigations and immunohistochemical tests. Radiological characteristics were a unilateral chest wall mass, pleural fluid and thickness, invasion to the adjacent lung parenchyma, pulmonary nodules and sometimes lymphadenopathy<sup>17</sup>.

As local recurrences and metastases are frequently seen in Askin tumor, it has a poor prognosis and a short survival<sup>18</sup>. The best

prognosis can be provided by surgical treatment with wide resection<sup>19</sup>. Recurrences in the primary tumor site are important in differentiating these tumors from other tumors in children and adolescents<sup>16</sup>.

Another factor determining the prognosis is the age of the patient. Being older than 26 years, having metastatic disease and presence of an extraosseous primary tumor are factors for high risk of short survival<sup>20</sup>.

Treatment in Askin tumor consists of radical surgery, neoadjuvant or adjuvant chemotherapy and radiotherapy. Although a long survival is intended by multimodal therapy, prognosis is generally poor. Recently remission rate has improved from 26 % to 65% with aggressive chemotherapy<sup>21,22</sup>.

Survival has been reported as 8 months after diagnosis<sup>6</sup>. Since our case was inoperable, chemotherapy was planned.

#### **Conclusion:**

Askin's tumor is a rare variety of peripheral PNET. So every case should be noted and reported. Response of chemotherapy is satisfactory and promising. However, the effectiveness of the chemotherapy needs to be validated with large clinical trials.

#### **References:**

1. Batsakis JG, Mackay B, el-Naggar AK, et al. Ewing's sarcoma and primitive neuroectodermal tumor: an innerim report. *Ann Otol Rhinol Laryngol*. Oct 1996; 105(10): 838-43. (MEDLINE).
2. Kempson R, Fletcher C, Evans H, Hendrickson M, Sibley RK. Malignant neoplasms (Managerial Groups III and IV, Table 1-10). In: *Tumors of the soft tissue*. 3rd. Washington D.C.: Armed Forces Institute of Pathology, 2001: 444-52.
3. Christiansen S, Semic M, Dockhorn- Dworniczak B, Ritkerj, Thomas M, Schmidt C et al. Diagnosis, treatment and outcome of patients with Askin's Tumor. *Thorac Cardivas Surg* 2000; 48: 311-5.
4. Hage R, DU Urkens Vam, Sel Denrijk CA, Brutel de la Riviere, Swieten HA, van den Bosch JMM. Primitive Neuroectodermal Tumor: report of two cases and review of literature. *J Thorac Cardiovasc Surg* 2002; 124: 833-6.
5. Drings P, Hasse J, Hermanek P, Wagner G. *Klassifikation maligner Thoraxtumoren Lunge. Pleura. Mediastinum*. Berlin, Heidelberg: Springer-Verlag 2003: 194.

6. Askin FB, Rosai J, Sibley RK et al. Malignant small cell tumor of the thoracopulmonary region in childhood. *Cancer* 1979; 43:2438-2451.
7. Contesso G, Llombart-Bosch A, Tarrier Ph, Peydro-Olaya A, Henry Amar M, Oberlin O et al. Does Malignant Small Round cell Tumor of the Thoracopulmonary region (Askin Tumor) constitute a clinicopathologic Entity. *Cancer* 1992; 69: 1012-20.
8. Schmidt D, Herrmann C, Jurgents H, Harms D. Malignant peripheral neuroectodermal tumor and its necessary distinction from Ewing's sarcoma. *Cancer* 1991; 68: 2251-9.
9. Takahashi K, Dambara T, Ueskusa T, Nukiwa T, Kira S. Massive chest wall tumor diagnosed as Askin's tumor. Successful treatment by intensive combined modality therapy in an adult. *Chest* 1993; 104: 287-8.
10. Linnoi RI, Tsoks M, Tirche TJ, Marangos PJ, Candra RS. Evidence of neural origin and PSA-positive variants of the malignant small cell tumor of thoracopulmonary region ('Askin tumor'). *Am J Surg Pathol* 1986; 10: 124-33.
11. Promnitz, Petri F, Schulz HJ, Gellert K. Der Askin-Tumor-eine Raritat. Ein Fallbericht mit Einflussen der Literatur. (Askin's tumor - a rare entity. Case report with influences from the literature) *Pneumologie* 1999, 53: 393-9.
12. Schmith D, Hermann C, J.rgens H et al. Malign peripheral neuroectodermal tumor and its necessary distinction from Ewing's sarcoma. *Cancer* 1991; 68: 2251-2259.
13. Dorfman HD, Czerniak B. Bone tumors. 1st Ed. St. Louis. Mosby; 1998, p.649-653.
14. Aksoy F, .zsan H, Derviþolu S et al. Parietal kemik yerleþimli Ewing sarkomu. *T.rk Patoloji Dergisi* 1994; 10: 56-58.
15. Hage R, Duurkensvam, Seldenrijk CA, Brutel de la Riviere, Swieten HA, van den Bosch JMM. Primitive neuroectodermal tumor: Report of two cases and review of the literature. *J Thorac Cardiovasc Surg* 2002; 124: 833.
16. Askin FB, Rosai J, Sibley RK et al. Malignant small cell tumor of the thoracopulmonary region in childhood. *Cancer* 1979; 43: 2438-2451.
17. Fraser RS, Pare PD, Colman N et al. Diagnosis of diseases of the chest, 4th ed.USA. W.B. Saunders Company; 1999; p.3028-3029.
18. Contesso G, Bosch AL, Terrier P et al. Does malignant small round cell tumor of the thoracopulmonary region (Askin Tumor) constitute a clinicopathologic entity? *Cancer* 1992; 69:1012-1020.
19. Ahmad R, Mayol BR, Davis et al. Extraskkeletal Ewing sarcoma. *Cancer* 1999; 85:725-731.
20. Baldini EH, Demetri GP, Fletcher CD et al. Adults with ESE/PNET: adverse effect of older age and primary extraosseous disease on outcome. *Ann Surg* 1999; 230: 79-86.
21. Angervakk L, Enzinger FM. Extraskkeletal neoplazm resembling Ewing sarcoma. *Cancer* 1975; 36:240-251.
22. Soule EH, Newton W, Moon TE et al. Extraskkeletal Ewing sarcoma. *Cancer* 1978; 42: 259-264.