

URETHRAL STRICTURE MANAGED WITH HOMEOPATHIC MEDICINE: A STUDY OF FOUR CASES

Nazmul Hasan*

DOI:
doi.org/10.3329/brc.v9i1.63605

Mirpur-1, Dhaka-1216. Bangladesh

ABSTRACT

Urethral stricture is the narrowing of the urethral mucosa, commonly resulting from trauma followed by inflammation and fibrous changes of the corpus spongiosum along the male urethra. Clinical manifestation contains gradual deterioration of hesitancy, intermittency, dribbling of urine, and in association with a sensation of incomplete voiding of the bladder, increased frequency, urgency, straining, and urethralgia during micturition. A low Qmax in Uroflowmetry will give a primary idea of stricture; however, a Retrograde Urethrography (RUG) confirms the stricture location, length, and other identifiable pathology affecting the urethra. In this particular disease, the scope of conventional medicinal treatment is limited, however, there transurethral (dilation, internal urethrotomy) and open surgical (stricture resection and anastomosis, urethroplasty, and perineal urethrostomy) procedures are available, and recurrence is common. Homeopathic medicine is mostly an individualized medicine with a minimum number and high dilution. The use of homeopathic medicine for urological diseases is an opportunistic option. However, a group of patients with similar set of symptoms might be treated with a specific homeopathic medicine. The author is reporting a study of four urethral stricture cases treated with homeopathic medicines, namely *Clematis erecta*, *Medorrhinum*, and *Aurum metallicum*; within 6-24 weeks of homeopathic medicine treatment, all four patients experienced improved uroflowmetry and RUG. The current study results shows homeopathic medicine helped the patients in a harmless, cost-effective way which might encourage awareness among the medical practitioners regarding the available homeopathic medicinal treatment of urethral stricture.

KEYWORDS: homeopathy in stricture, clematis erecta, urethrotomy, urethroplasty

Received: 19 August 2022, Accepted: 27 November 2022

Type: Original Research

*Corresponding Author: Dr. Nazmul Hasan,
Dr. Nazmul's Chamber, Mirpur-1, Dhaka-1216. Bangladesh.
Email: nazmul_1979@yahoo.com

Introduction

According to the International Consultation on Urological Disease (ICUD) panel, the urethral stricture is defined as a narrowing of the urethra resulting in ischemic spongio-fibrosis, and distinct from sphincter stenosis and a urethral disruption injury (Latini *et al.*, 2014). Most urethral strictures are idiopathic, traumatic, inflammatory, or iatrogenic (Lumen *et al.*, 2009). The major portion of patients present with slow and progressive deterioration of the urinary stream followed by a feeling of incomplete emptying of the bladder which may associate with splaying of the urinary stream, an increase of frequency and urgency, straining, and urethralgia during micturition (Bhuiyan, 2018). An uroflowmetry with a low Qmax will give a primary idea of urethral stricture; however, a Retrograde Urethrography (RUG) will provide information regarding the stricture location, length, and other identifiable pathology affecting the urethra. Another diagnostic tool, Cystourethroscopy, is more useful in assessing post-surgery follow-up (Hillary, Osman and Chapple, 2014). There is a scarcity of conventional medicinal treatment for urethral stricture, though surgical correction of the narrow segment is invariably suggested (Mundy and Andrich, 2011); however,

the surgical solution may lead to many complications including urinary incontinence, recurrent infection, impotence and recurrence of stricture (Lazzeri *et al.*, 2016).

The use of homeopathic medicine for urological deceases is an optimistic option (Mahesh *et al.*, 2019; Saruggia and Corghi, 1992). Homeopathic medicine is mostly an individualized medicine; however, a group of patients with the same set of symptoms might be treated with very-same homeopathic medicine (Banerji, Campbell and Banerji, 2008). This study revised the clinical features, diagnostic procedures, and treatment of patients with urethral stricture who received homeopathic medicine. The outcomes of this study may provide evidence to improve the understanding of clinicians regarding the application of homeopathic medicine in managing urethral strictures.

Materials and Methods

Four individual Asian males, within the age range of 25-39 years patients presented with a similar set of symptoms including increased frequency of micturition, burning pain during micturition, and obstructed micturition. As a prominent

practice, they contacted conventional medical services; Uroflowmetry and RUG confirmed their diagnosis as a case of Urethral Stricture. Initially, all patients were advised conservative treatment, but later, they were recommended for surgical intervention. However, all four patients decided to take homeopathic medicine instead of surgery. They were non-alcoholic, tobacco non-user, and maintained good health with no other health issues.

In this study three homeopathic medicines, *Clematis erecta*, *Medorrhinum* and *Aurum metallicum* were used. A four-weekly follow-up was taken from the patients, up to twenty-four weeks, and follow-up Uroflowmetry and RUG were performed at the end of homeopathic treatment. All three medicine were advised to take orally in the following dose and potency:

Table 1. List of used homeopathic medicines with their detailed preparation and administration

SL. No.	Medicine with potency	Used dilution and preparation	Administered
01	<i>Clematis erecta</i> 6C	0.5 ml dissolved with 60 ml distilled water and distributed in 15 equal doses	4 ml/24 hours, 2 ml in the morning and 2 ml at night, before meal
02	<i>Medorrhinum</i> 200C	0.5 ml dissolved with 30 ml distilled water and distributed in 4 equal doses	7.5ml/7 days, in the morning, after meal
03	<i>Aurum metallicum</i> 200C	0.5 ml dissolved with 30 ml distilled water and distributed in 4 equal doses	7.5ml/7 days, in the morning, after meal

Presentation of cases and repartorization of the cases

Case 1: A 25 years unmarried male presented with sufferings from chronic urinary tract infection, with pain and burning in the urethra during micturition, difficulty in micturition, and sensation as if the bladder outlet is obstructed.







Remedy	Clem	Puls	Dig	Calc	Graph	Merc
Totally	19	14	13	10	10	10
Symptoms Covered	8	4	4	4	4	4
Kingdom						
[Complete] [Urethra]STRICTURE: (86)	4	4	3	3	3	4
[Complete] [Urethra]STRICTURE:Gonorrhea, in: (27)	4	4	4	1	3	3
[Complete] [Urethra]PAIN:Burning, smarting:Emissions, pollutions, seminal:During:Stri...	3					
[Complete] [Mind]REMORSE, REPENTANCE: (124)	1	3	3	3	1	1
[Complete] [Mind]FEAR:Happen:Something will:Bad, evil: (158)	2	3	3	3	3	2
[Complete] [Male Genitalia]PAIN:Testes:Walking:Agg.: (18)	3					
[Complete] [Male Genitalia]PAIN:Burning, smarting:Penis:Prepuce:Frenum:Bathing, w...	1					
[Complete] [Male Genitalia]PAIN:Drawing:Testes:Extending to:Inguinal ring: (3)	1					

Figure 1. Symptoms of case-1 as indexed in Complete Repertory with a predictive list of medicine

Case 2: A 34 years old unmarried male was suffering from chronic urinary tract infection, with difficulties in micturition, feeling pain and burning from the urge to evacuation of urine, and needed to strain on evacuation. He became tired of the pain and got frustrated with the suffering of the disease.

Remedy	Clem	Dig	Puls	Merc	Sulph	Rhus-t	Phos
Totality	21	21	20	17	17	17	16
Symptoms Covered	8	6	6	6	6	5	6
Kingdom							
[Complete] [Urethra]STRICTURE: (86)	4	3	4	4	4	4	2
[Complete] [Urethra]STRICTURE:Gonorrhea, in: (27)	4	4	4	3	3	4	3
[Complete] [Urethra]PAIN:Burning, smarting:Emissions, pollutio...	3						
[Complete] [Urine]BURNING, HOT: (234)	3	4	3	4	4	3	4
[Complete] [Urethra]PAIN:Cutting: (110)	1	4	3	3	3	4	3
[Complete] [Mind]REMORSE, REPENTANCE: (124)	1	3	3	1	1		1
[Complete] [Mind]FEAR:Happen:Something will:Bad, evil: (158)	2	3	3	2	2	2	3
[Complete] [Male Genitalia]PAIN:Testes:Walking:Agg.: (18)	3						

Figure 2. Symptoms of case-2 as indexed in Complete Repertory with a predictive list of medicine

Case 3: A 37 year divorced male visited with heaviness in the lower abdomen, pain and burning in micturition, and increased urge to void.

Remedy	Clem	Dig	Puls	Ars	Merc	Sulph
Totality	24	17	17	15	14	14
Symptoms Covered	11	5	5	5	5	5
Kingdom						
[Complete] [Urethra]STRICTURE: (86)	4	3	4		4	4
[Complete] [Urethra]STRICTURE:Gonorrhea, in: (27)	4	4	4		3	3
[Complete] [Urethra]PAIN:Burning, smarting:Emissions, pollutions, seminal:During:Stricture, in: (1)	3					
[Complete] [Urine]BURNING, HOT: (234)	3	4	3	4	4	4
[Complete] [Mind]REMORSE, REPENTANCE: (124)	1	3	3	3	1	1
[Complete] [Mind]FEAR:Happen:Something will:Bad, evil: (158)	2	3	3	3	2	2
[Complete] [Male Genitalia]PAIN:Testes:Walking:Agg.: (18)	3					
[Complete] [Mind]SUICIDAL DISPOSITION:Despair, from: (21)	1			3		
[Complete] [Male Genitalia]PAIN:Burning, smarting:Penis:Prepuce:Frenum:Bathing, washing agg.: ...	1					
[Complete] [Male Genitalia]PAIN:Drawing:Testes:Extending to:Inguinal ring: (3)	1					
[Complete] [Mind]WEEPING, TEARFUL MOOD:Trembling, with: (3)	1			2		

Figure 3. Symptoms of case-3 as indexed in Complete Repertory with a predictive list of medicine

Case 4: A 39 years old married male visited with a frequent urge for micturition, sensation as if obstructed bladder outlet, and heaviness in the lower abdomen.

Remedy	Clem	Sulph	Rhus-t	Puls	Merc	Acon	Dulc
Totality	25	16	15	14	12	12	12
Symptoms Covered	11	5	5	5	5	4	4
Kingdom							
[Complete] [Urethra]STRICTURE: (86)	4	4	4	4	4	3	4
[Complete] [Urethra]STRICTURE:Gonorrhea, in: (27)	4	3	4	4	3	3	4
[Complete] [Urethra]PAIN:Burning, smarting:Emissions, pollutions, seminal:During:Stricture, ...	3						
[Complete] [Mind]FEAR:Happen:Something will:Bad, evil: (158)	2	2	2	3	2	3	2
[Complete] [Male Genitalia]PAIN:Testes:Walking:Agg.: (18)	3						
[Complete] [Male Genitalia]PAIN:Burning, smarting:Penis:Prepuce:Frenum:Bathing, washing ...	1						
[Complete] [Male Genitalia]PAIN:Drawing:Testes:Extending to:Inguinal ring: (3)	1						
[Complete] [Mind]WEARY OF LIFE:Fear of death, with: (10)	1		3			3	
[Complete] [Bladder]URINATION:Difficult, dysuria:Stricture, in: (10)	3	3	2	1	1		2
[Complete] [Urethra]PAIN:Burning, smarting:Coition:During: (10)	2	4			2		
[Complete] [Mind]IMOROSE, SULKY:Causeless: (11)	1			2			

Figure 4. Symptoms of case-4 as indexed in Complete Repertory with a predictive list of medicine

Follow-up and Results

Considering the presenting symptoms of the patients, individual repartorization was done and found *Clematis erecta* is the most similar. The selected medicine was given for 4 weeks at the previously stated dose and potency (Table 1). All the patients were feeling much more comfortable till 4th week of homeopathic treatment, but after the 8th week, the patients were not feeling improvement as they experienced previously. Another reviewing the case history and considering the incidence of gonorrhoea, *Medorrhinum* was given for four weeks along with higher potency of *Clematis erecta* (Table 1, and 2). After twelve weeks, all patients felt much better and continued *Clematis erecta* only. At the end of, 16 weeks their

physical symptoms were reduced significantly, however, patients of cases 1, 2, and 3 were feeling a little despair about their disease; bearing this symptom these patients were advised *Aurum metallicum* as stated in Tables 1 and 2. By the end of twenty weeks, all patients were feeling much better with a reduction of most of the symptoms; this time placebos were given to them, and asked to report with a follow-up Uroflowmetry and RUG. After twenty-four weeks, follow-up RUG was found with dilated bulbous part of the urethra of case 1 and case 4 (Figures 5, and 8). An improved Qmax in follow-up Uroflowmetry of case 2, and case 3 (Figures 6, and 7) was also observed.

Table 2. Patient follow-up till twenty-four weeks of homeopathic treatment

Visit	Patient condition	Prescribed medicine	Justification
1 st Visit	Features of UTI and Urethral stricture	<i>Clematis erecta</i> , orally in 6C dilution (0.5 ml dissolved with 60 ml distilled water) and distributed in 15 equal doses, (4 ml/24 hours, 2 ml in the morning and 2 ml at night, before meal), for 4 weeks	Selected on similimum
2 nd Visit, after 4 weeks	The patients expressed their easiness	<i>Clematis erecta</i> , orally in 6C dilution (0.5 ml dissolved with 60 ml distilled water) at the same dose for the next 4 weeks	Patients were feeling better
3 rd Visit, after 8 weeks	The patients expressed less easiness than was observed before.	<i>Clematis erecta</i> , orally in 30C dilution (0.5 ml dissolved with 60 ml distilled water) at the same dose for the next 4 weeks	Seems the previous potency stopped working, and potency increased.

		<i>Medorrhinum, orally in 200C dilution</i> (0.5 ml dissolved with 30 ml distilled water) and distributed in 4 equal doses (7.5ml/7 days, in the morning, after meal), for the next 4 weeks	Considering gonorrhoea in the background, it was advised once a week.
4 th Visit, after 12 weeks	Pain and burning reduced significantly, and urine volume increased.	<i>Clematis erecta, orally in 30C dilution</i> (0.5 ml dissolved with 60 ml distilled water) at the same dose for the next 4 weeks	Patients were feeling better
5 th Visit, after 16 weeks	Symptoms reduced. Patients of case 1, case 2 and case 3 felt depressed.	<i>Clematis erecta, orally in 30C dilution</i> (0.5 ml dissolved with 60 ml distilled water) at the same dose for the next 4 weeks	Patients were feeling much better.
		<i>Aurum metallicum, orally in 200C dilution</i> (0.5 ml dissolved with 30 ml distilled water) and distributed in 4 equal doses (7.5ml/7 days, in the morning, after meal), for the next 4 weeks	Considering their suicidal disposition, and thwarting, it was advised once a week.
6 th Visit, after 20 weeks	Most of the symptoms reduced	Placebo was advised for the next 4 weeks	Advised to perform follow-up RUG and Uroflowmetry
7 th Visit, after 24 weeks	Almost all symptoms were relieved	No other medicine was advised	Satisfactory RUG or Uroflowmetry observed

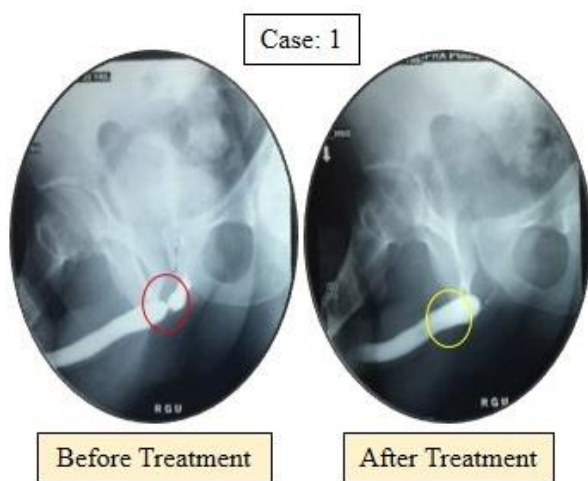


Figure 5. A urethral stricture found at the bulbous part of the urethra which resolved after treatment

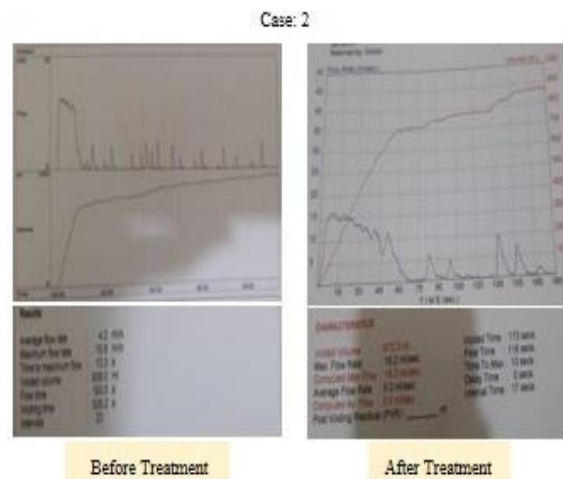


Figure 6. Before treatment, uroflowmetry shows a low Qmax/urine flow rate, 15.6 ml/s with 23-sec intermittence; after treatment, uroflowmetry shows increased Qmax/urine flow rate with 16.2ml/s with 17-sec intermittence

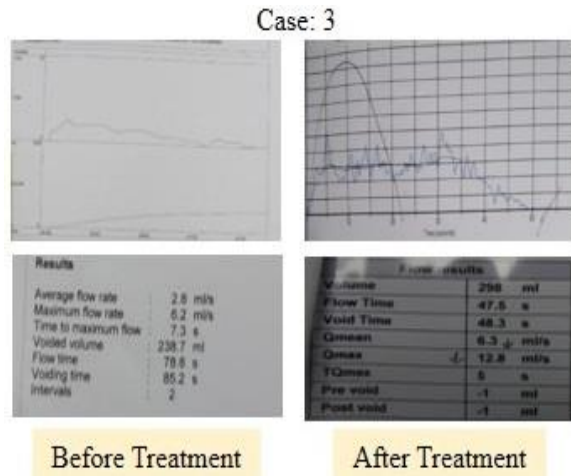


Figure 7. Before treatment, uroflowmetry shows a low Qmax/ urine flow rate, 6.2ml/s; after treatment, uroflowmetry shows an improved Qmax/urine flow rate, 12.8ml/s.

Discussion

Management of bulbar urethral stricture is very challenging and surgical intervention is one of the major reconstructive-surgery problems (Barbagli *et al.*, 2020). Moreover, the fear of becoming low-steamed in penile erection after urethrotomy is one important concern (Sangkum *et al.*, 2015) [12]. The scope of homeopathic medicine in urinary tract diseases is evident (Sharma *et al.*, 2018, Hasan *et al.*, 2018), however, there is a scarcity of evidence to prove the scope of homeopathic medicine in urethral stricture management.

Several homeopathic medicines cover urethral stricture-associated symptoms including *Apis mellifica*, *Aurum metallicum*, *Cantharis*, *Clematis erecta*, *Digitalis purpurea*, *Medorrhinum*, *Sulfur iodatum*, *Thuja occidentalis*, etc. (Murphy, 2003). According to homeopathic philosophy, a group of symptoms is considered to select individualized homeopathic medicine (Manchanda *et al.*, 2021). Repartorization is a numeric gradation process of homeopathic symptoms that helps in homeopathic remedy selection, and Roger van Zandvoort's 'The Complete Repertory' is one of the popular repertories (Van Zandvoort, 1994). The above discussion rationalizes the use of *Clematis erecta* in these four cases of urinary tract infection with urethral stricture.

Homeopathic medicine usually contains within ethanol (Chirumbolo and Bjørklund, 2018). Ethanol-based *Clematis* plant solution has the potential for anti-inflammatory property (Yesilada *et al.*, 2007), which also amplifies the significance of the selection of *Clematis* in these very cases. *Medorrhinum*, an important Nosodes medicine, is indicated in many cases including in gonorrhea-suppression-induced clinical conditions, and to break the miasmatic barrier (Murphy, 2003; Boericke, 2002; Sheeba *et al.*, 2020), which also implies the logic of using this medicine in these cases. A homeopathic preparation of *Aurum metallicum* is effective in healing the 'guilt-induced despair' state (Murphy, 2003; Boericke, 2002), also reasoning the use of this medicine in those particular cases (Table 2).

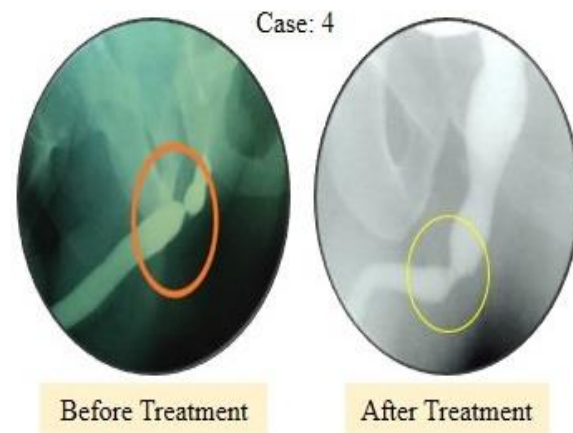

Figure 8. A urethral stricture found at the bulbous part of the urethra which improved after treatment

Conclusion

Urethral stricture is a notorious and painful clinical condition that causes serious stress on males, both physical and mental; the limitation of available effective conventional medicine, and the risk of unfavorable surgery increases this anxiety. Even well-planned experiments have some limitations, this study isn't an exception, such as only a few numbers of participants, a lack of comparison with other related homeopathic medicines, and a lack of explanation of homeopathic medicine's mode of action. However, this case study could be considered a demonstration of homeopathy treatment in the management of urethral strictures. Further studies are needed to understand the mechanism of homeopathic medicine and prospects of other homeopathic medicines on urethral strictures.

References

1. Latini JM, McAninch JW, Brandes SB, Chung JY, Rosenstein D. SIU/ICUD consultation on urethral strictures: epidemiology, etiology, anatomy, and nomenclature of urethral stenoses, strictures, and pelvic fracture urethral disruption injuries. *Urology*. 2014 Mar 1;83(3):S1-7.
2. Lumen N, Hoebeke P, Willemsen P, De Troyer B, Pieters R, Oosterlinck W. Etiology of urethral stricture disease in the 21st century. *The Journal of urology*. 2009 Sep;182(3):983-7.
3. Bhuiyan ZH. Male Urethral Strictures: Management Options. *Bangladesh Journal of Urology*. 2018;21(2):158-63.
4. Hillary CJ, Osman NI, Chapple CR. Current trends in urethral stricture management. *Asian journal of Urology*. 2014 Oct 1;1(1):46-54.
5. Mundy AR, Andrich DE. Urethral strictures. *BJU international*. 2011 Jan;107(1):6-26.
6. Lazzeri M, Sansalone S, Guazzoni G, Barbagli G. Incidence, causes, and complications of urethral stricture

- disease. *European Urology Supplements*. 2016 Jan 1;15(1):2-6.
7. Lazzeri M, Sansalone S, Guazzoni G, Barbagli G. Incidence, causes, and complications of urethral stricture disease. *European Urology Supplements*. 2016 Jan 1;15(1):2-6.
 8. Mahesh S, Jaggi L, Jaggi A, Tsintzas D, Vithoulkas G. Individualised homeopathic therapy in ANCA negative rapidly progressive necrotising crescentic glomerulonephritis with severe renal insufficiency—a case report. *Journal of Medicine and Life*. 2019 Jan;12(1):49.
 9. Saruggia M, Corghi E. Effects of homeopathic dilutions of china rubra on intradialytic symptomatology in patients treated with chronic haemodialysis. *British Homoeopathic Journal*. 1992 Apr 1;81(2):86-8.
 10. Banerji P, Campbell DR, Banerji P. Cancer patients treated with the Banerji protocols utilising homeopathic medicine: A Best Case Series Program of the National Cancer Institute USA. *Oncology Reports*. 2008 Jul 1;20(1):69-74.
 11. Barbagli G, Bandini M, Balò S, Sansalone S, Butnaru D, Lazzeri M. Surgical treatment of bulbar urethral strictures: tips and tricks. *International braz j urol*. 2020 Jun 1;46:511-8.
 12. Sangkum P, Levy J, Yafi FA, Hellstrom WJ. Erectile dysfunction in urethral stricture and pelvic fracture urethral injury patients: diagnosis, treatment, and outcomes. *Andrology*. 2015 May;3(3):443-9.
 13. Sharma, B., Mehra, P., Oberai, P., Roja, V., Reddy, G.R.C., Arya, D.D., Mohanan, P.G., Padmanabhan, M., Manchanda, R.K. and Kumar, B.S.J., 2018. Homeopathic treatment for lower urinary tract symptoms in men with benign prostatic hyperplasia: An open label randomised multicentric placebo-controlled clinical trial.
 14. Hasan N, Kayes ME, Alom MJ, Kayes MK. Hydrangea arborescence and Berbaris vulgaris Ease Ureteric Calculi Emission: Single Case Report. *International Journal of Medical and Pharmaceutical Case Reports*. 2018 Feb 15:1-5.
 15. Murphy R. *Lotus materia medica*. B. Jain Publishers; 2003.
 16. Manchanda RK, Miglani A, Gupta M, Meena BS, Chadha V, Joseph F, Kalsi A, Konthembath P, Sharma K, Rama KN, Kaur P. Homeopathic remedies in COVID-19: prognostic factor research. *Homeopathy*. 2021 Aug;110(03):160-7.
 17. Van Zandvoort R. *The complete repertory*. Institute for Research on Homeopathic Information and Symptomatology; 1994.
 18. Chirumbolo S, Bjørklund G. Homeopathic dilutions, Hahnemann principles, and the solvent issue: must we address ethanol as a “homeopathic” or a “chemical” issue?. *Homeopathy*. 2018 Feb;107(01):040-4.
 19. Yesilada E, Küpeli E. *Clematis vitalba* L. aerial part exhibits potent anti-inflammatory, antinociceptive and antipyretic effects. *Journal of Ethnopharmacology*. 2007 Apr 4;110(3):504-15.
 20. Boericke W. *Pocket Manual of Homoeopathic Materia Medica & Repertory: Comprising of the Characteristic and Guiding Symptoms of All Remedies (clinical and Pahtogenetic [sic]) Including Indian Drugs*. B. Jain publishers; 2002.
 21. Sheeba, S., Narayan, M., Sylum, S., Reghu, R. and Sheeba, S., 2020. Clinical study on the anti-miasmatic approach of patients with cervical spondylosis and its Homoeopathic Management.