

Case Report

Diaphragmatic Hernia (Bochdalek Hernia) in an Adult: a Case Report

RK Saha¹, ASMT Rahman², D Roy³, AS Ahmed⁴, A Tarif⁵, MT Hussain⁶, S Saha⁷

Abstract:

Bochdalek hernia (BH) is the most common type of congenital diaphragmatic hernia and constitutes 85% of cases. In adults BH is extremely rare. Most of them are asymptomatic. We present a case of BH in an adult patient to point out the importance of clinical examination and computed tomography (CT) scan in reaching the exact diagnosis. A 17-year-old male was presented to the surgery department with a 3-days history of recurrent abdominal pain, vomiting and unable to lie flat. The BH was confirmed on computed tomography (CT) imaging and the patient underwent emergency laparotomy and per-operatively we found part of stomach, greater omentum, splenic flexure of colon along with spleen herniated into the left hemithorax through a defect of approximately 8x6cm in the left postero-lateral aspect of the diaphragm. Reduction of hernia contents and surgical repair of the defect was done with non-absorbable suture. His post-operative period was uneventful. Although rare, this disorder should be recognized and treated appropriately to avoid complications.

Key words: Bochdalek hernia, Laparotomy.

Introduction:

Diaphragmatic hernia occurs in a defect of the diaphragm, through which loops of small and large bowel, stomach, liver, and spleen may protrude into the thoracic cavity of the involved side. This defect of the diaphragm can be either congenital or acquired after a blunt trauma^{1,2}. The incidence of congenital diaphragmatic hernias (CDH) is 1 in 2500 births and left sided CDH is more common than right-side (85% and 12%, respectively)³. Although CDH is diagnosed prenatally or in the immediate postnatal period, in 5-25% of cases diagnosis can be late, and could be detected during routine examinations or examination

because of respiratory or gastrointestinal problems³. Bochdalek hernia (BH) is a variety of congenital diaphragmatic hernia caused by failure fusion of the posterolateral diaphragmatic foramina; resulting in the displacement of abdominal contents into thoracic cavity⁴. Bochdalek first described this anomaly in 1848⁴. BH is very rare beyond childhood with an incidence of 0.17%. Diaphragmatic hernias are usually asymptomatic in adults⁵. In 5–10% of affected individuals, signs and symptoms of appear later in life and may include respiratory or GI problems⁶.

1. Prof. Ratan Kumar Saha, MBBS, FCPS (Surgery), Professor & Head, Department of Surgery, Bangabandhu Sheikh Mujib Medical College, Faridpur.
2. Dr. A.S.M. Tanjilur Rahman, MBBS, FCPS (Surgery), Junior Consultant, Department of Surgery, Bangabandhu Sheikh Mujib Medical College Hospital, Faridpur.
3. Dr. Dipankar Roy, MBBS, FCPS (Surgery), Registrar, Department of Surgery, Bangabandhu Sheikh Mujib Medical College Hospital, Faridpur.
4. Dr. Abu Saleh Ahmed, MBBS, FCPS (Surgery),

- Registrar, Department of Surgery, Bangabandhu Sheikh Mujib Medical College Hospital, Faridpur.
5. Dr. Adnan Tarif, MBBS, MS (Paediatric Surgery), Registrar, Department of Surgery, Bangabandhu Sheikh Mujib Medical College Hospital, Faridpur.
6. Dr. Md. Tofazzal Hussain, MBBS, Assistant Registrar, Department of Surgery, Bangabandhu Sheikh Mujib Medical College Hospital, Faridpur.
7. Dr. Sumit Saha, MBBS, HMO, Department of Surgery, Bangabandhu Sheikh Mujib Medical College Hospital, Faridpur.

Address of the correspondence:

Dr. Dipankar Roy, Registrar, Dept. of Surgery, Bangabandhu Sheikh Mujib Medical College Hospital, Faridpur. Phone: +88 01717 388828, Email- dr.dip99@gmail.com

Symptomatic hernias are misdiagnosed in up to 38% of cases leading to unnecessary interventions such as chest tube insertion or failure to diagnose which could lead to strangulation of the herniated content and death⁷.

Case report:

A 17-year-old boy came to our surgery department with the complaints of recurrent upper abdominal pain for last 1 year which was burning in nature, insidious on onset, non-radiating and aggravated after taking meal. The pattern of pain changed to continuous and agonizing nature with increasing severity for last 3 days before hospital admission with vomiting for several times for last 24 hours. He gave no history of surgery or trauma. On examination, abdomen was diffusely tender, maximum over epigastric & left hypochondriac region, with rigidity and muscle guarding. Chest movement was normal, vocal fremitus was reduced on left side, percussion note was dull and on auscultation breath sound was diminished on left lower chest with presence of bowel sounds in the left hemithorax. Plain X-ray abdomen showed loops of bowel were high-up, lying in the left lower hemithorax. There was no evidence of pneumoperitoneum or abnormal air fluid level (Figure-1).

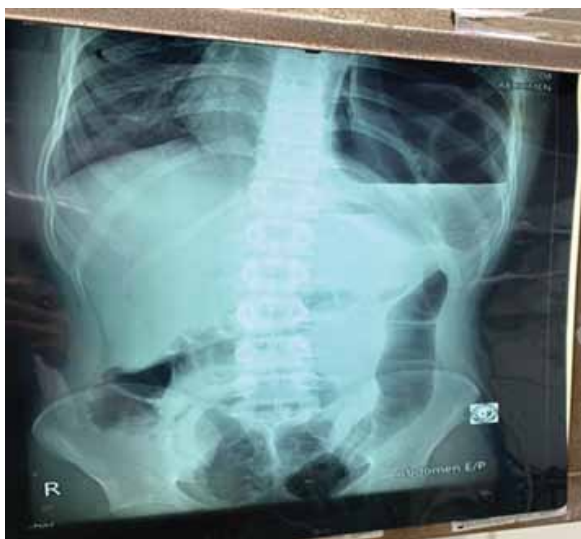

Figure 1: Plain X-ray abdomen showed loops of bowel were high-up, lying in the left lower hemithorax, no evidence of pneumoperitoneum or abnormal air fluid level was seen.

CT scan of chest showed large bowel loop along with peritoneal fat entered into left hemithorax through abnormal opening in the postero-lateral aspect of diaphragm, left lung is collapsed & mediastinum was shifted to the right (Figure-2).

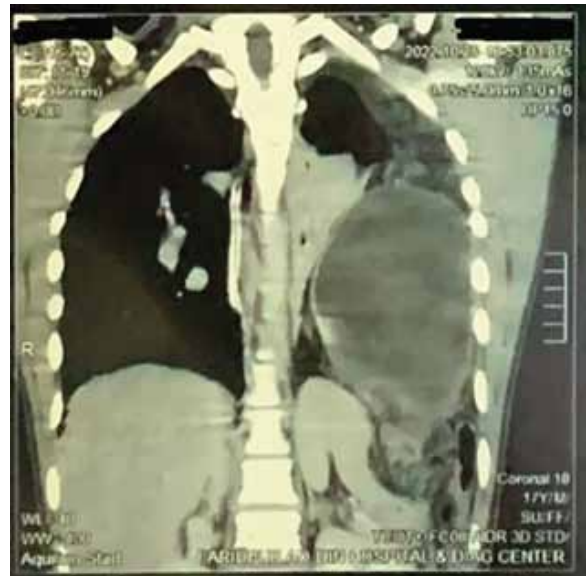

Figure 2: Coronal section of CT scan of chest showing large bowel loop along with peritoneal fat entered into left hemithorax.

Other laboratory investigations were within normal limit. At first, the patient was resuscitated. Then an emergency laparotomy was arranged. After opening the abdomen, we found part of stomach, omentum, splenic flexure of colon along with spleen herniated into the left hemithorax through a defect of approximately 8x6cm in the postero-lateral aspect of the diaphragm. Reduction of hernial contents was done meticulously, viability checked and primary repair of the defect was done by 1-0 polypropylene suture (Figure 3).

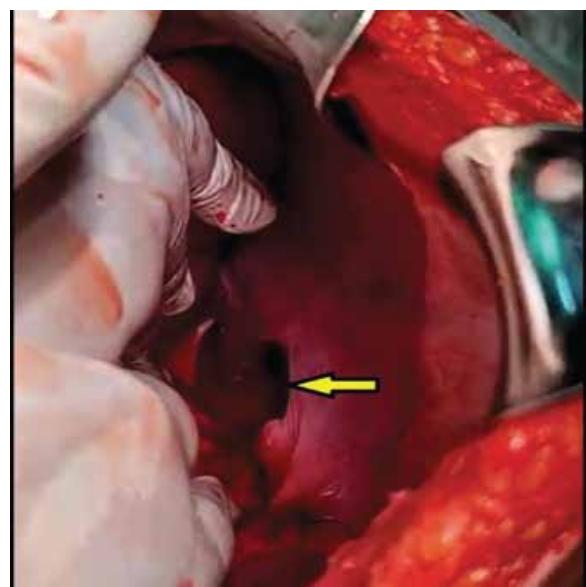


Figure 3: Showing the defect of diaphragm

Abdominal drain tube was kept in the site of repair & a chest drain tube was inserted. Nasogastric tube was kept for 3 days. He was kept nothing per oral for 3 days. Post-operative period was uneventful (Figure-4).

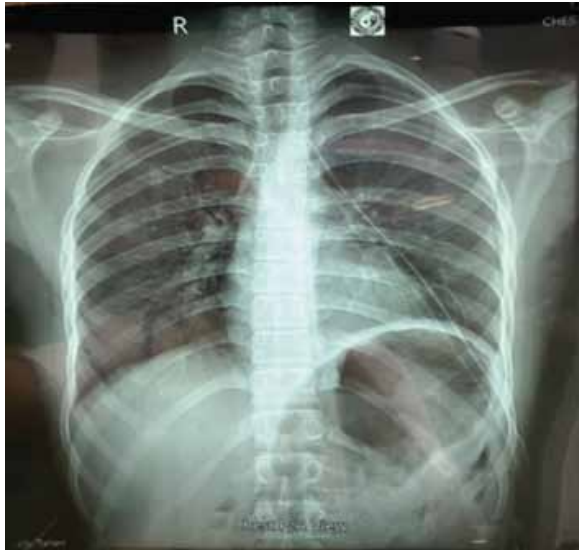

Figure 4: Post-operative chest x-ray P/A view showing chest drain tube in situ, normal contour of left dome of diaphragm, gastric bubble below the left dome of diaphragm.

Discussion:

Congenital diaphragmatic hernias, clinically represented in adult life are extremely rare, and they can occur through the frontal parasternal opening (Morgagni hernia 1-6%) or through the postero-lateral opening (Bochdalek hernia 80-90%)⁸. Postero-lateral (Bochdalek hernia) is the most common type of congenital diaphragmatic hernias that occurs in 95% of cases, resulting from inadequate closure of the posterolateral pleuroperitoneal membranes⁹. The overall prevalence of Bochdalek hernias in adults is 6-10%¹⁰. Literature review reveals that defects occur more frequently on the left side (80-90%) than on the right side of the diaphragm, and the hernia contents included omentum, left colon, stomach, small bowel loops and spleen¹¹. In adults, most Bochdalek's hernias are asymptomatic, and thus the finding of the condition is incidental. Some patients have no symptoms and the disorder is unexpectedly detected on a chest X-ray or CT scan of the thorax. Symptomatic cases of Bochdalek's hernia in adults are rare. They are diagnosed in adults as an incidental medical finding or when the symptoms appear. Our patient presented with abdominal pain, vomiting and unable to lie flat. Acute presentation is usually due to incarceration, obstruction, or

strangulation of the hernia. Diagnosis is confirmed by a combination of chest X-ray and computed tomography (CT). Chest CT is usually the imaging of choice¹².

The management of Bochdalek hernia includes reduction of hernial contents to the peritoneal cavity and repair of the diaphragmatic defect¹³. Various surgical repair options include open surgery, laparoscopic repair, and thoracoscopic approach. Although laparotomy was the most widely used surgical approach, minimally invasive surgical techniques have gained popularity since their first report in 1995¹⁴. Laparoscopic repair can be performed with a low complication rate (7%) and short hospital stay¹⁴. Several authors suggested an abdominal approach for left-sided defects and a thoracic approach for right-sided hernias¹¹. Regardless of the type of surgical procedure, suturing the defect is likely important for the restoration of the anatomy between the thoracic and abdominal cavities. In patients with large diaphragmatic hernias, synthetic or biologic grafts can be used for definitive treatment and prevention of recurrence but it has some complications like adhesion formation with diaphragm¹⁵. In our patient the size of the defect in the diaphragm was 8 cm wide. We decided to open repair of the hernia instead of attempting laparoscopic repair. Nevertheless, a tensionless type of repair has been validated as an option for BHs, which is similar to the type of repair used for all other hernia repairs¹⁴. Diaphragm hernia repair approaches can cause postoperative pneumonia, deep venous thromboembolism, myocardial infarction, or sepsis¹⁵. In our case, none of these complications occurred.

Conclusions:

Patients with a Bochdalek hernia may not have any symptoms and the condition may present as an acute abdomen or with respiratory problems. Examination of the chest may give strong suspicion and chest radiography is a good screening tool but CT scan has higher sensitivity for these lesions. Even though rare, this disorder should be recognized and treated appropriately to avoid complications.

References:

1. Killeen KL, Mirvis SE, Shanmuganathan K. Helical CT of diaphragmatic rupture caused by blunt trauma. *AJR. American journal of roentgenology.* 1999 Dec; 173(6):1611-6.
2. Kearney PA, Rouhana SW, Burnay RE. Blunt rupture of the diaphragmatic: mechanism, diagnosis and treatment. *Ann Emerg Med.* 1989; 18:1326-30.

3. Topor L, Pătrăncuș T, Caragața R, Moga A. Left congenital diaphragmatic hernia—Case report. *Chirurgia (Bucur)*. 2015 Jan 1; 110(1):84-7.
4. Sutedja B, Muliani Y. Laparoscopic repair of a Bochdalek hernia in an adult woman. *Asian Journal of Endoscopic Surgery*. 2015 Aug; 8(3):354-6.
5. Testini M, Girardi A, Isernia RM, De Palma A, Catalano G, Pezzolla A, et al. Emergency surgery due to diaphragmatic hernia: case series and review. *World J Emerg Surg*. 2019; 17(14):48.
6. Baerg J, Kanthimathinathan V, Gollin G. Late-presenting congenital diaphragmatic hernia: diagnostic pitfalls and outcome. *Hernia*. 2012; 16(4):461–6.
7. Malekzadegan A, Sargazi A. Congenital diaphragmatic hernia with delayed presentation. *Case reports in Surgery*. 2016 Oct 30; 2016.
8. Kumar A, Maheshwari V, Ramakrishnan TS, Sahu S. Caecal perforation with faecal peritonitis—unusual presentation of Bochdalek hernia in an adult: a case report and review of literature. *World Journal of Emergency Surgery*. 2009 Dec; 4(1):1-6.
9. Salacin S, Alper B, Cekin N, Gulmen MK. Bochdalek hernia in adulthood: a review and an autopsy case report. *J Forensic Sci* 1994; 39: 1112-16.
10. Ilkins AC, Govodes GF, Hibbeln JF. Imaging findings in adult Bochdalek hernias. *Clin Imaging* 1994; 18: 224- 29.
11. Gligorievski A. Left Sided Bochdalek Hernia in Adult: A Case Report. *Frontiers in Medical Case Reports*. 2018 Mar 5.
12. Irish MS, Holm BA, Glick PL. Congenital diaphragmatic hernia: a historical review. *Clinics in perinatology*. 1996 Dec 1; 23(4):625-53.
13. Patle NM, Tantia O, Prasad P, Das PC, Khanna S. The management of Bochdalek hernia includes reduction of hernial contents to the peritoneal cavity and repair of the diaphragmatic defect. *Indian J. Surg*. 2013 Jun; 75(Suppl 1):303-4.
14. Yagmur Y, Yiğit E, Babur M, Gumuş S. Bochdalek hernia: a rare case report of adult age. *Annals of Medicine and Surgery*. 2016 Feb 1; 5:72-5.
15. Ercan M, Aziret M, Karaman K, Bostancı B, Akoğlu M. Dual mesh repair for a large diaphragmatic hernia defect: An unusual case report. *International journal of surgery case reports*. 2016 Jan 1; 28:266-9.