

The Aging Voice

Kamrul Hassan Tarafder¹, Pran Gopal Datta², Ahmed Tariq³

¹Professor, Department of Otolaryngology and Head-Neck Surgery, ²Vice Chancellor, ³MS Student, Bangabandhu Sheikh Mujib Medical University (BSMMU), Dhaka

Abstract:

Aging of voice is an unseen issue perceived by sounding 'old'. This involves a widespread change throughout the upper and lower airway mainly affected by the change in anatomy and physiology of vocal fold/cord. Thinning of laryngeal mucosa, atrophy of vocal muscles, reduced movement of cricoarytenoid joint, reduced lung volume and capacities; reduced movement of tongue, jaw as well systemic conditions may all affect the normal voice in older ages. Higher pitch voice in men, lower pitch voice in women, 'thin' voice, vocal fatigue, difficulty in being heard in noisy situations, tremor or shakiness in the voice are common changes found in old people. Various pathological conditions of larynx may cause voice change similar to aging voice. This can be differentiated endoscopically by an experienced Otolaryngologist. Avoidance of smoking, shouting, gastric reflux, resting the throat during a cold attack are simple measures that can delay aging process of our voice. 'Voice related quality of life index' is a quick & easy measurement of voice quality based on changes in last two weeks. Voice therapy and phonosurgery with injectable materials in vocal fold can improve the voice in advanced age.

Key words: Aging voice, voice therapy, vocal surgery.

[BSMMU J 2012; 5(1):83-86]

Introduction:

When we age, not only our aches and pains worsen, our skin wrinkles, teeth fall out, and our hair disappears, voices show sign of age as well. Few of us just think about how important it is until it stops functioning properly. In advanced age, we lose some of the fine coordination that we had in younger years, we lose muscle mass, our mucous membrane become thin and dry. Aging affects two main aspects of vocal fold anatomy and function. First, much like muscles elsewhere in the body, muscles of the vocal fold lose bulk (atrophy). Second, the flexible tissues which are responsible for vocal fold vibration during voicing (i.e. superficial lamina propria) become thinner, stiffer and less pliable. Together these changes sometimes result in voice which is perceived as sounding 'old'.

The aging and upper aerodigestive tract:

The phonatory organ is composed of the resonator (larynx), the articulator (supraglottic structures) and the compressor (lungs). Age related changes in any one or all of these structures can have a direct impact on voice quality and general comfort level (direct factors).¹

The respiratory system changes from young adulthood to old age. In lung tissue, loss of elasticity is the most significant change while other changes include stiffening of the thorax and weakening of respiratory muscles. These changes alter lung volumes and respiratory mechanics. While total lung volume remains unchanged in the elderly, vital capacity decreases and residual volume increases. Maximum expiratory flow rate declines and lung pressure decreased. The larynx also undergoes age related anatomic changes during adulthood. Many of the changes are more extensive in males, including ossification and calcification of laryngeal cartilages, atrophy and degeneration of intrinsic muscles, restricted movement of CA (cricothyroid) joint, degeneration of mucosal glands, lamina propria and conus elasticus. In elderly males, changes in the CA joint may affect function by lessening vocal fold approximation during phonation. Dryness of epithelium causes stiffening of vocal cord cover leading to instability of vocal fold vibration and raise fundamental frequency (F_0) in elderly men. Changes in the supralaryngeal system include a process of "symmetrical enlargement" of the craniofacial skeleton (3-5%) from young adulthood to old age. Atrophy of facial, masticatory and pharyngeal muscles is reported in the elderly along with lowering of the larynx in the neck. Degenerative changes in the temporomandibular joint, thinning/ loss of elasticity of oral mucosa, declining salivary function, loss

Address for Correspondence: Dr. Kamrul Hassan Tarafder, Professor, Department of Otolaryngology and Head-Neck Surgery, Bangabandhu Sheikh Mujib Medical University (BSMMU), Dhaka

of tongue strength, and tooth loss – all affects the speech.²

Furthermore, the older population are often exposed to a wide array of environmental and medicinal irritants that compound the problem, particularly in the case of long term tobacco smoking (indirect factors).³

Older patients may also suffer from medical conditions that can affect vocal quality, such as carcinoma, vocal cord palsy, Parkinson's disease, amyotrophic lateral sclerosis, benign essential tremor, diabetes and other endocrine dysfunctions. The frequent occurrence of depression with SNHL can lead to a hyperfunctional voice and muscle tension dysphonia (MTD).^{4,5,6,7}

Common Changes in the voice as we age:

- Higher pitch voice in men, lower pitch voice in women
- Reduced volume & projection of the voice ('thin' voice)
- Reduced vocal endurance
- Difficulty in being heard in noisy situations
- Tremor or shakiness in the voice

Above symptoms are complicated by reduced hearing ability that commonly occurs in our peers as we age.⁸

What Do Age Related Vocal Folds Look Like?

Under normal circumstances, the edge of the vocal fold stretches in a straight line between its attachments from thyroid cartilage to arytenoid cartilages in back of the larynx. Atrophy of the vocal fold muscle and thinning of the superficial vibratory tissues generally causes the edge to take on a scalloped appearance (Fig - 1).⁹

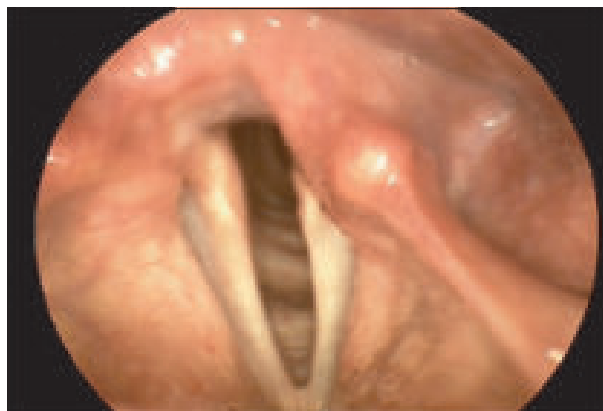

Fig.-1: Thinning of vocal fold tissues causes the vocal fold margin to appear scalloped or concave.

In addition, the vocal folds are thinner and less plump. The cartilages are more starkly outlined, in particular, the vocal processes of the arytenoid cartilages may stand out, mistaken for a mass, like a polyp or a cyst (Fig - 2).

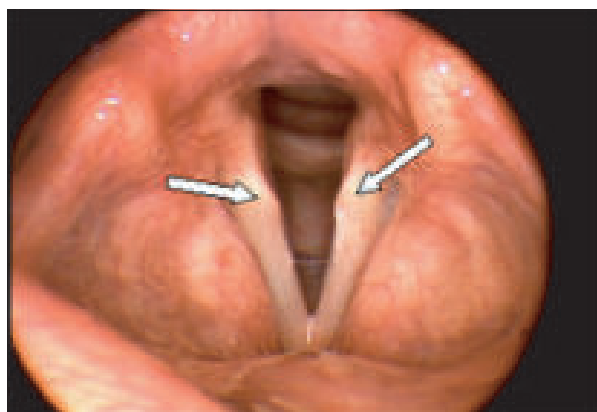


Fig.-2: Normal projections of cartilage (arrows) appear to stand out as abnormal masses in these thinned vocal folds.

During voicing, the vocal fold edges do not come together in the middle because they have lost bulk. This produces a gap between the vocal folds in the shape of a spindle. This spindle-shaped gap has been accepted among otolaryngologists as the definitive sign of age-related voice change (Fig.-3).

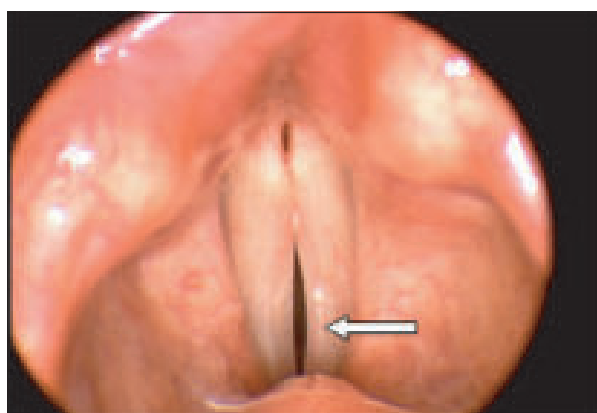


Fig.-3: Thinned vocal folds are not able to close completely during voicing, and leave a characteristic spindle-shaped gap.

Individuals should be aware that there are other reasons for such a gap, and also that the gap alone is not the whole problem underlying age-related voice changes.¹⁰

How to minimize effect of aging on voice?

Couple of ways to minimize the changes that causes with growing older -

DRINK MORE FLUID: Drink at least 1.5 - 2 liters of water a day. Moisture for the larynx is like grease for a ball-bearing. No liquids touch the vocal cords, but they are lubricated by saliva like fluid made by nearby glands. For the vocal folds to vibrate well, the body must be kept hydrated enough to make this lubrication sipping.

AVOID SPICY FOOD: We may not feel or taste it, but a common cause of damage to the voice is gastric acid reflux. It irritates and dries out the larynx. Signs of silent reflux are:

- throat clearing, frequent hawking,
- a croaky lower voice in the morning and
- the feeling of having a lump in the throat

Avoid foods with an irritating effect on the stomach, such as onions, chili, fizzy drinks and chocolate. Avoid eating two hours before bed.

DON'T SHOUT: Shouting can inflame the vocal cords. Repeated 'banging' can lead to nodules of the cord. These make the larynx work harder, causing muscle tiredness and discomfort. Teachers, singers, vendors, lawyers, political personnel and telephone workers are the prone groups for damaging their voices. Keep calm and anyone who has to shout at work should rest their voice for 5 minutes/hour.

CUT BACK ON SMOKING: Smoking dries up the laryngeal mucosa and stopping working the vocal cords properly. Nicotine also exacerbates gastric reflux, while the heat from the smoking can scar the vocal cords.

REST THE THROAT DURING A COLD ATTACK: Vocal cords can become scarred if used during a bad cough or sore. Anyone having a cold with laryngitis should rest his/her voice for a day or two. Healing by scarring means lesser chance to vibrate well. Voice may sound rough and someone may lose his/her upper register permanently.

IMPROVE POSTURE: Take exercise regularly which is essential to keep the voice young. Slumping causes change in the entire vocal tract; preventing deep breathing and making the vocal cords work harder. This can be tested by standing straight & saying 'e' and then moving the head forward. Physical exercise strengthens the abdominal muscles, ensuring a better airflow through the voice box, producing a stronger tone.¹¹

SING LOUD: Reading a paper loudly for 10–15 minutes, 2-3 times a day, as well as singing with the radio/ in the shower is good ways to preserve voice. Voice of the professional singers take longer to age, as they keep their laryngeal muscles strong.

What Can Be Done About Age-Related Voice Change?

Someone bothered with aging voice can take action today. By answering a short series of questions (Voice- Related Quality of Life quiz) available on the American Academy of Otolaryngologist web site, quality of voice can be assessed.¹² Answers should be based upon average voice quality over the past 2 weeks or so.

Because of my voice...	How much of a problem is this?				
I have trouble speaking loudly or being heard in noisy situations.	1	2	3	4	5
I run out of air and need to breathe frequently when talking.	1	2	3	4	5
I do not know what will come out when I begin speaking.	1	2	3	4	5
I am anxious / frustrated.	1	2	3	4	5
I get depressed.	1	2	3	4	5
I have trouble using the telephone.	1	2	3	4	5
I have trouble doing my job or practicing my profession.	1	2	3	4	5
I avoid going out socially.	1	2	3	4	5
I have to repeat myself to be understood.	1	2	3	4	5
I have become less outgoing.	1	2	3	4	5

The quiz was adapted from the “Voice-Related Quality of Life Measure”, developed at the Vocal Health Center of the University of Michigan Health System.

	Quiz Score	Your Voice-Related Quality of Life (V-RQOL) Score
1 = None, not a problem	10	100 (excellent)
2 = A small amount	20	75 (fair to good)
3 = A moderate (medium) amount	30	50 (poor to fair)
4 = Frequently	40	25 (poor)
5 = As bad as it can be	50	0 (worst possible)

Secondly, consider a vocal fitness program (i.e. voice therapy) which can make a big difference in quality of voice. Voice exercise may not seem as obvious as exercise in the gym, so guidance from a trained voice therapist is important.

Finally, should voice therapy alone prove unsatisfactory, vocal fold injection may be considered. The principle of this treatment is to restore the lost bulk of vocal fold muscle, and thereby improve the closure of the vocal folds stronger and less effortful. However, injection does not remedy all the changes occurred in the vibratory tissues of the larynx. So a “perfect” voice may not be produced by such a procedure. In addition, most vocal fold injectable materials are temporary; absorbed over a certain period of time. Individuals should speak to their Otolaryngologist regarding the advisability of the procedure.¹³

Conclusion:

In aged vocal folds, dense collagen deposition takes place and hyaluronic acid decreases in the lamina propria. Hirano, et al¹⁴ reported an in vitro study using animal model where fibroblasts were harvested from young and aged rat vocal folds and cultured with or without hepatocyte growth factor and /or basic fibroblast growth factor at different concentration. Subsequently, the production of hyaluronic acid and collagen type I was examined in the supernatant culture media using ELISA. They found that aged fibroblast produced less hyaluronic acid than younger fibroblasts. When aged & younger fibroblast were cultured with basic fibroblast growth factor, hyaluronic acid production increased and collagen type I production decreased regardless of the concentration, whereas the effects of hepatocytes growth factor was also associated with stimulation of growth of aged fibroblasts. They concluded that basic fibroblast growth factor, may have therapeutic potential in restoration of aged vocal fold.¹⁵

References:

1. Sunberg J. The science of the singing voice, De Kalb, Illinois, Northern Illinois University Press, 1987.
2. Linville, S.E. (2004, Oct. 19). The Aging Voice. The ASHA Leader, pp.12, 21
3. Liss JM, Weismer G, Rosenbek JC. Selected acoustic characteristics of speech production in very old males. J Gerontol 1990;45(2):35-45.
4. Ramig LA. Effects of physiologic aging on vowel spectral noise. J Gerontol 1983;38(2):223-5.
5. Ramig LA, Ringel RL. Effects of physiologic aging on selected acoustic characteristics of voice. J Speech Hearing Res 1983;26:22-30.
6. Ramig LO, Scherer RC, Klasner ER, Titze IR, Horii Y. Acoustic analysis of voice in amyotrophic lateral sclerosis: a longitudinal case study. J Speech Hear Disord 1990;55(1):2-14.
7. Woo P, Casper J, Colton R, Brewer D. Dysphonia in the aging: physiology versus disease. Laryngoscope 1992; 102(2):139-44.
8. Biever DM, Bless DM: Vibratory characteristics of the vocal folds in young adult and geriatric women. J Voice 1989;3:120-131.
9. Murty GE, Carding PN, Kelly PJ. Combined glottographic changes in the elderly. Clin Otolaryngol Allied Sci 1991; 16(6):532-4.
10. Honjo I, Isshiki N. Laryngoscopic and voice characteristic of aged persons. Arch Otolaryngol 1980;106(3):149-50.
11. Von Leden H, Alessi DM. The aging voice. In: Benninger MS, Jacobson BJ, Johnson AF, eds. Vocal Arts Medicine: The Care and Prevention of Professional Voice Disorders. New York: Thieme Medical Publishers, Inc. 1994; 269-280.
12. Official website of American Academy of otolaryngology – Head and Neck Surgery at <http://www.entnet.org/AboutUs/voiceHandicapIndex.cfm>.
13. Tucker HM. Laryngeal framework surgery in the management of the aged larynx. Ann Otol Rhinol Laryngol 1988;97(5 Pt 1): 534-6.
14. Hirano S, Bless DM, del Río AM, Connor NP, Ford CN. Therapeutic Potential of Growth Factors for Aging Voice. Laryngoscope 2004; 114(12): 2161-7.
15. Sato K, Hiara M, Nakashima T. Age related changes in vitamin a-storing stellate cells of human vocal folds. Ann Otol Rhinol Laryngol 2004; 113(2):108-112