

## Linear Psoriasis-A rare case report

Md Mahabubur Rahaman<sup>1</sup> Md Rahmat Ullah Siddique<sup>2</sup> Md Aminul Islam<sup>3</sup> Md. Moksedur Rahman<sup>4</sup> Md Zahed Parvez Barbhuiyan<sup>5</sup> Kaniz Rahman<sup>6</sup>

<sup>1</sup>Associate Professor, Department of dermatology & Venereology, Eastern Medical College, Comilla <sup>2</sup>Research Assistant Dept. of Dermatology & Venereology, BSMMU, Dhaka <sup>3</sup>Assistant Professor, Northern Medical College, Dhaka <sup>4</sup>Assistant Professor Cosmetic & Hair transplant surgeon Consultant, ShSMCH <sup>5</sup>Assistant Professor, Dept. of dermatology & Venereology, <sup>6</sup>Medical College, Dhaka.

### Abstract:

Linear psoriasis is a rare form of disease which is very difficult to differentiate from inflammatory linear verrucous epidermal nevus. Sometimes clinical history, physical examination and histopathology analysis may not be sufficient to confirm the diagnosis. We report a case of 25 year-old male presented with a linear plaque covered with silvery scales on left upper extremity extending from tip of the index to mid forearm for last 2 years. A skin biopsy was consistent with psoriasis, and the unilateral distribution in a linear pattern led to a diagnosis of linear psoriasis, which is a rare variant of psoriasis. Although histopathologically it can be difficult to distinguish from inflammatory linear verrucous epidermal nevus (ILVEN), linear psoriasis presents in adulthood and responds to conventional topical antipsoriatic therapies

**Key Words:** Blaschko lines, ILVEN, Psoriasis.

[BSMMU J 2015 ; 8 (1) : 74-76]

### Introduction:

Linear psoriasis is characterized by a linear distribution of psoriatic lesions along Blaschko's lines. True linear psoriasis in the absence of lesions elsewhere is extremely rare with few cases reported in the literature<sup>1</sup>. Happle proposed the pathogenesis of linear psoriasis as somatic recombination of a gene predisposing to psoriasis leading to segmental mosaicism. This hypothesis offers a reasonable explanation for linear psoriasis being a nonhereditary trait and the linear distribution similar to many other mosaic skin disorders<sup>2</sup>. Linear psoriasis may be confused with inflammatory linear verrucous epidermal nevus (ILVEN) or Koebner's response of psoriasis over verrucous epidermal nevus<sup>3</sup>. ILVEN tends to develop during the first month of life, progresses slowly, can be very pruritic and is usually unresponsive to treatment. However, linear psoriasis tends to develop later in life, progresses rapidly, only occasionally pruritic and responds well to antipsoriatic treatment<sup>4</sup>. Immunohistopathological studies may be helpful in further distinguish-

ing linear psoriasis and ILVEN.

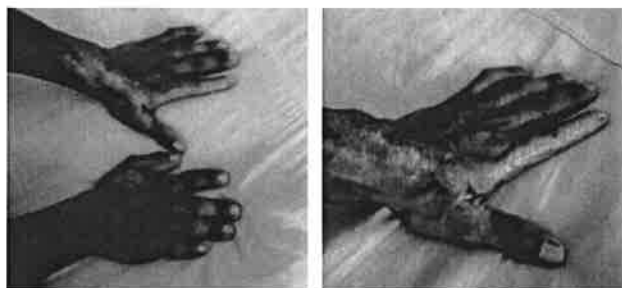
There is lower expression of keratin 10 in psoriasis as compared to normal levels in ILVEN. Involucrin expression is absent in ILVEN, but detectable in psoriasis<sup>4</sup>. Psoriasis overlying an epidermal nevus also has been described, but the lesions are extremely pruritic and most of the cases develop typical psoriatic lesions elsewhere in the body<sup>5</sup>. Our patient had onset of lesions late in life and did not develop lesions of psoriasis elsewhere in the body during the span of 10 years and the lesions progressed only in a linear distribution causing only mild pruritus. In addition, histopathology revealed features of psoriasis and the lesions responded well to treatment.

### Case Report:

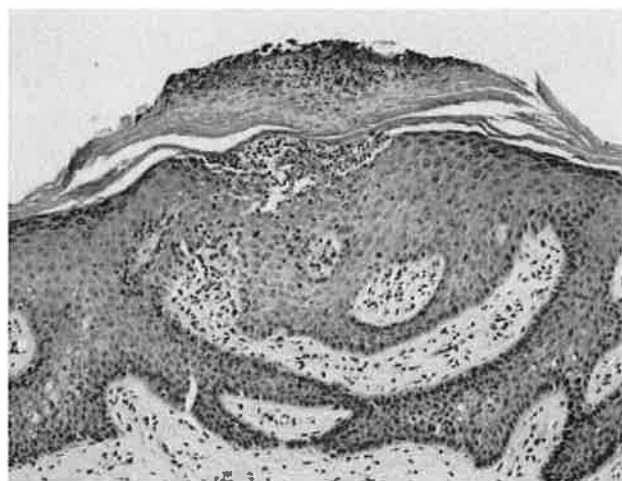
A 25-year-old male presented with 2 years history of a linear erythematous plaque on left upper extremity extending from tip of the index to mid forearm. The patient denied any episodes of infection preceding the dermatosis. No personal or family history of psoriasis. Physical examination revealed a linear erythematous plaque covered with silvery scales.

Address for Correspondence: : DR. Md Mahabubur Rahaman, DDV, FCPS (Dermatology & Venereology) Associate Professor, Department of dermatology & Venereology, Eastern Medical College, Comilla

Auspitz sign is positive. Nail pitting on both finger & toe nails are present. Musculoskeletal and neurological examination revealed no abnormalities. Other systemic examination appeared normal. The histopathologic analysis of a skin biopsy revealed orthokeratosis, parakeratosis and spongiform pustules- Munro's microabscesses, in association with a regular elongation of rete ridges, suprapapillary thinning, and an absence of granular cell layers.



**Fig-1.** Photograph of linear lesion on left upper extremity extending from tip of the index to mid forearm.



**Fig-2.** Histopathological findings of lesional biopsy revealed Munro's microabscess, parakeratosis, elongated rete ridges with absence of granular layer:

### Discussion:

Linear psoriasis is a rare form of psoriasis which was first described in 1951. The disease is characterized by psoriatic lesions distributed along Blaschko's lines. The main differential diagnosis is ILVEN, and the distinction between the two entities has been discussed in the literature<sup>6,7,8</sup> Saraswat et al<sup>9</sup> described the clinical differences between the two entities. A late onset of asymptomatic to slightly itchy lesions with a possible involvement of scalp

and nails and a favorable response to antipsoriatic treatment favors the diagnosis of linear psoriasis<sup>10,11</sup> In contrast, ILVEN lesions usually occur in the first months of life, are slowly progressive, very pruritic and highly refractory to antipsoriatic therapy. As for the histological features, ILVEN classically demonstrates hypergranulosis and parakeratosis alternating with hypogranulosis and orthokeratosis<sup>12</sup> On the other hand, the classic features of psoriasis are hyperkeratosis, parakeratosis, the absence of granular cell layers, an elongation of rete ridges, suprapapillary thinning and Munro's microabscesses, which can also be seen in ILVEN. Immunohistopathologic studies may be helpful in distinguishing the two conditions, as done by Vissers et al.<sup>6</sup> In ILVEN patients, the number of Ki-67-positive nuclei tended to be reduced, whereas the number of keratin-10-positive cells was increased compared with psoriasis patients. Involucrin expression, another marker, is absent in ILVEN patients but detectable in psoriasis<sup>13</sup>. The pathogenesis of linear psoriasis is not clear, but it could be explained by the well-established concept of genetic mosaicism<sup>14</sup>.

### References:

1. Chien P Jr, Rosenman K, Cheung W, Wang N, Sanchez M. Linear psoriasis. *Dermatol Online J* 2009;15:4.
2. Happle R. Somatic recombination may explain linear psoriasis. *J Med Genet* 1991;28:337.
3. Morag C, Metzker A. Inflammatory linear verrucous epidermal nevus: Report of seven new cases and review of the literature. *Pediatr Dermatol* 1985;3:15-8.
4. de Jong E, Rulo HF, van de Kerkhof PC. Inflammatory linear verrucous epidermal naevus (ILVEN) versus linear psoriasis: Clinical, histological and immunohistochemical study. *Acta Derm Venereol* 1991;71:343-6.
5. Bondi EE. Psoriasis overlying an epidermal nevus. *Arch Dermatol* 1979;115:624-5.
6. Vissers WH, et al. Immunohistochemical differentiation between inflammatory linear epidermal naevus (ILVEN) and psoriasis. *Eur J Dermatol*. 2004;14:216–220.
7. de Jong E, Rulo HF, van de Kerkhof PC. Inflammatory linear verrucous epidermal naevus (ILVEN) versus linear psoriasis. A clinical, histological and immunohistochemical study. *Acta Derm Venereol*. 1991;71:343–346.
8. Vissers WH, Muys L, Erp PE, de Jong EM, van de Kerkhof PC. Immunohistochemical differentiation between inflammatory linear verrucous epidermal nevus (ILVEN) and psoriasis. *Eur J Dermatol*. 2004;14:216–220.
9. Saraswat A, et al. Unilateral linear psoriasis with palmoplantar, nail, and scalp involvement. *Pediatr Dermatol*. 2004;21:70–73.

10. Ghorpade A. Linear naevoid psoriasis along lines of Blaschko. *J Eur Acad Dermatol Venerol.* 2004;18:726–727.
11. Lehnrs-Weber C, de la Brassine M, Dezfoulian B, et al. Congenital psoriasis following the lines of Blaschko. *Pediatr Dermatol.* 1996;13:219–221.
12. Miteva LG, Dourmishev AL, Schwartz RA. Inflammatory linear verrucous epidermal nevus. *Cutis.* 2001;68:327–330.
13. Ginarte M, Fernandez-Redondo V, Toribio J. Unilateral psoriasis: a case individualized by means of involucrin. *Cutis.* 2000;65:167–170.
14. Happle R. New aspects of cutaneous mosaicism. *J Dermatol.* 2002;29:681–692.