

Silver–Russell syndrome- A rare case report

¹ Shohela Akhter, ² Mohammad Imnul Islam, ³ Hafiz Al Mamun, ⁴ Shahana A Rahman

¹ Associate Professor, ² Assistant Professor, ³ Assistant Professor, ⁵ Professor of Paediatrics, Department of Paediatrics, Bangabandhu sheikh Mujib Medical University, Dhaka.

Abstract:

Silver–Russell syndrome is clinically and genetically a heterogeneous disorder. In most of the cases, etiology is unknown, only in 10% cases defect in chromosome 7 is identified. It has distinctive facial features and asymmetric limbs. Most predominant symptom is growth failure. A case of Silver–Russell syndrome reported here who presented with growth failure, hemihypertrophy of left side of the body, dysmorphic facial profile and difficulty in speech. Counseling was done with the parents regarding the etiology, progression and outcome of the disease.

Key words: Silver –Russell syndrome, short stature, congenital asymmetry.

[BSMMU J 2013 ; 6 (2) : 175-177]

Introduction:

Silver-Russell syndrome (SRS) is clinically and genetically a heterogeneous disorder of growth with a spectrum of additional dysmorphic features. SRS may comprise different disorders with clinically similar phenotypes or may result from disruption of different components of a single biochemical or endocrinological pathway.^{1,2} It is a syndromic disorder present at birth that involves poor growth, low birth weight, short stature, and differences in the size of the two sides of the body. In 1953, Silver et al reported two unrelated children with congenital hemihypertrophy, low birth weight, and short stature.³ In 1954, Russell described five unrelated children with extreme intrauterine growth retardation and characteristic facial features.⁴ A case of Silver-Russell syndrome is reported for proper understanding of the problem and to avoid wrong diagnosis and management.

Case Report :

A 8 years old boy, first issue of a non-consanguineous parents was admitted in the department of paediatrics,

Bangabandhu Sheikh Mujib Medical University with complaints of failure to gain weight and increased size of left half of the body since birth. Parents also complained of small penis and absence of left testis. He was delivered by LUCS at 36 weeks of gestation and birth weight was 1000 gm. His developmental milestones were delayed (neck control was achieved at 1 year, sitting at 2 years and walking at 3 yrs.) .Other family members had no history of such type of illness.

On examination the boy was well and alert, co-operative and vital signs were normal. He had hemihypertrophy of left side of the body. There was frontal bossing with triangular facies, depressed nasal bridge, low set ear (fig-1,2). Malocclusion of teeth (fig-3) and high arched palate were also present. He also had brachydactyli of fingers, toes of both hands and feet. Hypoplasia of 5th finger & little toe, syndactyli of 3rd and 4th toes (fig-4) were found in this boy. His vital signs were within normal limit. His height was 109 cm and height for age Z score was -3. His weight was 23.5kg and weight for age Z score was -0.7. He had small penis and absence of left testis (fig-2). Routine investigations including blood count and urine were normal. Fasting blood sugar was 3.1mmol/L. Ultra-sonogram of KUB was normal with absence of left

Address for Correspondence: Dr Shohela Akhter Associate Professor,
Department of Paediatrics, Bangabandhu sheikh Mujib Medical University, Dhaka.
Bangladesh. M-01720038503. E-mail: drzharna@gmail.com

testis (fig-2). Routine investigations including blood count and urine were normal. Fasting blood sugar was 3.1mmol/L. Ultra-sonogram of KUB was normal with absence of left testis. His IQ test was done which was below normal (50 in WISC scale). Xray wrist found delayed bone age (5 carpal bones). Slit lamp examinations of eyes were normal. Considering history, clinical examinations (hemihypertrophy, short stature and limb anomalies) and radiological evidences, this patient diagnosed as a case of Silver- Russell Syndrome. Counseling was done with the parents regarding the etiology, progression and outcome of the disease. The boy was given nutritional support, physiotherapy and discharged with the advice for regular follow-up.

Discussion :

Silver-Russell dwarfism, also called Silver-Russell syndrome (SRS) or Russell-Silver syndrome (RSS) is a growth disorder occurring in approximately 1/50,000 to 1/100,000 births.⁴ It is estimated that 7–10% of patients with this syndrome have a defect in a gene called the maternal uniparental disomy (UPD) for chromosome 7. Most cases occur in a person whose family has no history of the disease. Clinically apparent limb asymmetry occurs in about 60% of reported patients.⁵ Children born with Silver- Russell syndrome show different signs-symptoms since birth and phenotypic character varied from mild to classic. Although Silver et al originally described this feature as hemihypertrophy, it has been unclear whether the asymmetry is the result of hemihypertrophy, hemiatrophy, or a disturbance of the normal range of symmetry. The musculoskeletal manifestations of Russell-Silver syndrome were studied in 25 cases. The most common manifestations were short stature (25 cases), limb-length discrepancy (23 cases), clinodactyly (19 cases) metacarpal bone and phalangeal abnormalities (13 cases), scoliosis (9 cases), foot syndactylism (5 cases), and developmental dysplasia of the hips (3 cases).⁶

Diagnostic criteria recently proposed that Silver Russell syndrome (SRS) should have at least 4 criteria which included dysmorphic facies characterized by small triangular facies, a high forehead with small jaw, micrognathia and prominent nasal bridge. Growth and skeletal-asymmetry of the limbs manifested as hemihypertrophy, clinodactyly of the fifth finger, syndactyly of second and third toes were also important criteria of SRS. Birth

weight and poor postnatal growth less than or equal to -2 SD and feeding difficulties during infancy were also included in the criteria. SRS patients have developmental delay and impaired cognitive abilities. Genitourinary abnormalities like hypospadias, variation of sexual development, posterior urethral valve and delayed bone age were commonly found in this children.⁷

Our patients had birth weight less than -2SD, poor postnatal growth and developmental delay. The boy also had hemihypertrophy of the left side, dysmorphic facies, skeletal deformities and delayed bone age. Diagnosis of Silver Russell syndrome was done on the basis of clinical and radiological features. Genetic analysis of our patient couldn't be done due to lack of logistic support.

The management of Silver-Russell syndrome is conservative which includes nutritional support and physical therapy to alleviate the skeletal symptoms. In more severe cases, surgery is needed to lengthen limbs. Growth hormone therapy is often prescribed as part of the treatment of SRS.⁴ We have started physiotherapy for this patient and also took opinion regarding corrective surgery from orthopedic surgeons.

Conclusions:

Silver-Russell syndrome is a growth and skeletal disorder associated with significant morbidity. Early diagnosis and initiation of treatment is very much important to prevent joint deformities. Physicians should be cautious about correct diagnosis of this disease. Meticulous history, examination and radiological investigations can confirm the diagnosis.

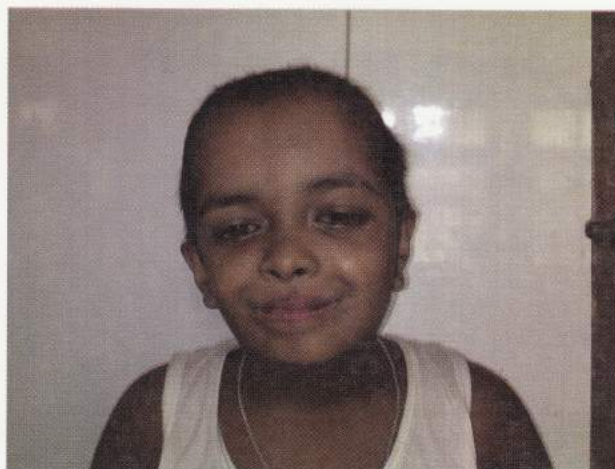

Fig-1 Facial profile .

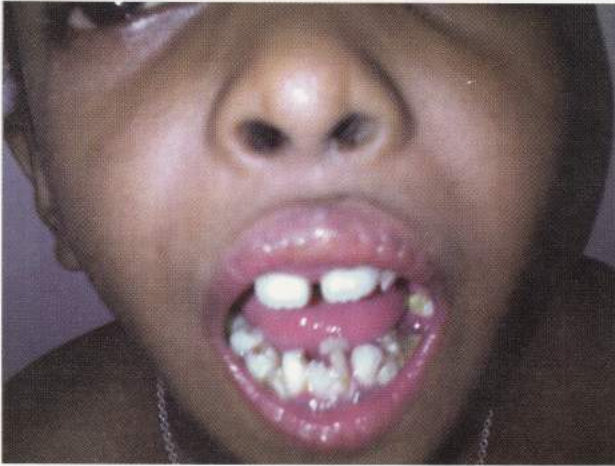


Fig 2: Malocclusion of teeth

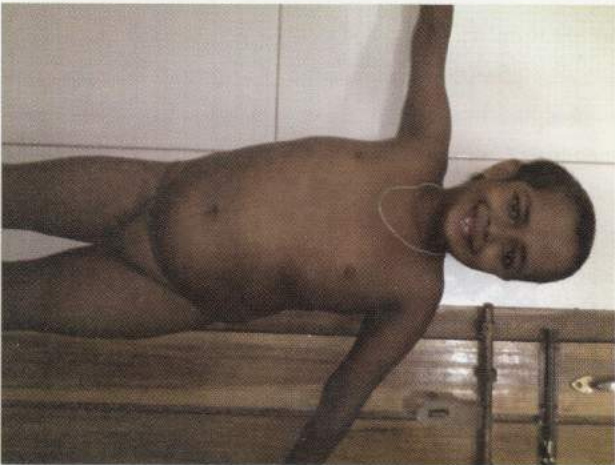


Fig 3: Hemihypertrophy of right side of the body.

References :

1. Hitchins MP, Stanier P, Preece, M A, Moore G E. Silver-Russell syndrome: a dissection of the genetic aetiology and candidate chromosomal regions. *Journal of Medical Genetics* 2001. Available from <http://www.accessmylibrary.com/article-1G1-81762589/silver-russell-syndrome-dissection.html>.
2. Sunil K, AP Jain, Sachin A ,Sindu C. Silver-Russell Syndrome: A case report. *Cases Journal* 2008, 1:304 . doi:10.1186/1757-1626-1-304
3. Patton M. Russell-Silver syndrome. *Journal of Medical Genetics* 1988, 25:557-560.
4. Silver-Russel Syndrome. Wikipedia [updated October 2011] Available from http://en.wikipedia.org/wiki/Silver%E2%80%93Russell_syndrome
5. Saal HM, Pagon RA, Pipin MG. Re-evaluation of Russell-Silver syndrome. *J Pediatr* 1985, 107:733-7.
6. Abraham E, Altiok H, Lubicky JP: Musculoskeletal manifestations of Russell-Silver syndrome. *J Pediatr Orthop* 2004, 24:552-64.
7. Ferry J R. Silver Russel Syndrome. *E Medicine. Pediatrics*, [updated June 2011] Available from <http://emedicine.medscape.com/article/948786-overview>.