

Squamous cell carcinoma developed on hypertrophic lichen planus-A case report

¹Md. Rahmat Ullah Siddique ²Md. Mahabubur Rahaman ³Md. Aminul Islam ⁴Md. Zulfiqar Hossain Khan ⁵Md. Moksedur Rahman ⁵Md. Zahed Parvez Barbhuiyan

¹ Research assistant, Dept. of Dermatology and Venereology, BSMMU ² Clinical & interventional dermatologist, Aurora Skin & Aesthetics, Dhanmondi, Dhaka ³ Assistant professor, Dept. of Dermatology and Venereology, Northern Medical college ⁴ Assistant professor ⁵ Consultant dermatologist ⁶ Dept. of Dermatology and venereology, DMCH.

Abstract:

Carcinoma occurring in the cutaneous lesions of Lichen Planus though rarely mentioned in literature does occur and should be kept in mind while treating such lesions. We report a 30 year female who developed a squamous cell carcinoma in a long standing hypertrophic lichen planus in the lower leg. This case is being presented to indicate the possibility of malignant transformation of cutaneous lichen planus to carcinoma, especially in the hypertrophic forms and the need to have an early diagnosis so that it can be treated in the initial stages. A high degree of suspicion should be present whenever we come across a non healing lesion in a patient with lichen planus. A few markers, which may give us a clue for increased chances of malignant transformation in these cases is presented.

Key words: hypertrophic lichen planus; squamous cell carcinoma

[BSMMU J 2014 ; 7 (1) : 58-60]

Introduction:

Lichen planus is a common papulo-squamous disorder affecting about 1-2% of the population. Lichen planus has several forms. It can affect the oral mucosa, skin, nails and genitalia. Cutaneous lichen planus may affect any area but it is often seen on the front of the wrists, lower legs, and ankles. Usually the lesions near the ankle are scaly and itchy and form the hypertrophic variant. New lesions occur when the old lesions are clearing. When the lesions cleared they are often replaced by greyish brown discoloration especially in dark skinned individuals. Usually these lesions heal with the conventional treatment.

Neoplastic transformation in lichen planus has been described, especially in the oral form of the disease where an estimated 0.3-3% of patients may develop squamous cell carcinoma. Malignancy though uncommon with cutaneous lichen planus has been described in chronic hypertrophic lesions of lichen planus on the legs ^{3,4,5}.

Case Report:

We described a 30 year-old female, who presented to our

Address for Correspondence: Md. Rahmat Ullah Siddique

Research assistant, Dept. of Dermatology and Venereology, BSMMU.

Department in february 2013 with a non healing ulcer over a large verrucous plaque on her right leg which is present for approximately eight months. She had been treated elsewhere but with no signs of healing. She had been diagnosed clinically and histopathologically as hypertrophic variant of lichen planus 8 years back.

On examination a large well defined raised pigmented verrucous plaque was found on right lower leg. There were areas of atrophy, hypertrophy and depigmentation on anterior aspect of right leg. (Fig.1). A biopsy of one of the depigmented plaques showed classic features of a lichen planus.(Fig.3)

The edges of the wound had plaques which suggested it had arisen from a lichen planus lesion (Fig. 2). This was being treated by regular dressings. Earlier topical betamethasone and salicylic acid had been tried with only partial response. Both the legs had post inflammatory changes at sites of earlier lesions. There was no popliteal or inguinal lymphadenopathy. The histological findings of the ulcer biopsy showed (Fig.4) multiple cellular atypia with keratin horn pearls confirming the to a diagnosis of squamous cell carcinoma.

(the ulcer showed(Fig.4) multiple cellular atypia with keratin horn pearls done under local anesthesia on 28.01.2013, referred to a diagnosis of squamous cell carcinoma.)

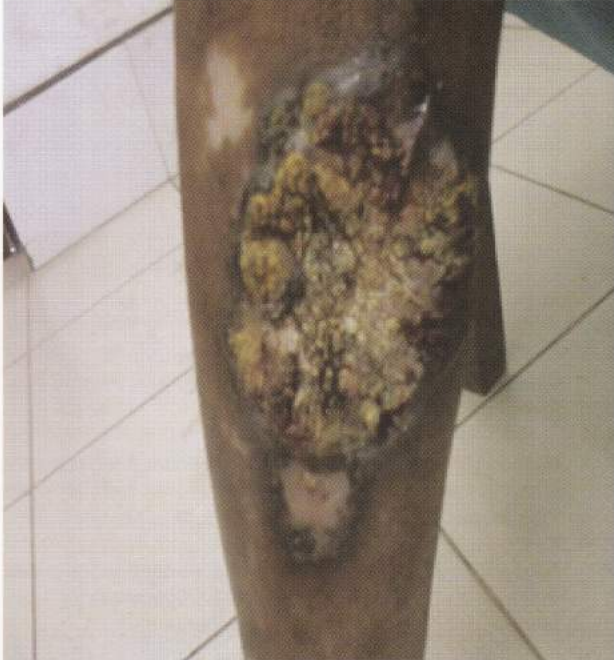

Fig-1: A large well defined verrucous plaque with adjacent lichen planus plaque

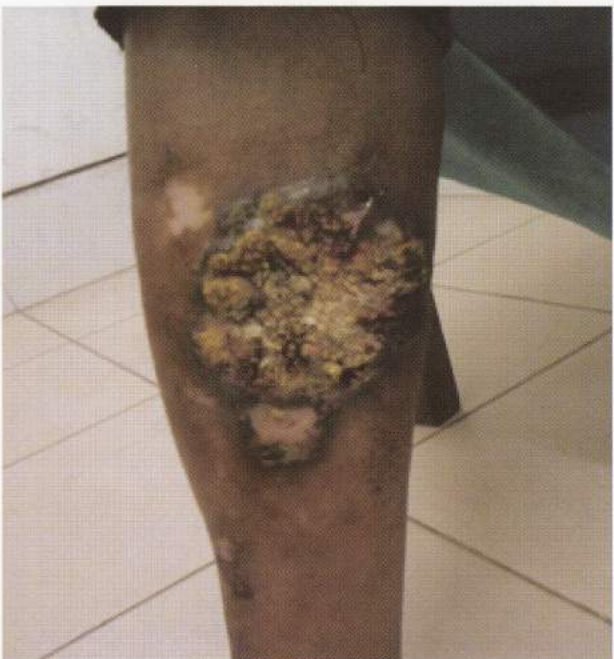

Fig-2: Multiple depigmented hypertrophic plaques surrounding a large plaque

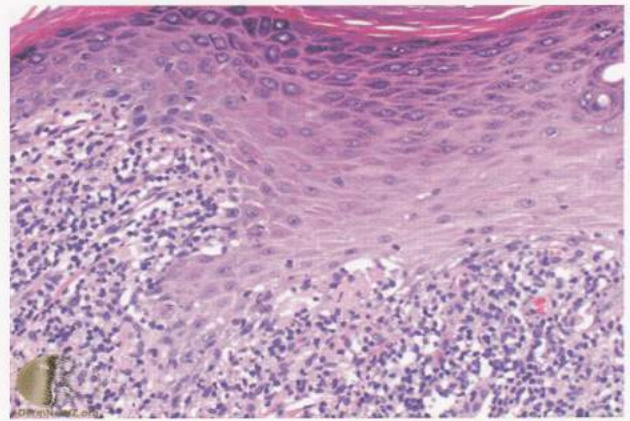


Fig-3: Histopathological findings of depigmented plaque shows features of lichen planus

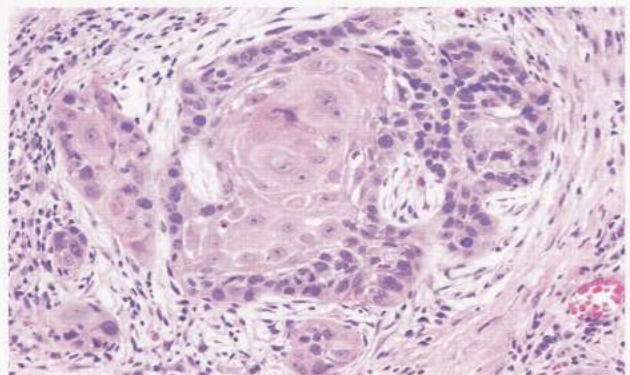


Fig-4: Histopathology of verrucous lesion shows multiple cellular atypia with keratin horn pearl, features of squamous cell carcinoma

Discussion:

Most squamous cell carcinoma (scc) is induced by ultraviolet light, while carcinogenic chemicals and human papilloma viruses are also implicated. While an increased risk of the development of carcinoma in oral LP is generally accepted, it is still unclear if there exists a true association between cutaneous lichen planus and Squamous cell carcinoma.

Squamous cell carcinoma complicating cutaneous Lichen Planus (LP) has an incidence of 0.4% and most of the reported cases are hypertrophic type⁴. It is essential that one identifies lesions which are likely to transform into carcinoma and a diagnosis is made early. One such marker could be the presence of areas of depigmentation in the lesions. Such lesions have increased the probability to turn into malignant⁵. Depigmentation was present on our case too.

Another common feature of all cases reported so far in literature is the presence of the lesions in the legs (specially the ankles). Hence such cases must be viewed with increased suspicion⁶⁻⁹.

Neoplastic transformation (development of squamous cell carcinoma / verrucous carcinoma) in lichen planus has been described, especially in the oral form of the disease where an estimated 0.3-3% of patients may develop squamous cell carcinoma¹. Malignancy though uncommon with cutaneous lichen planus has been described in chronic hypertrophic lesions of lichen planus on the leg^{6,8,9} including a case of metastatic squamous cell carcinoma developing in a 34-year old male in chronic hypertrophic lesions of lichen planus on the legs of more than 10 years duration¹⁰.

Conclusion:

Hypertrophic lichen planus on the legs tend to persist and has a propensity for malignant transformation even in young patients. Therefore non healing ulcers overlying such lesions should be viewed with great suspicion and biopsy to be performed to rule out squamous cell carcinoma.

References :

1. Castaño E, López-Ríos F, Alvarez-Fernández JG, Rodríguez-

- Peralto JL, Iglesias L Verrucous carcinoma in association with hypertrophic lichen planus. *Clin Exp Dermatol* 1997; 22:23-5.
2. Hodzic-Avdagic N, Kuhn A, Megahed M, Neumann NJ. Verrucous squamous cell carcinoma developing in hypertrophic lichen planus. *Hautarzt*, 2004; 55:385-7.
 3. Singh SK, Saikia UN, Ajith C, Kumar B: Squamous cell carcinoma arising from hypertrophic lichen planus. *J Eur Acad Dermatol Venereol*, 2006; 20:745-6.
 4. Sigurgeirsson B, Lindelöf FB, Lichen planus and malignancy: An epidemiologic study of 2071 patients and a review of the literature. *Arch Dermatol*, 1991; 127:1684-6.
 5. Jayaraman M, Janaki VR, Yesudian P. Squamous cell carcinoma arising from hypertrophic lichen planus. *Int J Dermatol*, 1995; 34:70-1.
 6. Gawkrödger DJ, Stephenson TJ. Squamous cell carcinoma complicating lichen planus a clinico-pathological study of three cases. *Dermatology*, 1994; 188:36-9.
 7. Kaulich M, Jurecka W, Steiner A. Development of squamous epithelial carcinoma on the lower leg in long term verrucous lichen planus. *Wien Klin Wochenscr*, 2003; 115:267-70.
 8. Potter B, Fretzin D. Well differentiated epidermoid carcinoma arising in hypertrophic lichen planus. *Arch dermatology*, 1996; 94:805-6.
 9. Manz B, Paasch U, Stierherling M. Squamous cell carcinoma as a complication of long standing hypertrophic lichen planus. *Int J Dermatology*, 2005;44:773-4.
 10. Ardabili M, Gambicher T, Rotterdam S, Altmeyer P, Hoffmann K, Stucker M. Metastatic cutaneous squamous cell carcinoma arising from chronic hypertrophic lichen planus. *Dermatol Online J* 2003;9:10.