

## Case Series of Stargardt's Disease-our Experience

Syed Abdul Wadud<sup>1</sup>, Muntasir Bin Shahid<sup>2</sup>, Sumon Afroz<sup>2</sup>

<sup>1</sup> Associate professor Department of community ophthalmology, BSMMU, <sup>2</sup>Resident Department of Community Ophthalmology, BSMMU.

### Abstract:

Stargardt disease is the most common form of juvenile macular degeneration. Clinically, it is characterized by pisciform flecks at the level of the retinal pigment epithelium and a bull's-eye maculopathy. Inheritance is usually autosomal recessive, although dominantly inherited case have been described. Both sexes are affected equally. We reported here three cases of Stargardt's macular dystrophy, who are siblings and daughters of non consanguineous parents. In case-1,2 and 3 we found the typical presentation with almost same findings.

**Key words:** Stargardt's central visual field loss, Optical coherence tomography ( OCT ).

[BSMMU J 2014 ; 7 (2) : 147-150]

### Introduction :

Stargardt disease is the most common type of hereditary recessive macular dystrophy. The estimated incidence for the disease is 1 in 10,000 live births, and it characteristically presents in juveniles and young adults<sup>1</sup>. Patients begin to experience a bilateral, gradual decline in their vision between the ages of 6 and 20 years, and can present with visual acuity ranging from 6/18 to 6/60. Their prior visual acuity is often normal, though their final acuity is often 20/200 or worse<sup>2</sup>. It was named for the German ophthalmologist Karl Stargardt, and may also be called fundus flavimaculatus. This condition affects retinal pigment epithelium (RPE). In people with Stargardt disease the RPE collects lipofuscin, which can lead to vision problems. Vision loss in Stargardt disease is most intense in the macula. Stargardt disease is part of a group of diseases affecting the macular region of the retina, called macular degenerations. Stargardt disease is sometimes called a juvenile macular degeneration because it often appears at an early age<sup>3</sup>.

“For most families with Stargardt disease, the inheritance

pattern is autosomal recessive. Recently a small number of families were found to have an autosomal dominant pattern of inheritance. This form is called a “Stargardt like” disease, and looks similar to the autosomal recessive form. These two forms are actually different diseases with different mechanisms. An accurate family tree or gene testing can help distinguish one from the other. Autosomal recessive Stargardt disease is caused by mutations in a gene called *ABCA4*. A second gene called *ELOVL4* has been found to be the cause of the autosomal dominant form of Stargardt-like disease. Severity of disease may be related to how severely a gene change affects gene function. Sometimes, a gene is also influenced by other genes or the environment. These factors help explain why variation exists within the same family. Patients with questions about their personal form of Stargardt disease should be guided by experienced health professionals, such as an ophthalmologist or genetic counselor, who know about genetics and Stargardt disease.

The classical Stargardt phenotype is characterized by a juvenile –onset foveal atrophy surrounded by discrete, yellowish, round or pisciform flecks at the level of the

---

Address for Correspondence: Syed Abdul Wadud, Associate professor Department of community ophthalmology, BSMMU.



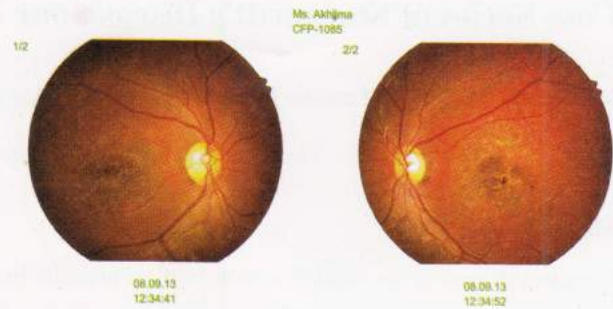
**Case – 1**

A 23-yrs old healthy young lady, presented at ophthalmology of Bangabandhu Sheikh Mujib Medical University (BSMMU) with the complaints of gradual dimness of vision of both eyes since her 6 years of age. There was no history of night blindness, loss of color vision, trauma or surgery to the eye. The patient consulted with local ophthalmologist at that time and was prescribed some eye drops, vitamins and refractive correction but her vision was not improved. On examination her (Best corrected visual acuity) BCVA 6/60 B/E. Anterior segment it was within normal limit B/E, pupillary light reaction brisk B/E.


On fundoscopic examination : Pigments were seen at the foveal zone with flecks all around (Fig -1a). Disc was normal. Vascular pattern was normal in both eyes (Fig -1b). Non - specific mottling at the fovea. Oval macular lesion about 1.5 disc diameter in size of Beaten -bronze appearance. Macular lesion was surrounded by yellow white flecks. Atrophic changes in the RPE and secondary changes in the photoreceptors. Retinathickness of was decreased. notably in the fovea. Photo receptors were lost External nuclear layer was changed. Abnormalities in the retinal pigment epithelium were seen (Fig - 1b). Average thickness was 163.2 um and central thickness was 56 um

**Case – 2**

A 12 years old girl presented to OPD of BSMMU with the complaint of gradual dimness of vision of her both eyes since her 6-yrs of age. She had no history of ocular pain, trauma, photophobia or seeing haloes around light. She consulted with a local ophthalmologist at that time and was prescribed some eye drops, vitamins and refractive correction but her vision was not improved satisfactorily. On examination her BCVA 6/18 both eyes, anterior segment-within normal limit. Pupillary light reaction was brisk in both eyes. On fundoscopic examination-Disc was normal, foveal reflex was dull. Pigmentary changes seen



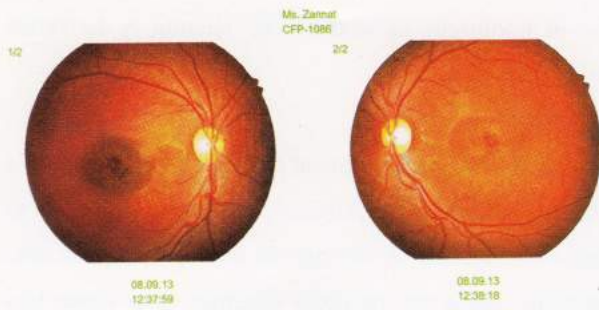**Fig -1a:** [Non - specific mottling at the fovea. Oval macular lesion about 1.5 disc diameter in size. Beaten -bronze appearance. Macular lesion surrounded by yellow white



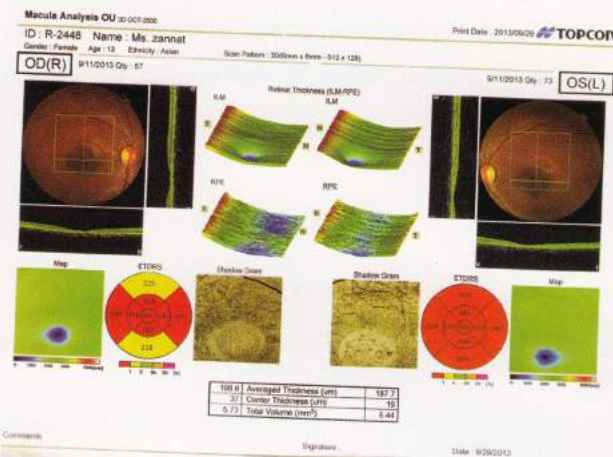
**Fig-1b:** [Decrease thickness of retina. Notably in the fovea. Loss of photo receptors. External nuclear layer changes. Abnormalities in the retinal pigment epithelium. Average thickness 163.2 um and central thickness is 56 um.]

Non specific mottling was seen at the fovea. Oval macular lesion about 1.5 disc diameter in size like Bull's eye maculopathy was observed. Macular lesion surrounded by yellow white flecks. Atrophic changes in and RPE and secondary changes in the photoreceptors and decreased thickness of retina. notably in the fovea and lost of photo receptors and external nuclear layer changes were Seen. Abnormalities in the retinal pigment epithelium (Fig - 2b). with average thickness 187.7 um & central thickness





**Fig-2(a):** [Non – specific mottling at the fovea. Oval macular lesion about 1.5 disc diameter in size. Bull’s eye maculopathy. Macular lesion surrounded by yellow white flecks.]

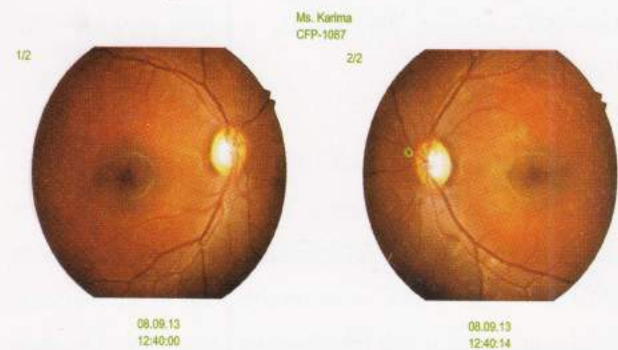


**Fig-2(b) :** [Decrease thickness of retina. Notably in the fovea. Loss of photo receptors. External nuclear layer changes. Abnormalities in the retinal pigment epithelium. Average thickness 187.7 um. Central thickness 19 um.]

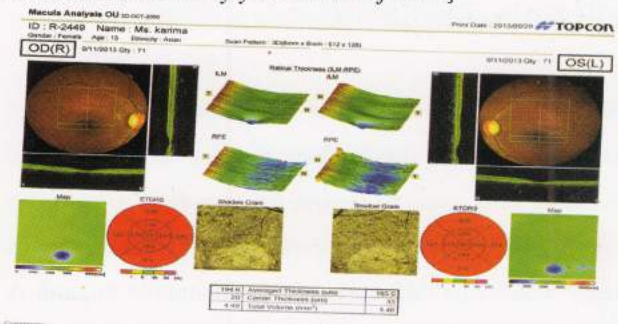
**Case – 3 :**

A 10-yr old girl presented to Eye OPD at BSMMU with the complaint of progressive dimness of vision of her both eyes since her 5-yr old. there is no history of night blindness or loss of colour vision. She had no history of ocular pain, trauma, Photophobia or haloes around light were seen. She consulted a local ophthalmologist and was

prescribed some eye drops, vitamins and given refractive correction but her vision was not improved. On examination her BCVA 6/24 both eyes, anterior segment within normal limit, papillary light reaction-brisk both eye. On fundoscopic examination. Disc : normal, foveal reflex : dull, pigmentary changes seen at foveal zone, flecks are seen all around macula in B/E (Fig :3a). Non specific mottling at the fovea. Oval macular lesion about 1.5 disc diameter in size, which is Snail – slime appearance with Bull’s eye maculopathy. Macular lesion was surrounded by yellow white flecks. Atrophic changes in the RPE and secondary changes in the photoreceptors was seen. Decrease thickness of retina, notably in the fovea and of photo receptors and external nuclear layer changes were seen. Abnormalities in the retinal pigment epithelium (Fig – 2b). Average thickness was 193.9 um. Central thickness was 33 um.



**Fig-3(a) :** [Non – specific mottling at the fovea. Oval macular lesion about 1.5 disc diameter in size. Snail – slime appearance with Bull’s eye maculopathy. Macular lesion surrounded by yellow white flecks.]



**Fig-3(b) :** [Decrease thickness of retina. Notably in the fovea. Loss of photo receptors. External nuclear layer changes. Abnormalities in the retinal pigment epithelium. Average thickness 193.9 um. Central thickness 33 um.]



## Discussion :

Our reported three cases of juvenile onset Stargardt macular dystrophy, who are siblings and daughters of non consanguineous parents. In case-1,2 and 3 we found the typical presentation with almost same findings. Non specific mottling was seen at the fovea. Oval macular lesion about 1.5 disc diameter in size giving the appearance at Bull's eye maculopathy. Macular lesion surrounded by yellow white flecks. Atrophic changes in the RPE and secondary changes in the photoreceptors. Case 1 have best corrected visual acuity 6/60, case 2, 6/18 and case 3 have 6/24 in both eyes respectively. Patients with Stargardt's disease and diffuse fundus flecks, the majority of patients did not lose VA to a greater extent than those with localized flecks. Patients who present with midperipheral fundus flecks, stage 2 or stage 2-3 Stargardt's disease, demonstrate a worse prognosis for Vision<sup>5</sup>.

The known molecular basis of the retinal dystrophies is the mutations in the human retinal degeneration slow (RDS) gene and the ATP-binding cassette transporter (ABCA4) gene. There are several reports in the literature about intrafamilial and interfamilial phenotypic variation among patients with retinal dystrophy caused by mutations of these genes. similar families displaying different combinations of patients: Stargardt's disease, CRD and RP as result of different mutations in the ABCA4 gene<sup>6</sup>.

At present there is no cure for Stargardt disease and there is very little that can be done to slow its progression. Wearing sunglasses to protect the eyes from UVa, UVb and bright light may be of some benefit. Animal studies have shown that taking excessive amounts of vitamin A

and beta carotene could promote the additional accumulation of lipofuscin, as well a toxic vitamin A derivative called A2E<sup>4,6</sup>.

A clinical study of a treatment that involves delivery of a healthy version of the ABCA4 gene into retinal cells to restore production of the normal protein. They are also optimistic about several drugs that may slow vision loss by reducing the buildup of lipofuscin. Because there is some evidence that sunlight may influence lipofuscin accumulation in the retina, u-v blocking sunglasses are generally recommended for outdoors. For people who already have significant vision loss, low vision aides are available<sup>4,5</sup>. We counsel our patient with all these treatment options. So future research is indeed like gene therapy or any options with proper rehabilitation measures to improve familial, social as well country economical growth.

## Bibliography:

1. Anderson KL, Baird L, Lewis RA, et al. A YAC Contig Encompassing the Recessive Stargardt Disease
2. Gene (STGD) on Chromosome 1p. Am J Hum Genet 1995;57:1351-63. [PubMed: 8533764]
3. American Academy Of Ophthalmology, Retina and vitreous 2012-2013;11:234-236.
4. <http://www.kellogg.umich.edu/patientcare/downloads/Understand-Stargardt.pdf>
5. Kim LS, Fishman GA. Comparison of visual acuity loss in patients with different stages of Stargardt's disease. Ophthalmology. 2006;113(10):1748-51.
6. Ozdek S, Onaran Z, Gürelik G, Bilgihan K, Acar C, Hasanreisoglu B. Stargardt's disease and retinitis pigmentosa: different phenotypic presentations in the same family. Eye (Lond). 2005;19(11):1222-5.
7. Westerfeld C, Mukai S. Stargardt's Disease and the ABCR Gene. Seminars in Ophthalmology 2008;23:59-65. [PubMed: 18214793]