

Mitral valve replacement in a 12 year old boy with Marfan syndrome and severe mitral regurgitation

Md. Alauddin, Kamrun Nahar, Golam Mokthader Khan, Karan Rai, Mostafizur Rahman and Rezwanul Hoque

Article Info

Department of Cardiac Surgery, Faculty of Surgery, Bangabandhu Sheikh Mujib Medical University, Shahbag, Dhaka, Bangladesh

For Correspondence:

Rezwanul Hoque
drrhbulbul@yahoo.com

Received: 27 January 2017
Accepted: 14 February 2017
Available Online: 24 February 2017

ISSN: 2224-7750 (Online)
2074-2908 (Print)

DOI: 10.3329/bsmmuj.v10i1.31232

Cite this article:

Alauddin M, Nahar K, Khan GM, Rai K, Rahman M, Hoque R. Mitral valve replacement in a 12 year old boy with Marfan syndrome and severe mitral regurgitation. *Bangabandhu Sheikh Mujib Med Univ J.* 2017; 10: 38-40.

Copyright on this research article is retained by the author(s)
[Attribution CC-BY 4.0]

Available at:

www.banglajol.info

A Journal of Bangabandhu Sheikh Mujib Medical University, Dhaka, Bangladesh

Abstract

A 12 year old boy with Marfan syndrome associated with severe mitral regurgitation underwent successful mitral valve replacement. Careful evaluation of the cardiovascular system and specific surgical intervention help long-term survival of patients.

Introduction

The cardiac, ocular and skeletal system of our body are commonly affect in Marfan syndrome of which cardiac manifestation is the most serious that reduces the life expectancy. It usually involves the aorta¹ and manifests as the dilatation of aortic root with or without aortic valve, aortic dissection, aortic aneurysm or aortic rupture, thus endanger the life.² Isolated mitral valve involvement is rare.³ It may or may not have positive family history.⁴ In mitral valve involvement, the leaflets may be prolapsed or thicken that cause regurgitation of blood to the left atrium,⁵ mitral regurgitation and associated with symptoms. It may also cause left ventricular hypertrophy and left atrial dilatation.^{5,6} Mostly it occurs in childhood.⁷ Early evaluation of valve morphology and effective surgical intervention can exhibits the long-term expectancy of life.

The skeleton as well as the ocular manifestation are also helpful for diagnosis of Marfan syndrome patient. Skeletal disorders are the most common and earliest to detect.⁸ They are progressive with age and are completed in adolescence. The skeletal feature typically encompasses with abnormally long finger, limbs are relative long to trunk length, the sternum either elevated or depressed, thoracolumbar scoliosis.² On examination of the eye, the mention findings myopia, cataract, retinal detachment and superior dislocation of the lens are also suggestive of Marfan syndrome.¹⁰

As an autosomal dominant condition Marfan syndrome affects multisystem of our body as a consequence of point mutation of FBN1 gene which is encoding for fibrillin-1 and is located on chromosome 15q21⁸ with a prevalence

of approximately 1 per 5,000 population⁴ and 26% of the cases have no family history.^{5,6} There is no geographic, ethnic or gender predilection.⁹

Case Report

A 12 year old boy presented with shortness of breath on exertion, palpitation and undue fatigue for 1 year. Symptoms were gradual in onset then progressive. At presentation, he was found dyspnoeic. He had progressive loss of vision since childhood and diminishing vision was also compromising his quality of life. He was the tallest member of his family. His grandfather also had similar phenotypic characteristics and died of heart disease at 55 years of age.

Physical examination revealed him to be a tall thin person with abnormally thin and long face with disproportionately long limbs compared to the trunk with long tapering fingers and hammer toes. His height was 178 cm (upper half of body 77 cm and lower half 101 cm) and a reduced upper to lower segment ratio (0.76). His arm span was more than height (178 cm) and arm span to height ratio was 1. Chest deformity was present in the form of pectus excavatum with decreased thorax expansion. Wrist (walker's) sign (Figure 1) and Thumb sign (Figure 2) was positive. He also had high arched palate and pes planus. Ocular examination revealed inferotemporal dislocation of both lens.

The patient was tachypnoeic with respiratory rate of 26/min. Pulse was 90/min in radial artery and blood pressure was 100/60 mm of Hg. On cardiovascular examination, apex beat was visible, palpable and displaced outside the



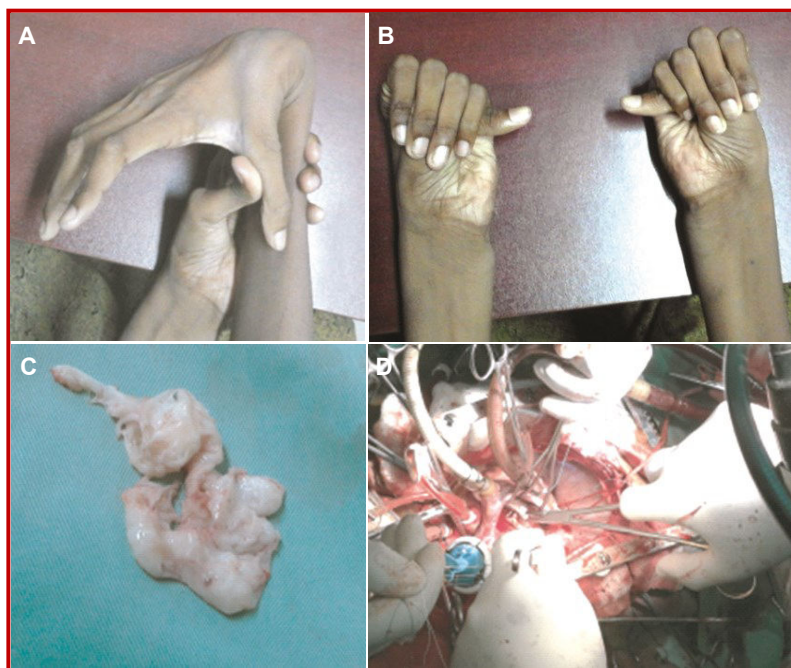


Figure 1: Wrist sign (A), thumb sign (B), excised floppy mitral valve (C), and mechanical valve during procedure (D)

left midclavicular line. 1st heart sound was soft. 2nd heart sound was normal. Pansystolic murmur was best heard over the mitral area with radiation towards the left axilla. Auscultatory findings were suggestive of mitral regurgitation.

Chest X-ray showed cardiomegaly. ECG reveals biventricular hypertrophy. Echocardiography showed severe mitral regurgitation grade 4, thickened AML and PML with prolapsed AML, dilatation of all cardiac chambers, hugely dilated left atrium and left ventricle, mild tricuspid regurgitation with mild pulmonary hypertension, mild pulmonary regurgitation and EF 55%. Histopathology showed thickened fibrous tissue with areas of myxomatous degeneration.

The phenotypic characteristics, clinical findings and investigation report were consistent with Marfan syndrome with mitral regurgitation.

Per-operative showed floppy mitral valve (Figure 3) and he underwent mitral valve replacement with 31 mm Saint Judes mechanical bileaflet valve under cardiopulmonary bypass, cross clamp time was 60 min and extracorporeal circulation time was 90 min. He was discharged with satisfactory hemodynamic condition on 12th postoperative day and subsequent follow-up at one month and three months revealed satisfactory hemodynamic and cardiac performance.

Discussion

This patient with Marfan syndrome have tall and

thin body condition, he also present long extremities that are disproportionate to the trunk. The fingers and toes of this patient are characteristically long of which the fingers can be wrapped completely around the opposite wrist and frequently overlapping (positive Walker's sign) and when the thumb enclosed within the clenched fist it protrudes beyond the ulnar border (positive Steinberg sign)¹¹ this phenotypic feature was suggestive for diagnosis of the patient.

Cardiovascular involvement determine the prognosis of Marfan syndrome, since they cause the highest mortality near about 70-95% of cases.¹² Progressive shortness of breath on exertion and palpitation were cardiac manifestations of this patient. It was due to mitral valve prolapsed. It's incidence depends on the age 40-80% in children.

In a study it has been estimated that only 0.25% of patients with mitral valve prolapsed have Marfan syndrome.¹³ The most common complication is mitral valve prolapsed that result in severe regurgitation as well as left atrial and ventricular dilatation due to progressive degeneration of the valve and chordae, with myxomatous infiltration. Bacterial endocarditis and sudden death may also occur due to severe mitral regurgitation or mitral valve prolapsed. Primary mitral valve surgery is currently performed most frequently to specifically treat mitral valve prolapsed. Surgical treatment for the floppy mitral valve abnormalities comprises repair or replacement of the valve.

Ocular involvement is common (70%) and progressive.¹⁴ On eye examination, this patient present unable to see the distal objects with occasionally double vision which is more specific due to inferotemporal subluxation of lens and the refractive errors was corrected accordingly to preserve the maximum visual function.

Conclusion

Early evaluation of the cardiovascular system, regular valvular monitoring, initiation of medical therapy as well as mitral valve replacement can improve and extend the lives of many patients of Marfan syndrome with mitral regurgitation.

References

1. Dean JCS. Marfan syndrome: Clinical diagnosis and management. *Eur J Med Genet.* 2007; 15: 724-33.
2. Krause KJ. Marfan syndrome: Literature review of mortality studies. *J Insur Med.* 2000; 32: 79-88.
3. Lacro RV, Dietz HC, Wruck LM, Bradley TJ, Colan SD, Devereux RB, Klein GL, Li JS, Minich LL, Paridon SM, Pearson GD, Printz BF, Pyeritz

- RE, Radojewski E, Roman MJ, Saul JP, Stylianou MP, Mahony L, Pediatric Heart Network Investigators. Rationale and design of a randomized clinical trial of beta-blocker therapy (atenolol) versus angiotensin II receptor blocker therapy (losartan) in individuals with Marfan syndrome. *Am Heart J*. 2007; 154: 624-31.
4. Dean JC. Management of Marfan syndrome. *Heart* 2002; 88: 97-103.
 5. Colod-Beroud G, Boileau C. Marfan syndrome in the third millennium. *Eur J Hum Genet*. 2002; 10: 673-81.
 6. Devereux RB. Diagnosis and classification of severity of mitral valve prolapsed: Methodologic, biologic and prognostic considerations. *Am Heart J*. 1987; 113: 1265-80.
 7. Robins PR, Moe JH, Winter EB. Scoliosis in Marfan's syndrome: Its characteristics and result of treatment in thirty-five patients. *J Bone Joint Surg Am*. 1975; 57: 358-68.
 8. Dietz H, Cutting G, Pyeritz RE, Maslen CL, Sakai LY, Corson GM, Puffenberger EG, Hamosh A, Nanthakumar EJ, Curristin SM, et al. Marfan syndrome caused by a recurrent *de novo* missense mutation in the fibrillin gene. *Nature* 1991; 352: 337-39.
 9. Yuan SM, Jing H. Marfan's syndrome: An overview. *Sao Paulo Med J*. 2010; 128: 360-66.
 10. Johnson WMS, Johnson P. Marfan syndrome: A case report. *Anatomica Karnataka*. 2012; 6: 35-39.
 11. Pearson GD, Devereux R, Loeys B, Maslen C, Milewicz D, Pyeritz R, Ramirez F, Rifkin D, Sakai L, Svensson L, Wessels A, Van Eyk J, Dietz HC, National Heart, Lung, and Blood Institute and National Marfan Foundation Working Group. Report of the National Heart, Lung, and Blood Institute and National Marfan Foundation Working Group on research in Marfan syndrome and related disorders. *Circulation* 2008; 118: 785-91.
 12. Freed LA. Prevalence and clinical outcome of mitral valve prolapsed. *N Engl J Med*. 1999; 341: 1-7.
 13. Wicken DE, Hickey AJ. Lifetime risk for patients with mitral valve prolapsed of developing severe valve regurgitation requiring surgery. *Circulation* 1988; 78: 10-14.
 14. Levy D, Savage D. Prevalence and clinical features of mitral valve prolapsed. *Am Heart J*. 1987; 113: 1281-90.
-