

# Excision of choledochal cyst in children by Roux-en-Y hepaticojejunostomy

A. K. M. Zahid Hossain, Gazi Zahirul Hasan, Susankar Kumar Mandal, Dinesh Prasad Koirala, Sanjay Kumar Sah and Razib Ahmed Chowdhury

## Article Info

Department of Pediatric Surgery, Faculty of Surgery, Bangabandhu Sheikh Mujib Medical University, Shahbag, Dhaka, Bangladesh

### For Correspondence:

A. K. M. Zahid Hossain  
drzahidps@gmail.com

Received: 22 January 2017  
Accepted: 18 February 2017  
Available Online: 23 February 2017

ISSN: 2224-7750 (Online)  
2074-2908 (Print)

DOI: 10.3329/bsmmuj.v10i1.31312

### Cite this article:

Hossain AKMZ, Hasan GZ, Mandal SK, Koirala DP, Sah SK, Chowdhury RA. Roux-en-Y hepaticojejunostomy after excision of choledochal cyst in children. *Bangabandhu Sheikh Mujib Med Univ J.* 2017; 10: 16-20.

Copyright on this research article is retained by the author(s)  
[Attribution CC-BY 4.0]

### Available at:

www.banglajol.info

A Journal of Bangabandhu Sheikh Mujib Medical University, Dhaka, Bangladesh

## Abstract

The aim of this study was to review our experience of total excision with Roux-en-Y hepaticojejunostomy for the surgical management of type I and type IVa choledochal cysts in 30 children. Among them, 22 were in type I and 8 in type IVa choledochal cysts. All had complete excision and Roux-en-Y hepaticojejunostomy with no mortality. Morbidity consisted of prolonged drainage (n=2) and late onset cholangitis/pancreatitis (n=4). Choledochal cyst generally has an excellent prognosis with early complete excision and Roux-en-Y hepaticojejunostomy.

## Introduction

Choledochal cyst is a congenital dilatation of the biliary tree, which is closely associated with an anomalous arrangement of the pancreaticobiliary duct. The incidence of cysts was reported to be approximately 1:100,000–150,000 live births but it is more common in Asian countries.<sup>1</sup>

Most of the cysts (85%) are reported to be diagnosed in the first decade or less than 15 years of age and approximately 20% of cysts are diagnosed in older patients.<sup>2,3</sup>

Clinical presentation of choledochal cysts varies and depends largely on the age of the child at presentation. The most common complaint includes recurrent abdominal pain, jaundice or cholangitis. Abdominal mass is rarely found in children. The potential morbidity of this condition is due to the risk of biliary tract malignancy. The incidence of the gall bladder or bile duct cancer increases with age. In patients with choledochal cysts under the age of 10 years, the risk of developing biliary tract cancer is 0.7% and the risk increases to 14.3% for patients over 20 years of age in the Western countries.<sup>4</sup> A prompt and accurate diagnosis of choledochal cyst, followed by surgical management is, therefore, essential.

The traditional open procedure for the management of type I and type IVa choledochal cysts is the complete excision of the extrahepatic cyst with biliary-enteric reconstruction through Roux-en-Y hepaticojejunostomy.

Although this surgical approach does not completely eliminate morbidity risk, it has been shown to considerably improve the prognosis.<sup>5</sup>

Long-term follow-up is recommended for the possible late complications after surgical treatment particularly in type IVa cyst, which seems to be more problematic regarding long-term complications. However, it is unclear whether the remaining intrahepatic duct dilatation can really affect the postoperative outcome in children.<sup>6</sup>

Herein, we report our experience in treating choledochal cyst using complete cyst excision and reconstruction through Roux-En-Y hepaticojejunostomy.

## Materials and Methods

A total of 30 patients (8 males, 22 females) with choledochal cysts type I and IVa were treated from January, 2012 to December, 2016. The diagnosis was established by either ultrasonography, MRCP or CT scan. The surgical approach was a complete extrahepatic cyst excision with Roux-en-Y hepaticojejunostomy. All choledochal cysts associated to biliary atresia or other anomalies or treated by a different approach were excluded. In those presenting with acute symptoms, they were treated to the acute episodes before definitive surgical intervention. Patient's demographics, presenting symptoms, preoperative complications of the disease, imaging, size and anatomical type of the cysts, plasma liver biochemistry, surgical repair, operative and postoperative morbidity, mortality, the length of hospital stay, pathology and follow-up data were collected and reviewed.

For descriptive analysis mean with range were calculated from numeric variables and numbers (percentage) were used to summarize demographic and practice data.



## Results

The age at diagnosis ranged from 45 days to 12 years (mean 6.2 years). According to the Todani's classification, there were 22 in type I cysts (14 cystic and 8 fusiform) and 8 in type IVa. The diameter of the cyst ranged from 3 to 15 cm (mean 6.5 cm). The presentation was shown in Table I.

<b>Presentation of choledochal cyst</b>	
Mode of presentation	Number
Acute abdominal pain	10
Recurrent abdominal pain	12
Mass	8
Neonatal jaundice	3
Obstructive jaundice	6
Clay colored stool	3
Antenatal ultrasonography	1

All patients had available imaging information before the cyst resection, which consisted of more than one imaging study. All 30 patients underwent preoperative abdominal ultrasound, which was complemented by MRCP in 23 abdominal CT scan in 5 cases. Intrahepatic duct dilatation was confined to the first-order hepatic ducts in 8 patients and these patients were classified as having type IVa choledochal cyst.

### *Operative management and outcome*

Cholecystectomy with complete excision of the choledochal cyst and Roux-en-Y hepaticojejunostomy was performed in all 30 patients.

The patient was positioned supine with a roll placed transversely beneath the upper abdomen. We prefer an extended right subcostal incision. After careful macroscopic examination of the choledochal cyst and liver, the gall bladder is mobilized from its bed while maintaining its continuity with the choledochal cyst. A Kocher maneuver and lateral division of the gastrohepatic ligament accentuated the cyst exposure. The cyst frequently extended beneath the proximal duodenum.

Prior to dissection of the cyst, we always opened the anterior wall of the choledochal cyst transversely because the anatomical variant of the common

hepatic duct was often found in the cystic type choledochal cyst. The incision should be made below the center of the cyst. By opening the anterior wall of the cyst, the posterior wall of the cyst was visible directly from the inside, and the choledochal cyst could be freed from surrounding tissues including the portal vein and hepatic artery more easily than by dissecting the cyst free without incising the anterior wall.

Once encircled, the dissection was carried inferiorly to the head of the pancreas as the common bile duct tapers to enter the substance of the pancreas. Following complete mobilization, stay suture were placed at the distal neck of the cyst, the cyst is transected and the stump was oversown with an absorbable suture. Sometimes the distal duct was diseased as it traversed the pancreatic substance. In these cases, local mucosectomy was performed to avoid the pancreatic ductal injury. Once the distal duct divided, the cyst was reflected cephalad and the posterior dissection was continued until the bifurcation of the hepatic duct was encountered. The common hepatic duct was then transected circumferentially immediately distal to the bifurcation, where it should appear healthy and well vascularized. In type IVa choledochal cyst, dilated proximal intrahepatic ducts were cleared of debris by irrigation with normal saline. In 4 patients with type I choledochal cyst, the common hepatic duct was narrow (about 4-5 mm wide) and the left hepatic duct was incised for a variable distance (5-10 mm) to allow a wide hilar hepatico-enterostomy. Reconstruction is performed with a Roux-en-Y conduit of jejunum. A 30-40 cm length of the jejunum (depending on the age of the child) was selected, as measured approximately 15-20 cm distal from the duodenojejunal flexure, where the jejunum was divided. The conduit was brought through the retrocolic window within the transverse mesocolon avoiding close proximity to the

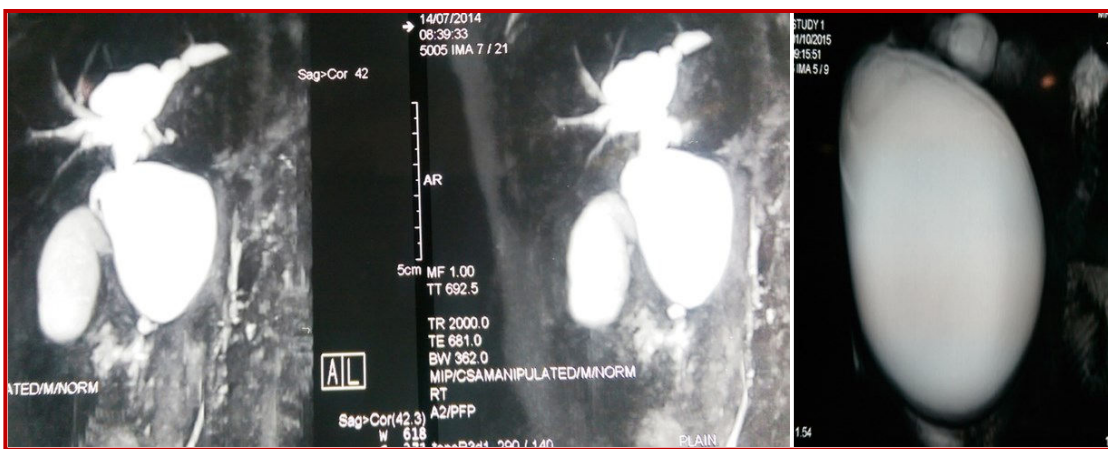


Figure 1: Preoperative evaluation with MRCP (Giant choledochal cyst)

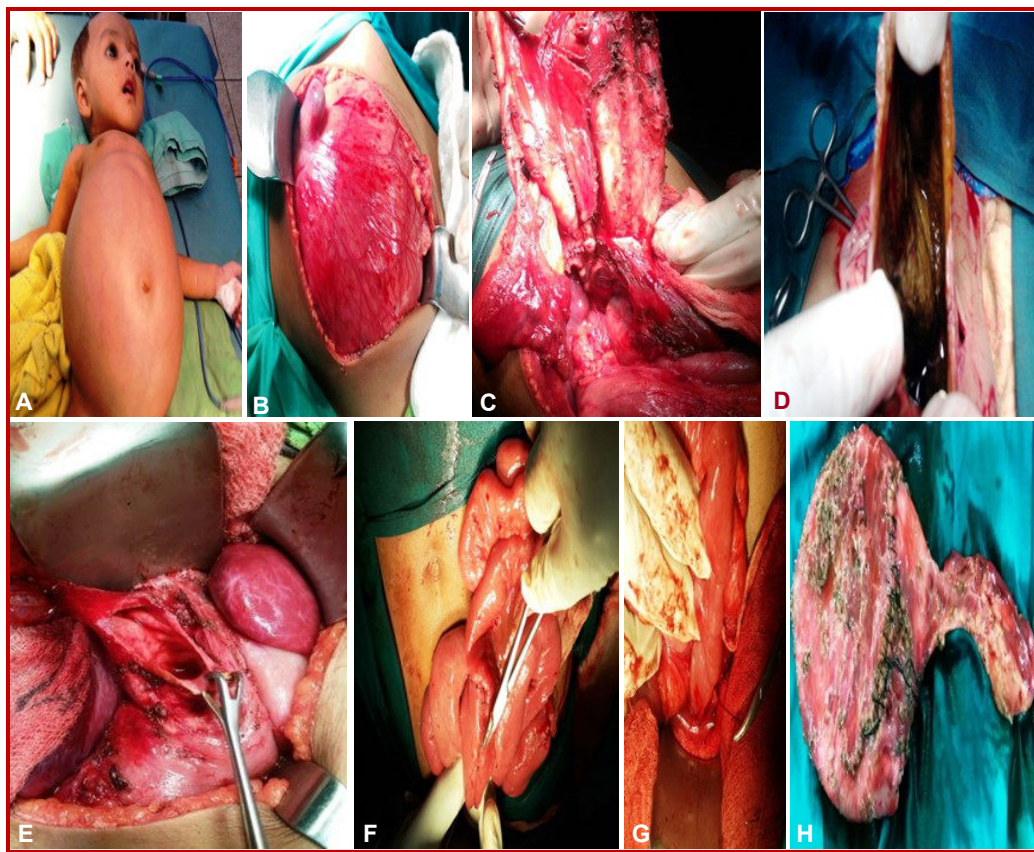


Figure 2: Preoperative view of the choledochal cyst (A), Intraoperative giant choledochal cyst (B), Gall bladder was separated from the liver bed (C), Interior of the choledochal cyst (D), Hepatic duct opening (E), Roux-en-Y jejunostomy (F), Hepaticojejunostomy (G) and resected choledochal cyst (H)

middle colic artery. To complete the Roux-en-Y, an end to side jejunostomy was performed using a two layer closure and the mesenteric defects are closed. The hepaticojejunostomy was performed in an end-to-end or end-to-side fashion by using full thickness, single-layer interrupted, and monofilament absorbable suture. Fixation of the jejunal serosa to the transverse mesocolon in four quadrants as it traversed the mesenteric window to avoid tension on the hepaticojejunostomy and internal herniation. Following assurance of adequate hemostasis, a suction drain was positioned in the subhepatic space and brought out through a separate stab wound. The abdominal wound was then closed in layers. Antibiotics were used postoperatively for 7 days. The drain tube was removed if there was no bilious drainage following the resumption of a regular diet. The drain tube was kept for an average of 6 days.

During surgery, minor injury to the head of the pancreas occurred in one patient in which pancreatic secretions drained via the drain tube for 12 days which was stopped spontaneously and complete recovery was followed. In another 45 days old infants, whose liver had early cirrhotic change with

ascites and hypoalbuminemia, have longer tube drainage about 28 days, which stopped with conservative management.

There were no postoperative mortality, no postoperative anastomotic leakage or adhesive bowel obstruction and not required any surgical revision.

The median hospital stay was 8.5 days (range 6-30 days).

During a median follow-up of 3 years (range 6 months to 4 years), 3 patients had abdominal pain and fever which seems to be cholangitis or pancreatitis and managed conservatively but the biochemical tests result were within normal limit except leucocytosis and mild increase amylase level.

Regarding intrahepatic dilatation of 8 cases of type IVa cysts, 4 cases had no longer dilatation following operative repair revealed by an abdominal scan. However, four cases still had intrahepatic dilatation with no symptoms at all.

## Discussion

In our series, we found common presenting

findings of patients are abdominal pain, vomiting and icterus. During infancy, common findings were jaundice. Hepatomegaly and acholic stool can resemble biliary atresia.<sup>7</sup> For preoperative diagnosis of choledochal cyst, abdominal ultrasonography is the initial diagnostic modality of choice. A properly performed high resolution ultrasonography can precisely measure intra/extrahepatic duct dilation and detect the presence of sludge or stone in the cyst or distal choledochus. Recently the magnetic resonance cholangiopancreatography (MRCP) has found to be useful in assessing the hepatobiliary and pancreatic pathology in children. MRCP has superseded the use of CT scan and ERCP for preoperative anatomical delineation of the pancreaticobiliary tract. MRCP or the intraoperative cholangiogram has a definite role in planning surgical management of choledochal cysts. All of our patients had a preoperative complete workup imaging evaluation.

Choledochal cyst is a congenital abnormality that requires surgical intervention to prevent hepatobiliary and pancreatic complications.<sup>8</sup> Currently complete excision of a cyst with cholecystectomy and Roux-en-Y hepaticojejunostomy is the standard approach in type I and IVa cysts. The incidence of recurrent cholangitis, intrahepatic calculi and postoperative anastomotic stricture has improved significantly with this procedure.

The surgical treatment of choledochal cyst has evolved and been refined over the past century. Although aspiration and marsupialization were the earliest forms of surgical therapy, the development of external biliary fistula often led to insurmountable fluid and electrolyte imbalance. Alonzo-lej et al analyzed the various approaches used in their 1959 report and pointed out that these simple external drainage techniques were unsuccessful.<sup>2</sup>

Fonkalsurd and Boles confirmed the same low mortality rate and technical advantages of cystoduodenostomy in 1965 and reinforce the value of this procedure.<sup>10</sup> Thus internal drainage without cyst excision was the preferred approach at that time. Subsequent patient evaluation however revealed morbidity rates approaching 50% primarily a result of cholangitis from duodenal reflux. The Roux-en-Y cystojejunostomy was subsequently developed as an alternative to cystoduodenostomy to avoid duodenal reflux associated complications. Although the overall morbidity was diminished, the risk of malignant degeneration within the cystic remnant was recognized. As preoperative and postoperative management improved in the early 1970s, the initial unfavorable results with cyst excision begun to be reexamined. In 1970, it was reported favorable result with cyst excision, which stimulated reintroduction of this procedure in other centers around the world.<sup>11,12</sup> Consequently, the surgical procedure of choice is now total cyst excision with

cholecystectomy and internal drainage through Roux-en-Y hepaticojejunostomy as described by Saito in 1966.

In our series, all patient with type I and IVa choledochal cysts were capable of having total cyst excision and Roux-en-Y hepaticojejunostomy. While most surgeons performed a Roux-en-Y hepaticojejunostomy after complete excision of cyst, some surgeons prefer a hepaticoduodenostomy after excision of cyst.<sup>13</sup> However some reports showed that about 33.3% of patients have symptomatic bile gastritis and of course the potential for metaplasia for malignancy in long-term due to duodenogastric bile reflux across the pylorus and a 10% incidence of cholangitis due to reflux of duodenal content into biliary tree which is often dilated.<sup>13,14</sup>

The incidence of postoperative complications varies with age, type of cysts, surgical procedure and preoperative complications. The incidence of postoperative complication in children (9%) is lower than in adults (42%).<sup>15</sup> Postoperative cholangitis more in type IVa cysts than type I cysts ranging from 33 to 44%. Complete excision of cyst reduces the risk of malignancy development, but is found it about 0.7% which is well above that of the general population.<sup>16</sup> From this review, the occurrence of malignancy in children was more than 10 years while that for adult could occur within very short interval after surgery. This emphasizes the importance of the awareness of the problem with early and proper surgery and regular follow-up.

---

## Conclusion

Complete excision of cyst and a Roux-en-Y hepaticojejunostomy gives excellent results and usually safe, feasible and reproducible as a primary procedure.

---

## References

1. Yamaguchi M. Congenital choledochal cyst analysis 1433 patients in the Japanese literature. *Am J Surg.* 1980; 140: 653-57.
2. De vries JS, de Vries S, Aronso DC, Bosman DK, Rauws EA, Bosma A, Heij HA, Gouma DJ, van Gulik TM. Choledochal cysts: Age of presentation, symptoms and late complications related to Todani's classification. *J Pediatr Surg.* 2002; 37: 1568-73.
3. Atkinson HDE, Fischer CP, de Jong CHC, KK Madhavan KK, RW Parks RW, OJ Garden OJ. Choledochal cysts in adults and their complications. *HPB (Oxford)* 2003; 5: 105-10.
4. Voyles CR, Smadja C, Shands WC, Blumgart LH. Carcinoma in choledochal cysts: Age related incidence. *Arch Surg.* 1983; 118: 986-88.

5. Ono S, Fuminos, Shimadera S, Iwai N. Long-term outcome after hepaticojejunostomy for choledochal cyst: A 10 to 27 years follow-up. *J Pediatr Surg.* 2010; 45: 376-78.
  6. Shimamura K, Kurosaki I, Sato D, Takano K, Yokoyama N, Sato Y, Hatakeyama K, Nakadaira K, Yagi M. Intrahepatic cholangio carcinoma arising 34 years after excision of a type IV-A congenital choledochal cyst, report of a case. *Surg Today.* 2009; 39: 247-51.
  7. Miyano T, Yamataka A, Li L. Congenital biliary dilatation. *Semin Pediatr Surg.* 2000; 9: 187-95.
  8. Scudamore CH, Hemming AW, Teare JP, Fache JS, Erb SR, Watkinson AF. Surgical management of choledochal cysts. *Am J Surg.* 1994; 167: 497-500.
  9. Alonso-Lej F, Rever WBJ, Pessagno DJ. Congenital choledochal cyst with a report of 2 and an analysis of 94 cases. *Int Abstr Surg.* 1959; 108: 1-30.
  10. Fonkalsurd EW, Boles ET. Choledochal cysts in infancy and childhood. *Surg Gynecol Obstet.* 1965; 121: 733-42.
  11. Kasai M, Asakura Y, Taira Y. Surgical treatment of choledochal cyst. *Ann Surg.* 1970; 172: 844.
  12. Ishida M, Tsushida Y, Saito S, et al. Primary excision of choledochal cysts. *Surgery* 1970; 68: 884.
  13. Takada K, Hamada Y, Watanabe K, Tanano A, Tokuhara K, Kamiyama Y. Duodenogastric reflux following biliary reconstruction after excision of choledochal cyst. *Pediatr Surg Int.* 2004; 21: 1-4.
  14. Shimotakahara A, Yamatuka A, Yanai T, Kobayashi H, Okazaki T, Lane GJ, Miyano T. Roux-en-Y hepaticojejunostomy or hepaticoduodenostomy for biliary reconstruction during the surgical treatment of choledochal cyst: Which is better? *Pediatr Surg Int.* 2005; 21: 5-7.
  15. Tao KS, Lu YG, Wang T, Dou KF. Procedure for congenital choledochal cysts and curative effect analysis in adults. *Hepatobiliary Pancreat Dis Int.* 2002; 1: 442-45.
  16. Watanabe Y, Toki A, Todani T. Bile duct cancer development after cyst excision for choledochal cyst. *J Hepatobiliary Pancreat Surg.* 1999; 6: 207-12.
-