

# Upper thoracic tuberculous spondylitis

Raihan Kamal Galib, Rajashish Chakraborty, Shamim Ahmed and Mohammed Atiqur Rahman

## Article Info

Department of Respiratory Medicine,  
Faculty of Medicine, Bangabandhu  
Sheikh Mujib Medical University,  
Shahbag, Dhaka, Bangladesh

### For Correspondence:

Raihan Kamal Galib  
raihankamalgalib@gmail.com

Received: 2 July 2017  
Accepted: 25 August 2017  
Available Online: 5 September 2017

ISSN: 2224-7750 (Online)  
2074-2908 (Print)

DOI: 10.3329/bsmmuj.v10i3.33700

### Cite this article:

Galib RK, Chakraborty R, Ahmed S, Rahman MA. Upper thoracic tuberculous spondylitis. *Bangabandhu Sheikh Mujib Med Univ J.* 2017; 10: 179-81.

### Copyright:

The copyright of this article is retained by the author(s) [Attribution CC-BY 4.0]

### Available at:

www.banglajol.info

A Journal of Bangabandhu Sheikh Mujib Medical University, Dhaka, Bangladesh

## Abstract

A 17 year old girl visited several physicians with the complaints of upper central chest pain for eight months. She was finally diagnosed as upper thoracic (third thoracic vertebra) tuberculous spondylitis. The diagnosis was probably delayed for its unusual site of presentation and delayed onset of constitutional features like fever, anorexia and weight loss.

## Introduction

Tuberculosis is a severe and contagious disease caused by the infection with members of *Mycobacterium tuberculosis* Complex (MTBC) which most often involves the lungs. Tuberculosis is transmitted by the cough with infectious dose of less than 10 bacteria.<sup>1</sup>

According to World Health Organization (WHO), the incidence of tuberculosis was 9.4 million, and the prevalence was 14 million, approximately 1.7 million people died in 2009.<sup>2</sup> In 2011, the incidence of tuberculosis was 3,40,000 and prevalence was 225 cases per 1,00,000 in Bangladesh according to WHO global TB report, 2012.<sup>1</sup> Harisinghani et al. reports that the resurgence of tuberculosis has occurred since the mid 1980s due to acquired immune deficiency syndrome epidemic and increasing drug resistant strain.<sup>2</sup>

Tuberculosis is predominantly a respiratory disease affecting lungs. 30% cases involve the extrapulmonary site with or without concomitant pulmonary involvement.<sup>1</sup> Patient usually presents with the constitutional feature and the local feature related to the site of the disease.<sup>3</sup> Occurrence of skeletal tuberculosis among tuberculosis in general was approximately 3 to 5. Twenty-five to fifty percent of all skeletal tuberculosis are located in the spine.<sup>2</sup> Tuberculous infection reaches the spine through blood stream or adjacent infected sites.

Definitive diagnosis of extrapulmonary tuberculosis is difficult, provided other diseases mimicking tuberculosis is excluded.<sup>3</sup> Osseous lesion results in endogenous reinfection from a post-primary case or reactivation from latent tuberculosis. Tuberculosis of the spine affects mainly mid and lower thoracic (67.0%) T5 to T8, upper thoracic (17.2%) T1 to T4, lumber (10.4%) and cervical (3.5%) spine.<sup>4</sup> Infection gradually

involves the anterior aspect of the intervertebral joints, spread behind the anterior longitudinal ligament to involve the adjacent vertebra and intervertebral disc. Eventually overlying discs dies as a result narrowing and subsequent vertebral collapse. Spinal cord compression occurs resulting in paraplegia. According to degree of external compression, gradual involvement of motor, sensory and then autonomic fibers. There may be local pain, muscle spasm, rigidity, characteristic erect posture and Aldermanic gait. Constitutional symptoms occur in less than 40% cases.

## Case Report

A 17 year old girl presented to us with complaints of the neck swelling for a month and low grade fever for 7 days. But on query, she gave history of deep seated upper central chest pain for 8 months, which was gradual in onset and slowly progressive. For which she consulted several doctors and took non-steroidal anti-inflammatory drug (NSAID), proton pump inhibitor but pain was never resolved completely. After several month of chest pain, she became anorectic and lost about 4 kg weight within the 4 months. The neck swelling situated just below the nape of her neck which was noticed by her parents 1 month ago and she also developed low grade fever 7 days before admission in our hospital.

Physical examination revealed mild anemia, tachycardia and raised temperature on general examination. On systemic examination of the respiratory system, nervous system was normal except a gibbus present just below the prominence of her 7<sup>th</sup> cervical vertebra. Routine blood test showed mild anemia with high ESR (110 mm in 1st hour) and positive MT test (15 mm). Chest X-ray P/A view revealed superior



mediastinal widening (Figure 1). Computer tomography of chest with contrast revealed destruction of D2 vertebra with pre- and para-vertebral abscess extending from the D1 to D3 vertebral level (Figure 2). As history, physical examination and investigation are consistent with Pott's patient was put on anti-Koch's with steroids and patient was clinically improving from next day. She was also advised for regular follow-up on 15 days interval.

### Discussion

This young girl presented with central chest pain with fever, anorexia and weight loss, examinations revealed, gibbus on upper thoracic spine. Investigations revealed superior mediastinal mass on chest X-ray, destruction of D2 vertebra with pre- and para-vertebral abscess extending from D1 to D3 vertebra on CT chest. Tuberculosis of spine usually presents with 3 common signs/symptoms: systemic toxemia, osseous lesion and neurological involvement.<sup>4</sup> In our patient, we observed systemic toxemias, for example, fever, anorexia, weight loss and osseous lesion like chest pain. Gibbus was

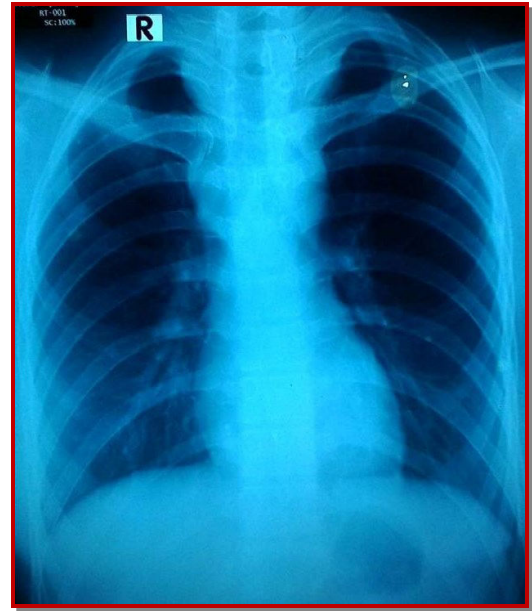


Figure 1: X-ray chest PA view

present. But central type of lesion in spine explains

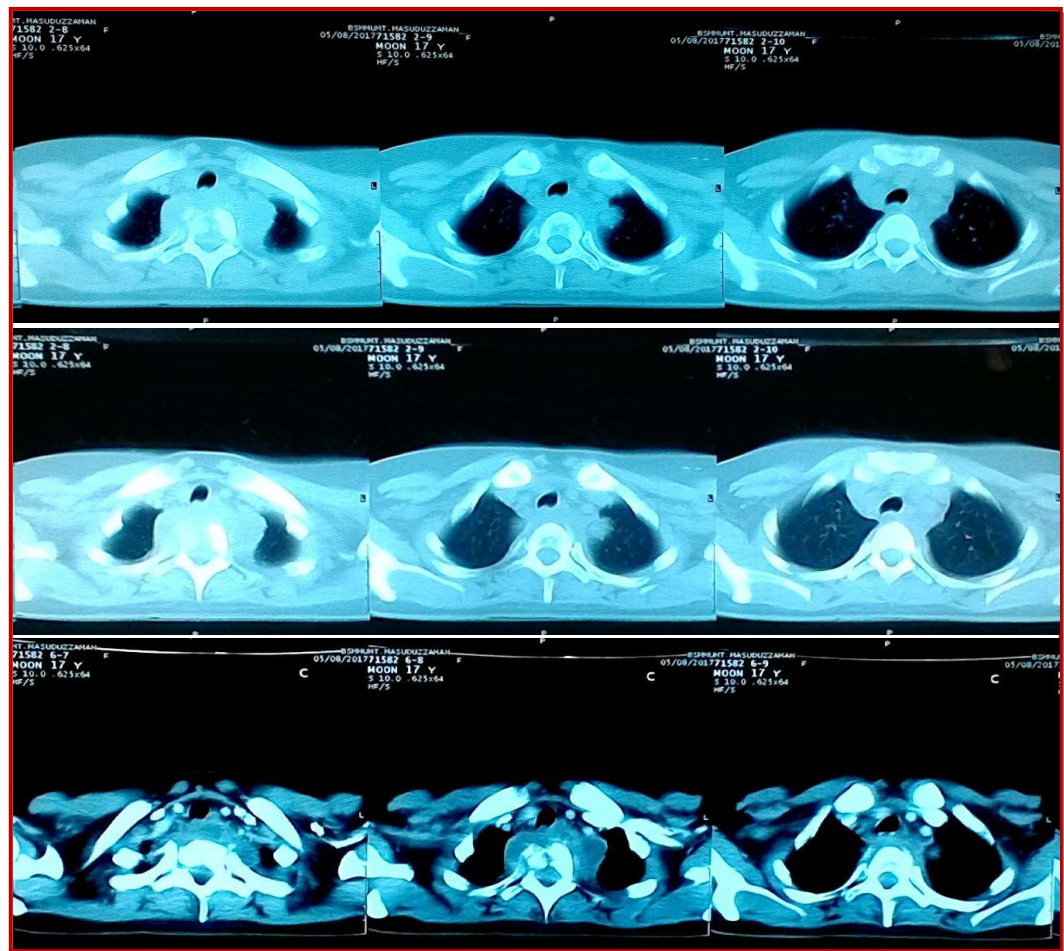


Figure 2: Computer tomography of the chest

absence of neurological features like absence of leg weakness (spastic paraplegia), bowel bladder involvement, normal reflexes and flexor plantar response.<sup>4</sup> Lack of neurological involvement, less common upper thoracic lesion, were important cause for delayed diagnosis. Routine investigation was suggestive of tuberculous spondylitis example high ESR (94.5%)<sup>5</sup> and positive MT. Radiologically classic findings were involvement of two adjacent vertebra with loss of intervertebral disc.<sup>6</sup> But our patient had central irregular osteolytic lesion involving body of D2 vertebra.<sup>2</sup> FNAC was not done due to critical position of the lesion. As history clinical features and other investigations are highly suggestive of tuberculosis, so, we started antitubercular drug with steroids. Tuberculosis of spine is medical disease, surgical intervention may disturb growth potential in children.<sup>7</sup> moreover it is difficult to operate on upper thoracic vertebra (T1 to T4).<sup>8</sup> So, we discharged the patient with advice for frequent follow-up.

---

### Conclusion

As upper thoracic tuberculous spondylitis was less common than mid and lower thoracic, the high index of suspicion required diagnosing such case. Best outcome is expected if the diagnosis is made on the early stages before the appearance of spinal deformity and neurological symptom.

---

### Acknowledgement

Authors acknowledge all the doctors of the Department of Respiratory Medicine, Bangabandhu Sheikh Mujib Medical University.

---

### References

1. Grippi M, Elias J, Fishman J, Pack A, Senior R, Kotloff R. Fishman's Pulmonary disease and disorder. 5th ed. 2 vol. New York, McGraw-Hill Medical, 2015, p 3972.
2. Harisinghani MG, Mcloud TC, Shepard JA, Ko JP, Shroff MM, Mueller PR. Tuberculosis from head to toe. *Radiographics* 2000; 20: 449-70.
3. National Guideline and operational for tuberculosis control. 5th ed. 2015, p 18.
4. Ahmed EBGE. Clinical pattern of Pott's disease of spine in adult Sudanese patients. *Inis Repository Search*. 1997; 30: 17-18.
5. Alothman A, Memish ZA, Awada A, Al-Mahmood S, Al-Sadoon S, Rahman MM, Khan MY. Tuberculous spondylitis: Analysis of 69 cases from Saudi Arabia. *Spine (Phila Pa 1976)*. 2001; 26: E565-70.
6. Hoffman EB, Crosier JH, Cremin BJ. Imaging in children with spinal tuberculosis. *J Bone Joint Surg Br*. 1993; 75: 233-39.
7. Jain AK, Sreenivasan R, Mukunth R, Dhammi IK. Tubercular spondylitis in children. *Indian J Orthop*. 2014; 48: 136-44.
8. Babashahi A, Mortazaviha S, Zaim I, Ranjbar F, Safari H, Teymoori A, Mashari M, Izadi L, Khoshnood R, Mirzaei H. Upper thoracic spine tuberculosis with pathologic fracture and cord compression. *Int J Spine Surg*. 2012; 6: 2.