

A 48 year old male with jaundice and exertional chest pain

Mohammad Mizanur Rahman, Md. Monirul Islam, Susane Giti, Mimi Parvin, Arif Ahmed Khan and Debashish Saha

Article Info

Department of Hematology, Armed Forces Institute of Pathology, Dhaka Cantonment, Dhaka, Bangladesh (MMR, MMI); Department of Pathology, Combined Military Hospital, Chittagong, Bangladesh (SG); Department of Chemical Pathology, Armed Forces Institute of Pathology, Dhaka Cantonment, Dhaka, Bangladesh (MP, DS); Department of Microbiology, Armed Forces Institute of Pathology, Dhaka Cantonment, Dhaka, Bangladesh (AAK)

For Correspondence:

Mohammad Mizanur Rahman
mizan142004@yahoo.com

Received: 19 September 2017
Accepted: 28 October 2017
Available Online: 26 November 2017

ISSN: 2224-7750 (Online)
2074-2908 (Print)

DOI: 10.3329/bsmmuj.v10i4.34151

Cite this article:

Rahman MM, Islam MM, Giti S, Parvin M, Khan AA, Saha D. A 48 years old male with jaundice and exertional chest pain. *Bangabandhu Sheikh Mujib Med Univ J.* 2017; 10: 227-33.

Copyright:

The copyright of this article is retained by the author(s) [Attribution CC-BY 4.0]

Available at:

www.banglajol.info

A Journal of Bangabandhu Sheikh Mujib Medical University, Dhaka, Bangladesh



Presentation of Case

Dr. Md. Monirul Islam: A 48 year old male attended the cardiac outpatient department with the complaints of chest pain on exertion. Two years back, he developed chest pain on exertion. The pain was retrosternal, dull in nature, non-radiating, aggravated on exertion and relieved by rest. There was no relation with food intake and not relieved by taking H₂ blocker. The patient was a known case of hypertension for the last 10 years. He was on antihypertensive medication and his blood pressure was controlled with therapy. There was no history of respiratory distress and cough. With these complaints, he at first attended to a nearby Government medical college hospital in Barisal (South central division of Bangladesh). In that hospital, the patient was diagnosed as coronary artery disease after performing first line investigations and referred to the capital city for further evaluation and management.

In a private clinic in Dhaka, he underwent necessary routine and special investigations including full blood count, random blood sugar, liver function tests, hepatitis viral profile (anti-HAV, anti-HEV, HBsAg, anti-HCV, anti-HIV, coagulation testing such as bleeding time, clotting time, prothrombin time and activated partial thromboplastin time, VDRL, TPHA, X-ray chest and KUB region, ultrasonogram of whole abdomen and coronary angiogram. Results of all investigations revealed mildly reduced hemoglobin (11.0 g/dL) and mildly raised serum bilirubin (3.4 mg/dL). Coronary angiogram detected double vessel coronary artery disease. After analyzing the history, clinical findings and the results of all investigation, the patient was diagnosed as a case of double vessel coronary artery disease with mild jaundice. As the prime problem of the patient was related to the cardiovascular system, so the treating physician focused on double vessel coronary artery disease and decided to perform coronary artery bypass graft operation.

The brother in law of the patient has been serving in Bangladesh Military, so the patient is entitled to get treatment in military hospital. Therefore, the patient got admitted into the

cardiac centre of a tertiary care military hospital, Dhaka on 4th May, 2017. The attending physician took detailed history of the patient, re-examined and evaluated the results of all investigations so far done. Here, the history also unveiled that he is a smoker, taking indigenous cigarettes (Biri), about 10 sticks per day, non-diabetic and also suffering from the peptic ulcer disease for which he is regularly taking H₂ blocker and also had family history of coronary artery disease. On general examination, all parameters were within normal limits including blood pressure (130/60 mm Hg) except mild anemia and jaundice. Systemic examination revealed no abnormality. He also advised to repeat all previous investigations including coronary angiogram and requested to do some more additional investigations such as peripheral blood film examination, reticulocyte count, hemoglobin electrophoresis and renal function tests including eGFR as well as thyroid function tests to resolve the problem of hyperbilirubinemia as well as to see the anesthetic and operation fitness. On the basis of history, physical findings and results of previous investigations carried out in a private clinic. The attending cardiac surgeon made the provisional diagnosis.

Provisional Diagnosis

Double vessel coronary artery disease with hyperbilirubinemia

Differential Diagnosis

Dr. Mohammad Mizanur Rahman: This patient reported to the hospital for a problem related to cardiovascular system and after investigations, his diagnosis was almost confirmed as double vessel coronary artery disease. But mild hyperbilirubinemia with mild anemia in this patient indicated the presence of a second pathology other than the liver disease and was taken into consideration for differential diagnosis in this present case presentation. Therefore, I would like to focus on the following differential diagnoses related to mild hyperbilirubinemia

with mild anemia.

Chronic Malaria

The history of man and malaria is thought to be educed together. A number of genetic conditions such as hemoglobin C and red cell Duffy negativity provide some form of defense or resistance to *Plasmodium falciparum* and *P. vivax* respectively and these conditions are more prevalent in West Africa and West and Central Africa indicating the original root of malaria in these regions.¹

It is difficult to define chronic malaria as there is differences of opinion about its definition. However, in semi-immune individuals without fever or any other symptoms pertaining to malaria persisting for a considerable period may be the features of chronic malaria but some authors argues that asymptomatic or chronic malaria does not exist.^{2,3} Chronic presence of malarial parasites is the cause of mild hemolysis leading to asymptomatic anemia and inclines the affected individuals to other infections.⁴ Patient with malaria may present with mild jaundice which is frequently missed clinically. Such jaundice is quite common and may be detected in 20–40% of the cases. Severe *P. falciparum* malaria is usually associated with deeper jaundice and serum bilirubin level may be more than 3 mg/dL and is consociated with anemia, hyperparasitemia and malarial hepatitis with elevated serum enzymes. In all cases of mild jaundice, malaria must be considered as a differential diagnosis, preferably in a malarious zone.⁵ In this patient, mild anemia and jaundice favor the diagnosis of chronic malaria but absence of splenomegaly, previous history of malaria and residing in non-malarious zone are against the diagnosis of malaria.

Inherited Hemolytic Anemias

Mild hyperbilirubinemia is caused by an increased rate of hemolysis. The prime cause of unconjugated hyperbilirubinemia is the escalated red blood cell destruction and accumulation of such bilirubin into various tissues can lead to yellowish or jaundiced appearance. Certain genetic red cell disorders, such as thalassemia and hemoglobinopathies, spherocytosis as well as red cell enzyme defects like pyruvate kinase and glucose 6-phosphate dehydrogenase deficiency can lead to mild hyperbilirubinemia.^{6,7} In the perspective of Bangladesh, beta thalassemia trait, HbE disease and hereditary spherocytosis are the potential candidates to be considered in the differential diagnosis.

Beta thalassemia trait: Thalassemias are inherited genetic blood disorders transmitted in an autosomal recessive pattern from one generation to next generation. Mainly two types of thalassemia exist– alpha thalassemia and beta thalassemia.⁸ Beta thalassemias are more prevalent among the peoples of Mediterranean origin, Arabian Peninsula such as

Palestinians and people of Palestinian descent and Asians. In the world, the incidence of beta globin chain defect with a carrier rate of 18% of the population in Maldives is found and the evaluated frequency is 15% in people from Cyprus, 1% in Thailand and 3–7% in populations from Bangladesh, China, India, Malaysia and Pakistan.⁹ Symptoms of beta thalassemia can vary and may be completely asymptomatic to the signs and symptoms of mild anemia (e.g., feeling tired and pale skin) as well as mild jaundice and dark urine. Individuals with beta thalassemia minor may have some shield against malaria and such phenomenon explains its high incidence in areas of the world where plasmodium infections exist.¹⁰ Beta thalassemia heterozygosity is associated with a reduced risk against advanced coronary artery disease. Individuals with beta thalassemia have such lipoproteins and blood rheology profile that may be the underlying causes of this safeguard effect.¹¹ There is a possibility of this patient is being thalassemic as mild anemia and jaundice are present but early development of coronary artery disease is against heterozygous beta thalassemia because it has mild protective effect against coronary artery disease.

This patient, presented with mild anemia and jaundice, favors the diagnosis of inherited hemolytic anemia that may be hemoglobin, red cell membrane or enzyme disorders. But age of the patient and absent family history of inherited hemolytic disorders are the possible points against the diagnosis of inherited hemolytic anemia.

Hemoglobin E: A single point mutation in beta (β) globin chain at position 26 causing substitution of glutamic acid to lysine results in the formation of an abnormal hemoglobin called HbE. HbE is most prevalent among peoples of South Asian countries including Bangladesh.¹² Among hemoglobinopathies and thalassemias, HbE is in the second position in terms of its frequency among hemoglobin disorders in the world and also common in Bangladesh.¹³ HbE is the most common in mainland Southeast Asia (Thailand, Myanmar, Cambodia, Laos and Vietnam). In Northeast India, the carrier rate of HbE reach approximately 60% of the population. Its incidence is also very high in Bangladesh.¹⁴ Individual with homozygous HbE allele may have the features of mild hemolytic anemia such as mild anemia but the jaundice may or may not be present. Mild splenomegaly may be present.¹⁵ Presence of mild anemia and jaundice favors the diagnosis of HbE disease but absence of family history of hemoglobinopathies and thalassemias as well as splenomegaly are against the diagnosis of HbE disease.

Spherocytosis: Hereditary spherocytosis and autoimmune hemolytic anemia are characterized by the presence of spherocytes which are sphere-shaped

and lack of central pallor in the peripheral blood. Hereditary spherocytosis is inherited as autosomal dominant fashion and results from the defects of cytoskeleton of red cells. Clinically patients with hereditary spherocytosis presented with mild to moderate anemia, mild jaundice and splenomegaly and also in some cases gall stone formation.¹⁶ Due to the presence of mild anemia and jaundice, hereditary spherocytosis may be one of the differential diagnoses in this patient but negative family history, non-palpable spleen and absence of cholelithiasis are against the diagnosis of hereditary elliptocytosis. Autoimmune hemolytic anemia occurs when anti-bodies are formed against the person's own red cells and make them susceptible to lyse leading to hemolysis and development of severe anemia, jaundice and splenomegaly.¹⁷ Autoimmune hemolytic anemia is an uncommon condition, occurs in one to three people per 100,000 per year. In about 50% of cases, autoimmune hemolytic anemia is secondary to many other illnesses.¹⁸ This patient had mild anemia and absence of splenomegaly which disfavor the diagnosis of autoimmune hemolytic anemia but jaundice is in favor of autoimmune hemolytic anemia.

Gilbert's Syndrome

Among the abnormal bilirubin metabolism of genetic nature, Gilbert's syndrome is one of the common types of unconjugated hyperbilirubinemia, accounting 5% of the population. A considerable number of people are asymptomatic but many patients with Gilbert's syndrome may present with mild jaundice. Genetic mutation in the UGT1A1 gene results in reduced activity of the bilirubin uridine diphosphate glucosyltransferase enzyme.

Occasionally patients with Gilbert's syndrome may also have tiredness, weakness and abdominal pain.¹⁹ Many studies on Gilbert's syndrome have shown that a significantly diminished risk of coronary artery disease in individuals with Gilbert's syndrome was found. Importantly, people with mildly increased levels of bilirubin were at lower risk for coronary artery disease as well as future heart disease. Bilirubin IX α , which is recognized as an effective antioxidant was thought to have beneficial effect against coronary artery disease.²⁰ Long-term data from Framingham Heart Study also supported such association.²¹ Patients with Gilbert's syndrome due to unknown mechanism, platelet count and

mean platelet volume are reduced. The increased levels of bilirubin and decreased levels of mean platelet volume and C-reactive protein in patients with Gilbert's syndrome may have an effect to slow down the atherosclerotic process.²² This patient presented with mild jaundice which was detected incidentally and the patient was unwary about the symptoms which were in favor of the diagnosis of Gilbert's syndrome. But presence of mild anemia and coronary artery disease in early age is the points against Gilbert's syndrome.

Dr. Mohammed Kamruzzaman: After three days I received the results of all the investigations which were sent after getting admitted into the cardiac centre. Again I have evaluated all the reports. Coronary angiogram revealed triple vessel coronary artery disease. Blood film showed numerous elliptical red cells suggesting hereditary elliptocytosis and advised to carry out family screening, osmotic fragility test and red cell membrane protein analysis. Hemoglobin electrophoresis was normal. Indirect (unconjugated) serum bilirubin was 2.0 mg/dL and direct (conjugated) 0.6 mg/dL, confirming the presence of unconjugated hyperbilirubinemia. Cardiac specific troponin I (cTr) was negative. But his serum TSH was found raised though the serum FT3 and FT4 were within normal limit. Reticulocyte count was at the upper limit of normal range. Blood film of the only son of the patient also revealed elliptocytosis but his only daughter could not come for family screening. Osmotic fragility of the patient and his son were also normal. Results of all investigations and blood film of the index case and his son are shown in Table I, Figure 1 and Figure 2. In the cardiac center, we all specialists discussed the detailed of the case and decided to refer the case to gastroenterologist and endocrinologist for the opinion about unconjugated hyperbilirubinemia and raised serum TSH.

Dr. S. M. Mizanur Rahman: I reviewed the case and found that the patient is a diagnosed case of triple vessel coronary artery disease with unconjugated hyperbilirubinemia. Laboratory investigations revealed that unconjugated serum bilirubin was 2.0 mg/dL. Blood film was suggestive of hereditary elliptocytosis which was also almost confirmed by family screening and osmotic fragility test, though polyacrylamide gel electrophoresis of red cell membrane protein is required for full confirmation of hereditary spherocytosis. Therefore, the cause of unconjugated hyperbilirubinemia is hereditary elliptocytosis and I advised to consult with hematologist.

Dr. Mohammed Mosleh Uddin: After evaluating the patient and all other investigations, especially the blood film, reticulocyte count, osmotic fragility test and hemoglobin electrophoresis, my impression is hereditary elliptocytosis and I prescribed tablet folic

Table I

Hematological and biochemical parameters		
	Patient	Son
Hb (g/dL)	11.2	13.5
RBC count (x10 ⁹ /L)	3.8	4.9
MCV (fL)	88.0	80.9
MCH (pg)	29.8	27.7
MCHC (g/dL)	33.8	34.2
RDW (%)	15.6	13.8
HbA	97.6	97.7
HbA2	2.4	2.3
Reticulocyte count (%)	2.5	1.0
Osmotic fragility test (%)	0.4	0.4
Serum bilirubin (mg/dL)	2.8	1.0
Serum ferritin (ng/mL)	668.1	63.0

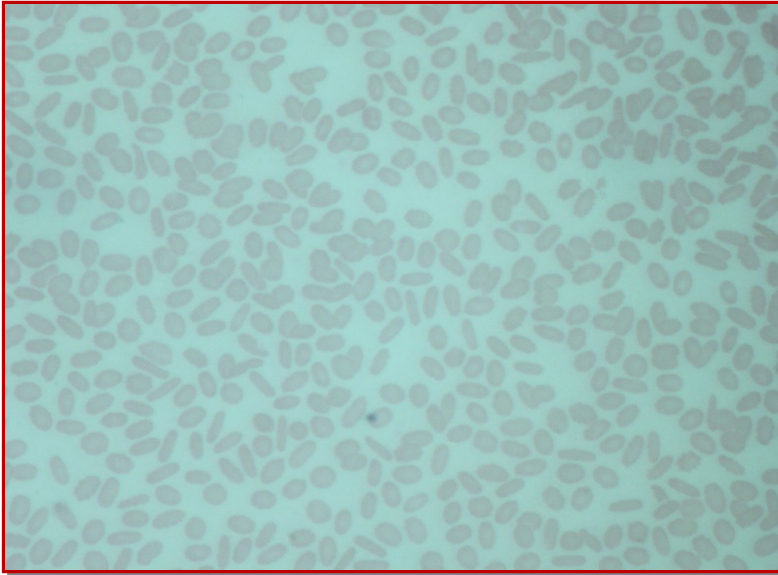


Figure 1: Blood film of the index case showing about 82% elliptocytes

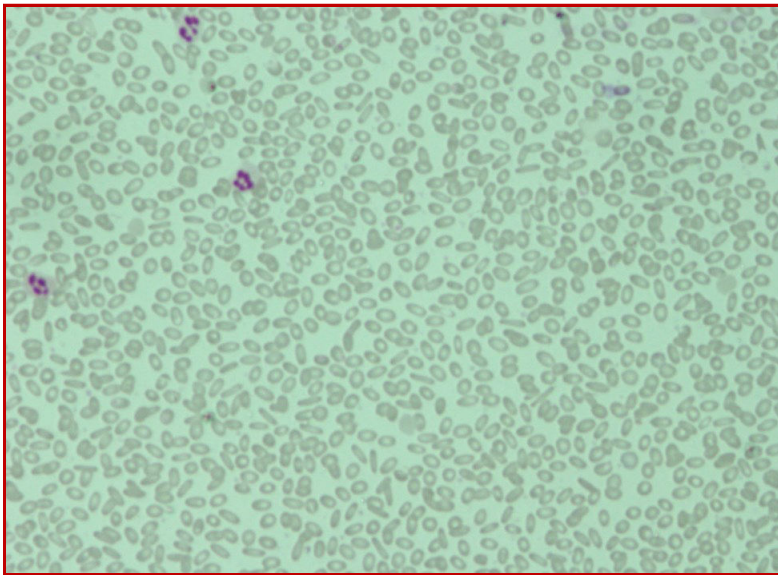


Figure 2: Blood film of son of the index case showing about 67% elliptocytes

acid 5 mg daily continuously. I also emphasized that for the operative treatment of triple vessel coronary artery disease, hereditary elliptocytosis is not a contraindication.

Dr. Md. Anwarul Kabir: This patient was referred for high serum TSH level to me. I evaluated the patient and enquired about the thyroid problems. The patient did not have any signs and symptoms relating to hypothyroidism. As the serum TSH level was repeatedly high, so my clinical impression was subclinical hypothyroidism. I opined that the cardiac surgeons may perform the operative treatment of the patient without thyroid hormone replacement.

Dr. Islam's Diagnosis

Hereditary elliptocytosis with triple vessel coronary artery disease and subclinical hypothyroidism.

Discussion

Dr. Mohammad Mizanur Rahman: Hereditary elliptocytosis is inherited as an autosomal dominant manner.²³ In normal healthy individuals, elliptical red cells are often seen as many as 10% of the red cells. Slightly increased number of elliptocytes is often seen in iron deficiency, thalassemias, sickle cell disease and myelodysplastic syndrome.²⁴ Incidence varies from region to region and is not exactly known because of its asymptomatic nature. In USA, the approximate frequency of hereditary elliptocytosis is between 1 in 1000 to 1 in 5000. No racial or ethnic group is spared but it confers resistance to malaria.²⁵ Hereditary elliptocytosis is caused by numbers of different mutations of genes affecting red cell cytoskeleton and membrane protein integrity. Most of the mutations found in hereditary elliptocytosis occurs in the α -spectrin, β -spectrin and protein 4.1 genes. These mutations are due to single nucleotide substitutions, insertions, deletions and defective RNA processing. Most patients are symptomless with heterozygous form of hereditary elliptocytosis, although some may have splenomegaly and features of hemolysis.²⁶ Diagnosis of hereditary elliptocytosis is usually made by positive family history of the condition and presence of at least 25% elliptocytes of the red cell on a blood smear.²⁷ If there is doubt about the diagnosis, definitive diagnosis can involve osmotic fragility test, an autohemolysis test and direct red cell membrane protein assay by poly acrylamide gel electrophoresis.²⁸ Hereditary elliptocytosis is a rare inherited single gene autosomal dominant Mendelian disorder which was first identified by Dresbach in 1904 and hereditary nature in 1932 by Hunter.²⁹ It is much more common among blacks and in areas where malaria is endemic. In Malayan aborigines, the incidence of hereditary elliptocytosis is high, about 30%, which may explain the resistance of hereditary elliptocytes to invasion by malarial parasites.³⁰ In more than 60% of patients with hereditary elliptocytosis, α -spectrin mutation is mainly responsible for the development of the condition.³¹ Hereditary elliptocytosis is most commonly diagnosed by chance from a blood film or the presence of marginally raised bilirubin.³² In this index case, the blood film showed 82% elliptocytes with hemoglobin level 11.20 g/dL along with normal mean corpuscular fragility, normal hemoglobin electrophoresis and slightly raised serum bilirubin. Reticulocyte count was at the upper limit of the normal range but serum ferritin was raised indica-

ting mild hemolysis and deposition of iron in the body.

The blood film of the son revealed 67% elliptocytes with normal hemoglobin level and all other laboratory investigations including reticulocyte count, hemoglobin electrophoresis, serum bilirubin and serum ferritin were within reference range indicating the absence of hemolysis. Though in both the cases red cell membrane protein assay was not done but basing on family screening and blood film finding, it can be concluded that both have been suffering from hereditary elliptocytosis. Pedigree chart of the index case is shown in Figure 3.

Dr. Mohammad Shahidul Islam: Is there any relationship between hypothyroidism and hereditary elliptocytosis?

Dr. Islam: There is no association between hypothyroidism and hereditary elliptocytosis. Clinical features of hypothyroidism are completely distinctive from hereditary elliptocytosis. Blood film findings also differ from each other. In hypothyroidism, round macrocytes are usually seen but in hereditary elliptocytosis, elliptical cells are found.³³

Dr. Debashish Saha: Is there any cut off count of elliptical cells in the blood film for diagnosing hereditary elliptocytosis?

Dr. Rahman: For diagnosing hereditary elliptocytosis, there should be more than 25% elliptocytes in the blood film as well as a positive family history.²⁷

Dr. Mehedi Hasan Shourov: Do you think that there is relationship between hereditary elliptocytosis and coronary artery disease?

Dr. Islam: No data is available regarding the association between hereditary elliptocytosis and coronary artery disease. It was found that people with mildly elevated levels of bilirubin are at lower risk for coronary artery disease and future heart disease.

This advantageous sequel is due to bilirubin IX α which is recognized as a powerful antioxidant.²⁰

Dr. Dildar Alam: What are the conditions where we may get elliptocytes in the blood film?

Dr. Rahman: Slightly increased number of elliptocytes is often seen in iron deficiency, thalassemias, sickle cell disease and myelodysplastic syndrome.²⁴

Dr. Wasim Selimul Hoque: What type of hereditary elliptocytosis did this patient inherit?

Dr. Rahman: Hereditary ellipto-

cytosis has three major forms: common hereditary elliptocytosis, spherocytic elliptocytosis and South-east Asian ovalocytosis. This patient has been recognized as having common hereditary elliptocytosis which is the least severe form and here it was diagnosed incidentally.³¹

Dr. Mimi Parvin: Why did serum bilirubin elevated in this patient?

Dr. Lutfunnahar Khan: Though the patient is asymptomatic but he is suffering from mild chronic hemolysis which results in unconjugated hyperbilirubinemia.³¹

Dr. Parvin: HbA1c is 3.3% in this patient. How will you explain this?

Dr. Islam: Low HbA1c in this patient may be due to low hemoglobin level (11.2 g/dL) and shortened red cell survival.³⁴

Dr. Rukhsana Khanum: How will you explain normal osmotic fragility test in this patient?

Dr. Rahman: In general a change in the osmotic fragility test is less marked in hereditary elliptocytosis than hereditary spherocytosis. Abnormal osmotic fragility usually correlates with severity of hemolysis, osmotic fragility is usually normal in non-hemolytic hereditary elliptocytosis.³⁵ I think this patient belongs to non-hemolytic hereditary elliptocytosis or there is mild hemolysis that could not interfere the osmotic fragility.

Dr. Arif Ahmed Khan: How will confirm your diagnosis?

Dr. Monwar Tarek: Red cell membrane protein analysis and DNA-based assays to detect mutations within genes for the red cell membrane proteins are the most specific tests for membrane defects but these are not routinely done. Osmotic fragility test and family screening are usually sufficient for diagnosing hereditary elliptocytosis.³²

Dr. Md. Monirul Islam: What are the complications of hereditary elliptocytosis and life expectancy of patients with hereditary elliptocytosis?

Dr. Rahman: Patients with hereditary elliptocytosis have mildly increased risk of developing gallstones. Life expectancy is usually normal but those with very severe disease have a shortened life expectancy.²⁷

Dr. Rahman: How will you differentiate morphologically between elongated/elliptical cells of iron deficiency anemia and of hereditary elliptocytosis?

Dr. Khan: Elliptocytes in iron deficiency anemia have hypochromia but elliptocytes in hereditary elliptocytosis do not have any hypochromia.

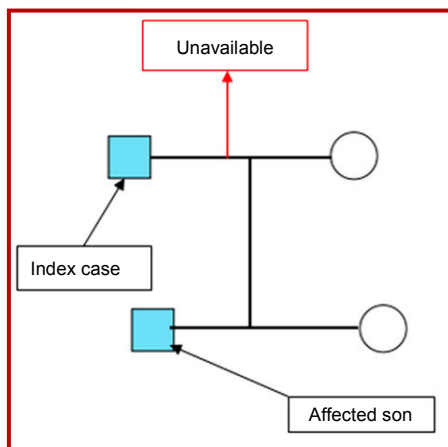


Figure 3: Pedigree chart of the index case

Final Diagnosis

Hereditary elliptocytosis with TVCAD and subclinical hypothyroidism

References

- Carter R, Mendis KN. Evolutionary and historical aspects of the burden of malaria. *Clin Microbiol Rev.* 2002; 15: 564-94.
- Bousema T, Okell I, Felger I, Drakeley C. Asymptomatic malaria infection: Delectability, transmissibility and public health relevance. *Nat Rev Microbiol.* 2014; 12: 833-40.
- Chen I, Clarke SE, Gosling R, Hamainza B, Killen G, Magill A. Asymptomatic malaria: A chronic and debilitating infection that should be treated. *PLoS Med.* 2016; 13: e1001942.
- Bisoffi Z, Leoni S, Angheben A, Beltrame A, Esem FE, Gobbi F, Lodesani C, Marocco S, Buonfrate D. Chronic malaria and hyper-reactive malarial splenomegaly: A retrospective study on the largest series observed in a non-endemic country. *Malar J.* 2016; 15: 230.
- Wangdi K, Gatton ML, Kelly GC, Banwell C, Dev V, Clements ACA. Malaria elimination in India and regional implications. *Lancet Infect Dis.* 2016; 16: e214-24.
- Roche SP, Kobos R. Jaundice in the adult patient. *Am Fam Physician.* 2004; 69: 299-304.
- Winger J, Michelfelder A. Diagnostic approach to the patient with jaundice. *Primary Care.* 2011; 38: 469-82.
- Elliott P. Changing pattern of thalassemia worldwide. *Ann N Y Acad Sci.* 2005; 1054: 11-17.
- Weatherall DJ. Keynote address: The challenge of thalassemia for the developing countries. *Ann N Y Acad Sci.* 2005; 1054: 11-17.
- Weatherall DJ. The thalassemias: Disorders of globin synthesis. In: Williams hematology. Kaushansky K, Lichtman MA, Prchal JT, Levi MM, Press OW, Burns LJ, Caligiuri M (eds). 9th ed. USA, McGraw-Hill Education, 2015, p 725.
- Tassiopoulos S, Deftereos S, Konstantopoulos K, Farmakis D, Tsironi M, Kyriakidis M, Aessopos A. Does heterozygous β -thalassemia confer a protection against coronary artery disease? *Ann N Y Acad Sci.* 2005; 1054: 467-70.
- Chernoff AI, Minnick A, Nanakorn S. Studies on hemoglobin E. The clinical, hematologic and genetic characteristics of the hemoglobin E syndrome. *J Lab Clin Med.* 1956; 47: 455-89.
- Aziz MA, Begum M, Islam MS, Islam N, Rahman MJ, Kabir AL. Hemoglobin E/ β -thalassemia: A study in BSMMU. *Bangladesh Sheikh Mujib Med Univ J.* 2009; 2: 78-80.
- Olivieri NF, Pakbaz Z, Vichinsky E. HbE/ β -thalassemia: A common and clinically diverse disorder. *Indian J Med Res.* 2011; 134: 522-31.
- Hoffbrand AV, Moss PAH. Hoffbrand's essential hematology. In: Hoffbrand AV, Moss PAH (eds). 7th ed. India, Wiley Blackwell, 2016, p 85.
- Afroza S, Aziz L. Anesthetic management of a case hereditary spherocytosis for splenectomy and cholecystectomy. *J BSA.* 2005; 18: 50-53.
- Gehrs BC, Friedberg RC. Autoimmune hemolytic anemia. *Am J Hematol.* 2002; 69: 258-71.
- Sokol RJ, Hewitt S, Stamps BK. Autoimmune hemolytic anemia: An 18 years study of 865 cases referred to a regional transfusion centre. *Br Med J.* 1981; 282: 2023-30.
- Anstee QM, Jones DEJ. Liver and biliary tract disease. In: Davidson's Principle and practice of medicine. Walker BR, Colledge NR, Ralston SH, Penman ID (eds). 22nd ed. London, Churchill Livingstone, 2014, pp 921-89.
- Vítek L, Jirsa M, Brodanová M. Gilbert syndrome and ischemic heart disease: A protective effect of elevated bilirubin levels. *Atherosclerosis* 2002; 160: 449-56.
- Lin JP, O'Donnell CJ, Schwaiger JP. Association between the UGT1A1*28 allele, bilirubin levels and coronary heart disease in the Framingham Heart Study. *Circulation* 2006; 114: 1476-81.
- Cure MC1, Cure E, Kirbas A, Cicek AC, Yuce S. The effects of Gilbert's syndrome on the mean platelet volume and other hematological parameters. *Blood Coagul Fibrinolysis.* 2013; 24: 484-88.
- Hunter WC. Further study of a white family showing elliptical erythrocytes. *Ann Intern Med.* 1932; 6: 775-81.
- Mazzan JJ. Hemolytic anemia: Congenital and acquired. In: Manual of clinical hematology. Mazza JJ (ed). 2nd ed. New York, Little, Brown and Company, 1995, p 95.
- Glader EB, Lukens NJ. Hereditary spherocytosis and other anemias due to abnormalities of the red cell membrane. In: Wintrobe's Clinical hematology. Lee RG, Foerster J, Lukens J, Paraskevas F (eds). Baltimore, Williams & Wilkins, 1999, pp 114-52.
- Soderquist C, Bagg A. Hereditary elliptocytosis. *Blood* 2013; 121: 3066.
- Doherty MG. Current diagnosis and treatment-surgery. In: McGraw Hill Professional, 2010, pp 204-05.
- Hillman SR, Ault AK, Rinder MH. Hematology in clinical practice: A guide to diagnosis and management. 4th ed. McGraw Hill Professional, 2005, p 147.

29. Dresbach M. Elliptical human red corpuscles. *Science* 1904; 19: 469-70.
 30. Mohandas N. Rigid membranes of Malayan ovalocytosis: A likely genetic barrier against malaria. *Blood* 1984; 63: 1385.
 31. Coetzer T, Lawler J, Prchal JT, Palek J. Molecular determinants of clinical expression of hereditary elliptocytosis and pyropoikilocytosis. *Blood* 1987; 70: 766-72.
 32. Bianchi P, Mohandas N. Hereditary disorders of red cell membrane and disorders of red cell metabolism. In: *Postgraduate hematology*. Hoffbrand VA, Higgs RD, Keeling MD, Metha BA (eds). 7th ed. India. Wiley Blackwell, 2016, p 119-21.
 33. Saxena R, Pati HP, Mahapatra M. In: *deGruchy's clinical hematology in medical practice*. 6th ed. India, Wiley India Pvt. Ltd., 2013, p 99.
 34. Adeoye S, Abraham S, Erlikh I, Sarfraz S, Borda T, Yeung L. Anemia and hemoglobin A1c level: Is there a case for redefining reference ranges and therapeutic goals? *BJMP*. 2014; 7: a706.
 35. Layton M, Roper D. Investigation of the hereditary hemolytic anemias: Membrane and enzyme defect. In: *Dacie and Lewis practical hematology*. Bain BJ, Bates I, Laffan MA (eds). 12th ed. China. Elsevier Limited, 2017, pp 229-33.
-