

Multiple primary malignancies

Dibanur Rashid Siddiqua, Shamim Ahmed, Rajashish Chakraborty and Mohammed Atiqur Rahman

Article Info

Department of Respiratory Medicine,
Faculty of Medicine, Bangabandhu
Sheikh Mujib Medical University,
Shahbag, Dhaka, Bangladesh

For Correspondence:

Mohammed Atiqur Rahman
m_a_rahman88@yahoo.com

Received: 25 September 2017
Accepted: 22 November 2017
Available Online: 9 December 2017

ISSN: 2224-7750 (Online)
2074-2908 (Print)

DOI: 10.3329/bsmmuj.v10i4.34863

Cite this article:

Siddiqua DR, Ahmed S, Chakraborty R,
Rahman MA. Multiple primary malignancies.
Bangabandhu Sheikh Mujib
Med Univ J. 2017; 10: 260-63.

Copyright:

The copyright of this article is retained
by the author(s) [Attribution CC-BY 4.0]

Available at:

www.banglajol.info

A Journal of Bangabandhu Sheikh Mujib
Medical University, Dhaka, Bangladesh

Abstract

Two cases of multiple primary malignancies (two or more neoplasms without any relationship between them) are presented in this paper. The first case (65 years) was a male in whom follicular carcinoma of thyroid, metachronous neuroendocrine tumor of duodenum and urinary bladder transitional cell carcinoma were diagnosed within an eight-year period. The second case (65 years) was a female with synchronous dual malignancy of lung and urinary bladder diagnosed within a very short period of time.

Introduction

Now-a-days the malignant tumor is thought to be the new global pandemic. The International Agency for Research on Cancer reported that, there were 14.1 million new cancer cases and 8.2 million cancer deaths in 2012. In the light of studies, it can be assumed that if this continues at this rate, the global cancer burden is expected to increase to 21.7 million cases and 13 million deaths by 2030. About 1,688,780 new cancer cases are expected to be diagnosed within 2017.¹

Multiple primary malignancy is a special phenomenon in carcinogenesis that is beginning to become better understood due to a number of studies worldwide. In multiple primary malignancies, there are two or more synchronous (simultaneous) or metachronous (successive) cancer in the same individual originating from the different sites and/or are of a different histology or morphology group. The term was first described by Billroth at the end of the 19th century² and reported in a detailed study by Warren and Gates.³

The incidence of multiple primary malignancies has been reported to range from 0.7% to 11.7% and the incidence seems to increase with age.⁴ In different geographical regions, the incidence, characteristics, and survival rates associated with multiple primary malignancies have been found to be diverse. Whenever found, they compel us to think regarding the pathogenetic factors of hereditary, immunological or environmental⁵ as well as become a troublesome issue to both patients and clinicians because of limited therapeutic options

available to date.

The occurrence of two primary malignancies in a single individual has been reported with low incidence. The event of three or more is relatively rare to be reported. The aim of this paper is to report two cases; first one being a metachronous three primaries of unusual combination and second one is a synchronous phenomenon of two primaries.

Case Report

Case 1

The first case, a 65 year old man, ex-smoker (20 pack year), hypertensive and diabetic, was admitted to the hospital in 2006 for the evaluation of cough and shortness of breath. A thyroid swelling was noticed at that time but the patient refused to undergo any further assessment for the nodule which he stated to be present for quite a long time and he was discharged with only symptomatic management options. In 2008, he underwent CT guided FNAC from the anterior mediastinal mass which revealed follicular neoplasm of thyroid arising from the retrosternal goiter. Again he refused to take any definitive treatment.

From 2008 onwards, he was only followed up by doing some routine investigations and a further USG-guided FNAC from thyroid swelling which revealed the same. In 2011, he was incidentally diagnosed as neuroendocrine tumor of the duodenum (cytologically proven, moderately differentiated) while performing endoscopy of the upper GIT due to some



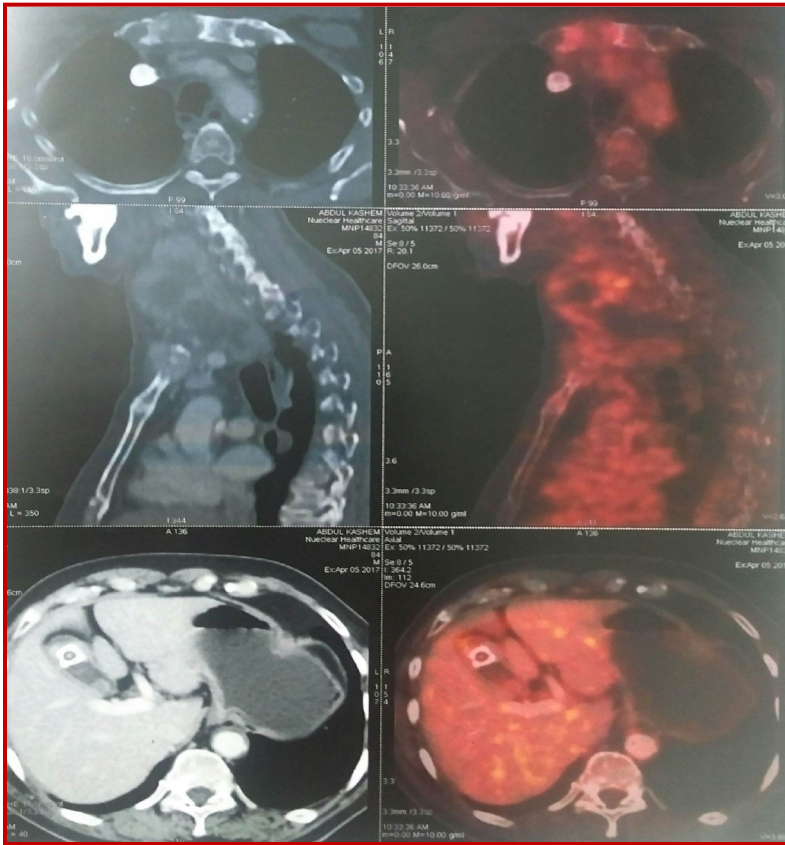


Figure 1: PET-CT scan showing active disease in the enhancing necrotic mass in the right lobe of thyroid, non-FDG avid bilateral lung nodules appear metastatic, low grade metabolic activity in the soft tissue component of sternal lytic lesions appear metastatic

abdominal discomfort. No definite management was given and he was advised to take 6-monthly follow up.

In August 2016, the patient started noticing right sided loin pain and hematuria. The USG of whole abdomen revealed soft tissue mass in the left vesical wall. He underwent urethro-cystoscopy followed by transurethral resection of the urinary bladder tumor in January 2017 and histopathology of the resected specimen confirmed as Grade II transitional cell carcinoma of the urinary bladder.

Two months later, follow-up the USG of the whole abdomen revealed the possible residual or recurrent urinary bladder tumor. So, he was admitted again and treated with diathermy coagulation of the bladder tumor under sub-arachnoid block.

Shortly after that, the patient developed cough and chest pain. Diagnostic work up with contrast enhanced ¹⁸F-FDG of the whole body was performed which showed active disease in the right lobe of the thyroid, non-FDG avid bilateral possible metastatic lung nodules, low grade activity in sternal lytic lesion (Figure 1). No metabolic activity was shown in the duodenal thickening and urinary bladder wall or elsewhere in the body.

The patient was again admitted due to intractable cough, hemoptysis, shortness of breath and generalized weakness. CT scan of the chest with contrast revealed multiple nodular lesions of variable sizes in all lobes of both lung fields (Figure 2). No further histopathological proof of that lung nodules could be done to search for the origin as patient's

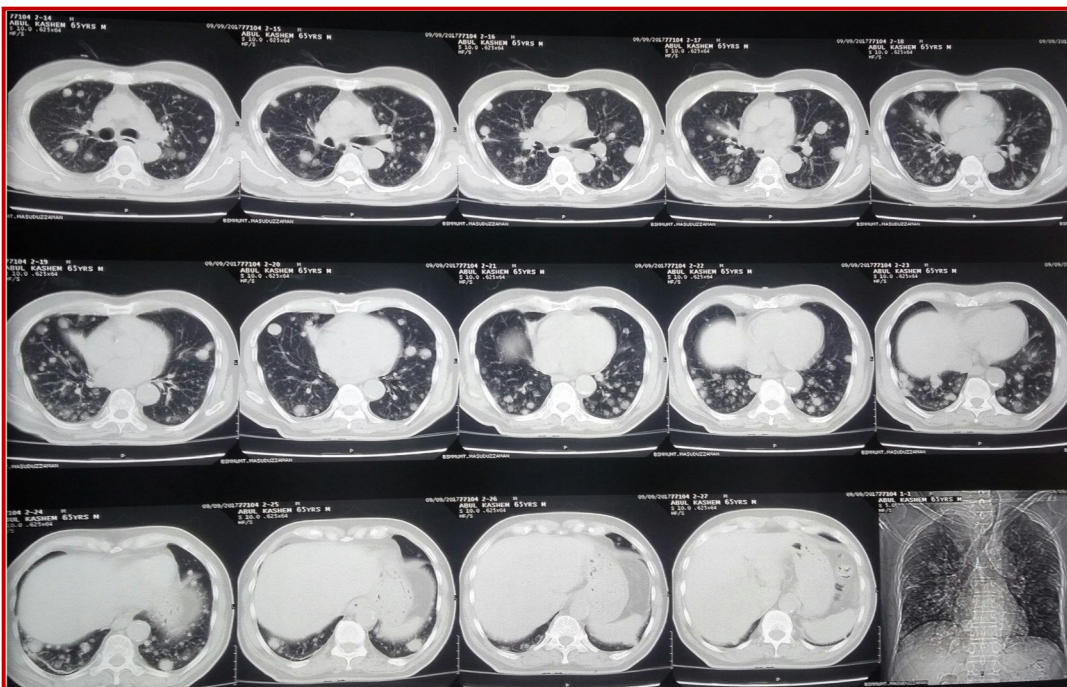


Figure 2: CT scan of chest showing bilateral lung nodules

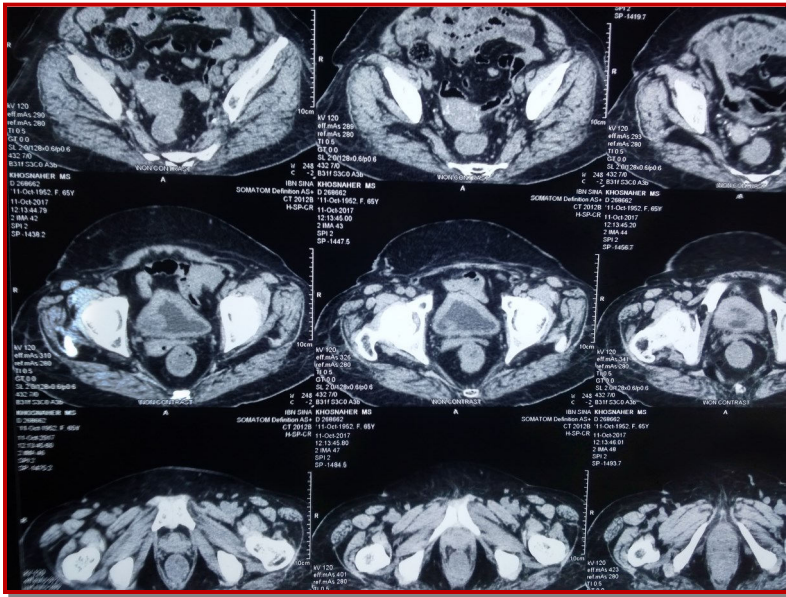


Figure 3: Soft tissue mass at postero-right lateral wall of urinary bladder

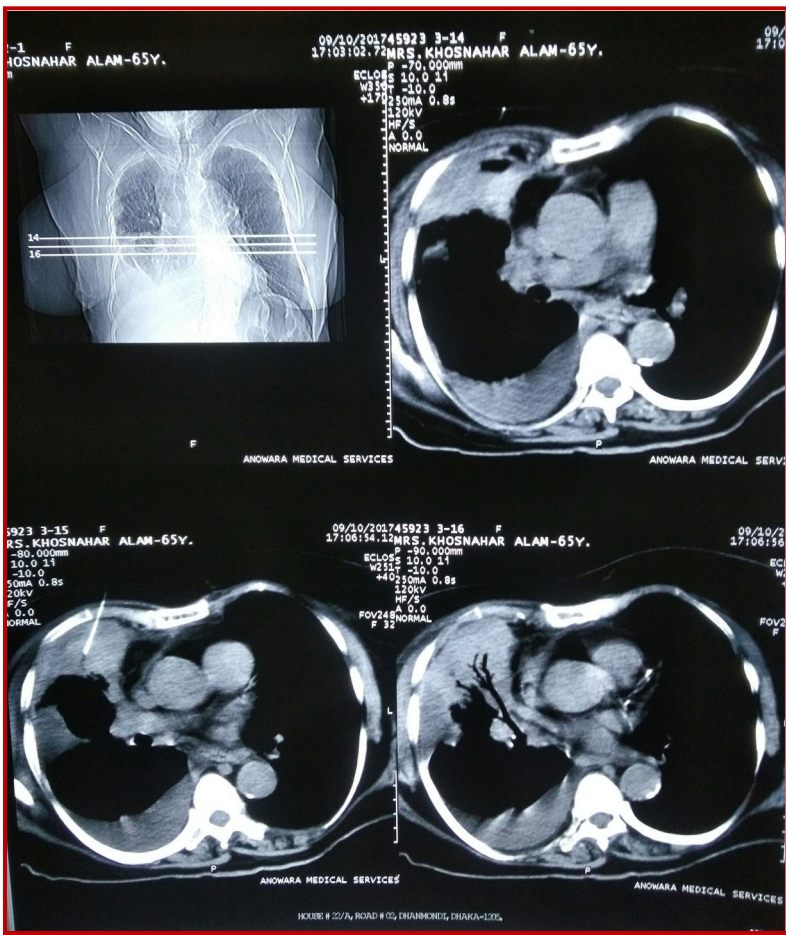


Figure 4: CT guided FNAC from soft tissue mass at right middle lung

condition was gradually deteriorating. He was shifted under Palliative Medicine care and the battle against cancer came to an end on 22nd September, 2017.

Case 2

The second case refers to a 65 year old woman, with a past medical history of hypertension and diabetes, presented in September 2017 with the progressive shortness of breath, right-sided chest pain, and occasional fever. After proper evaluation, she was diagnosed as having urinary bladder neoplasm evident from the USG of the whole abdomen and post-contrast CT scan of the whole abdomen (Figure 3) and right-sided pleural effusion. Though on repeated query, she denied any history which could be matched with the urinary bladder mass. Tube thoracostomy was done which drained hemorrhagic pleural fluid and pleural fluid study along with pleural biopsy was sent for further assessment.

Pleural fluid analysis revealed metastatic adenocarcinoma compatible with lung primary.

A multidisciplinary approach was then offered to the patient and her family involving chest physician, medical oncologist and urologist. Meanwhile, CT guided FNAC from the right lung mass came as adenocarcinoma (Figure 4). Cystoscopy with transurethral resection of bladder tumor was planned and then performed under sub-arachnoid block and bladder biopsies were taken. Histopathologically, it was confirmed as Grade III transitional cell carcinoma of the urinary bladder.

Shortly after that, the general condition of the patient deteriorated markedly and without getting any further treatment option, she died on October 27, 2017.

Discussion

Over the time, the concept and perception of MPMS have quite changed. The International Association of Cancer Registries and International Agency for Research on Cancer (IACR/IARC) and Surveillance Epidemiology and End Results (SEER) project deliver the two most accepted definitions based on interval period of development of primaries.⁶ The IARC proposes an interval of less than 6 months in case of synchronous and more than 6 months are applicable for metachronous tumors. A 2-month period to distinguish between synchronous and metachronous multiple primaries are recommended according to the SEER database.

For the accurate classification of multiple primaries, each tumor must have distinct entity, each

tumor must exhibit definite features of malignancies and each tumor must not be a metastasis of another.⁷ Tumors of varying histologies but originating from the same anatomical site can be considered multiple.

Schoenberg et al. reported that cancer patients have 1.29 times risk of developing a new malignancy.⁸ Rasmy et al. mentioned that multiple primary malignancies are common, in a study encountered in 3–5% of malignant tumors which are most often secondary, triple tumors occur in only 0.5%, quadruple tumors in 0.3% of malignant tumors.⁹

In this series, the first case is three primary malignant metachronous tumors affecting the thyroid, duodenum and urinary bladder. The most recent event was bilateral lung nodules, but the possibility of lung primary couldn't be ruled out histopathologically due to general debility. The case is worthy mentioning here because clustering of three primary malignancies and 4th one to be either lung primary or secondary from other site is of rare occurrence in a single patient, and, to our knowledge, this combination of three carcinomas appearing in the same patient has not been reported till now. Extensive literature study shows some synchronous and metachronous triple combination of tumors mostly of renal, bladder and prostate origin.¹⁰ As the patient was a smoker (20-pack-year), we could associate this with the only detectable risk factor. Unfortunately, he couldn't go through genetic study to exhibit any concealed genetic mutation and we couldn't correlate this to any treatment related neoplasm or any syndromic case.

The second case was however, a more ill-fated one. It was quite saddening as any direct causal relationship, like- tobacco consumption, occupational exposure or family history couldn't be considered. Moreover, she couldn't be offered any sort of treatment modality in the very brief period of time.

Over the past years, the increasing occurrence of subsequent primaries among the cancer survivors is observed due to a variety of unique factors. The increasing effectiveness of cancer therapies and the improvement of diagnostic tools have led to better survival rates among cancer patients.¹¹ Caucasian ethnicity, diagnosis of index cancer at a relatively early age, overall indolent behavior of tumor, the persistent hormonal and environmental provoking factors, hereditary cancer predisposition and the delayed effect of therapies to promote a second cancer-all are recognized reported factors.¹²

Conclusion

No direct relationship could be detected to be the responsible factor in these two cases.

Acknowledgement

All doctors of Respiratory Medicine Department of Bangabandhu Sheikh Mujib Medical University.

References

1. Cancer facts and figures 2017. American Cancer Society.
2. Koutsopoulos AV, Dambaki K, Datselis G, Giannikaki E, Froudarakis M, Stathopoulos E. A novel combination of multiple primary carcinomas: Urinary bladder transitional cell carcinoma, prostate adenocarcinoma and small cell lung carcinoma. *World J Surg Oncol.* 2005; 3: 51.
3. Testori A, Cioffi U, Simone MD, Bini F, Vaghi A, Lemos AA, et al. Multiple primary synchronous malignant tumors. *BMC Res Notes.* 2015; 8: 730.
4. Coleman MP. Multiple primary malignant neoplasms in England and Wales, 1971-1981. *Yale J Biol Med.* 1986; 59: 517-31.
5. Spratt JS Jr, Hoag MG. Incidence of multiple primary cancers per man-year of follow-up: 20-year review from the Ellis Fischel State Cancer Hospital. *Ann Surg.* 1966; 164: 775-84.
6. Coyte A, Morrison DS, McLoone P. Second primary cancer risk - the impact of applying different definitions of multiple primaries: Results from a retrospective population-based cancer registry study. *BMC Cancer.* 2014; 14: 272.
7. Aydiner A, Karadeniz A, Uygun K, Tas S, Tas F, Disci R, et al. Multiple primary neoplasms at a single institution: Differences between synchronous and metachronous neoplasms. *Am J Clin Oncol.* 2000; 23: 364-70.
8. Schoenberg BS. Multiple primary malignant neoplasms. The Connecticut experience, 1935-1964. *Recent Results Cancer Res.* 1977; 58: 1-173.
9. Rasmy A, Faris M, Saber K. A case report for three different malignancies in one patient. *Cogent Med.* 2015; 2: 992155.
10. Vogt A, Schmid S, Heinimann K, Frick H, Harrmann C, Cerny T, et al. Multiple primary tumors: Challenges and approaches. *ESMO Open.* 2017; 2: e000172.
11. Sakellakis M, Peroukides S, Iconomou G, Boumpoucheropoulos S, Kalofonos H. Multiple primary malignancies: A report of two cases. *Chin J Cancer Res.* 2014; 26: 215-18.
12. Satoh H, Momma T, Saito S, Hirose S. A case of synchronous triple primary carcinomas of the kidney, bladder and prostate. *Hinyokika Kiyo.* 2003; 49: 261-64.