

Effect of ethanol extract of *Trigonella foenum-graecum* on gentamicin-induced nephrotoxicity in rat

Syeda Rubayat Hilmi, Zesmin Fauzia Dewan and A. K. M. Nurul Kabir

Article Info

Department of Pharmacology, Faculty of Basic Science and Paraclinical Science, Bangabandhu Sheikh Mujib Medical University, Shahbag, Dhaka, Bangladesh (SRH, ZFD); Department of Pathology, Faculty of Basic Science and Paraclinical Science, Bangabandhu Sheikh Mujib Medical University, Shahbag, Dhaka, Bangladesh (AKMNK)

For Correspondence:

Syeda Rubayat Hilmi
dr.rubayathilmi@gmail.com

Received: 2 November 2017
Accepted: 12 May 2018
Available Online: 27 May 2018

ISSN: 2224-7750 (Online)
2074-2908 (Print)

DOI: 10.3329/bsmmuj.v11i2.35778

Keywords: Fenugreek; Gentamicin; Nephrotoxicity; *Trigonella foenum-graecum*

Cite this article:

Hilmi SR, Dewan ZF, Kabir AKMN. Effect of ethanol extract of *Trigonella foenum-graecum* on gentamicin-induced nephrotoxicity in rats. Bangabandhu Sheikh Mujib Med Univ J. 2018; 11: 107-111.

Copyright:

The copyright of this article is retained by the author(s) [Attribution CC-BY 4.0]

Available at:

www.banglajol.info

A Journal of Bangabandhu Sheikh Mujib Medical University, Dhaka, Bangladesh

Abstract

The present study was designed to determine the ameliorative effect of ethanol extract of *Trigonella foenum-graecum* in an experimental model of gentamicin-induced nephrotoxic rat. To induce nephrotoxicity, gentamicin was administered (80 mg/kg/day for 7 days) intraperitoneally. The ethanol extract of *T. foenum-graecum* was administered (500 mg/kg/day) orally concomitantly with gentamicin for 21 days and 28 days in different groups. Biochemical indices i.e. serum creatinine and serum urea levels were estimated to determine nephrotoxicity and amelioration of nephrotoxicity in all groups. To determine the status of oxidative stress and lipid peroxidation, the renal cortical reduced glutathione and malondialdehyde levels were estimated. Changes in renal architecture were estimated by histopathology of renal tissues. Statistically significant amelioration was observed in all the biochemical parameters supported by significant improvement of renal cortical histology in *T. foenum-graecum*-treated groups.

Introduction

The aminoglycoside antibiotics are used to treat severe life-threatening infections caused mainly by Gram negative organisms.¹ Gentamicin, an aminoglycoside, has proven its efficacy against many aerobic Gram negative organisms and *Staphylococci*.² The nephrotoxic effect of gentamicin is established which limits its clinical use. Gentamicin is still preferred for its potent bactericidal activity, post-antibiotic effect and low cost.³ Among other aminoglycosides, gentamicin is more widely used despite of its potential to produce acute renal tubular necrosis which is associated with the production of reactive oxygen species which may culminate in renal failure.^{4,5}

Gentamicin is a well-known research tool for the induction of nephrotoxicity (acute renal failure). Increased oxidative stress leading to macrophage infiltration, protein oxidation and lipid peroxidation cause tubulointerstitial nephritis, renal tubular necrosis, decrease glomerular filtration rate and ultimately may culminate in producing nephrotoxicity. Studies report that gentamicin-induced acute renal failure is usually characterized by tubular necrosis primarily in proximal convoluted tubules which is associated with cellular desquamation, tubular obstruction and parenchymal degeneration which may lead to gross nephrotoxicity.³

From immemorial time, physicians have been utilizing plant in preparing diversified medicines to cure different diseases. One such plant is *Trigonella foenum-graecum* (fenugreek), locally known as 'methi' by the rural people of Bangladesh and also to countries around. *T. foenum-graecum* is an annual plant of the family Fabaceae. *T. foenum-graecum* exhibits its health benefits and potential medicinal properties in various indications and has little or no adverse effect which further enhances its therapeutic and nutritional potentials.⁶ *T. foenum-graecum* seed extracts have anti-oxidant property and protects cell from oxidative damage. They scavenges hydroxyl radical (OH⁻) and inhibits hydrogen peroxide-induced lipid peroxidation in mitochondria.⁷ Reports suggest that extract of fenugreek seeds prevents lipid peroxidation and exerts exaggerated anti-oxidant activity.⁸ Among all extracts of *T. foenum-graecum*, the ethanolic extract is reported to show the highest anti-oxidant activity.⁹

Thus, so far it has been explained, it appears that the ethanol extract of *T. foenum-graecum* has anti-oxidant property. As oxidative stress is an important factor in producing gentamicin-induced nephrotoxicity (which leads to acute tubular necrosis). So, it may be assumed that any drug or disease which produces acute tubular necrosis could be prevented by the ethanol extract of *T. foenum-graecum*. The



present study is aimed to investigate the ameliorating effect of above herb on nephrotoxicity.

Materials and Methods

Chemicals and reagents

Gentamicin (80 mg/mL) was obtained from the Opsonin Pharma Ltd. (Bangladesh). The kits for the estimation of serum creatinine and urea were obtained from the Human (Germany). For estimation of GSH level, reduced glutathione was obtained from the Loba Cheme (India). For estimation of MDA, thiobarbituric acid, trichloroacetic acid and 1,1,3,3 tetraethoxypropane (MDA standard) were obtained from the Sigma Aldrich Chemie GmbH (Germany). *T. foenum-graecum* was purchased from the local grocery shop.

Ethanol extract of *T. foenum-graecum*

Two kilogram of *T. foenum-graecum* seeds were cleaned, shed dried and grinded by a grinding machine. The powder (1.2 kg) was suspended in 7.4 L of 70% ethanol for 72 hours. They were filtered and the filtrate was concentrated in a rotary vacuum evaporator. The condensed ethanol extract of 122 g was obtained.

Animals

Adult Long Evans Norwegian rats aged between 8-12 weeks and weighed between 150-250 g were obtained from the animal house of Bangabandhu Sheikh Mujib Medical University. The rats were housed in standard size metallic cages (3 rats/cage) and were allowed to live at room temperature with 12 hours of light/dark schedule in a well-ventilated room. They were fed normal rat diet and given water *ad libitum*. For the purpose of identification, rats were marked with permanent ink daily on different parts of their body surface.

Experimental design

Each group contains eight rats and groupings were done as follows: Group I (C): Distilled water was injected (1 mL/rat/day i.p for seven days) and sacrificed on day 8. This served as the control group. Group II (TFG): Rats received ethanol extract of *T. foenum-graecum* (500 mg/kg/day orally for 14 days) and sacrificed on day 15. Group III (GM): Gentamicin was injected (80 mg/kg/day i.p for seven days) and sacrificed on day 8. Group IVa (GM): Gentamicin was injected (80 mg/kg/day i.p for seven days) and sacrificed day 22. Group IVb (GM + TFG): Concomitant treatment with gentamicin (80 mg/kg/day i.p for seven days) and ethanol extract of *T. foenum-graecum* (500 mg/kg/day orally for 21 days) and sacrificed on day 22. Group Va (GM): Gentamicin was injected (80 mg/kg/day i.p for seven days) and sacrificed on the day 29. Group Vb (GM + TFG): Concomitant treatment

with gentamicin (80 mg/kg/day i.p for seven days) and ethanol extract of *T. foenum-graecum* (500 mg/kg/day orally for 28 days) and sacrificed on day 29.

Biochemical measurements

Serum creatinine¹⁰

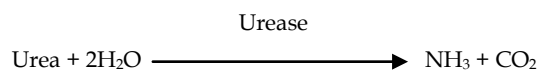
Creatinine forms an orange-red colored complex with picric acid in alkaline solution. The absorbance of this complex is proportional to the creatinine concentration in the sample:

Creatinine + Picric acid → Creatinine picrate complex

The absorbance of creatinine-picrate complex was measured at 492 nm wavelength.

Serum urea¹¹

Urea hydrolyzed in the presence of water and urease to produce ammonia and carbon dioxide.



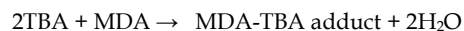In modified Bertholt reaction, the ammonium ions react with hypochlorite and salicylate to form a green dye. Any change in absorbance is proportional to the urea concentration in the sample. The absorbance of urea was measured at 578 nm wavelength.

Renal cortical GSH¹²

Sulfhydryl (SH) group reduces 5,5'-dithiobis-(2-nitrobenzoic acid) to 2-nitro-5-mercaptobenzoic acid which is yellow color. This color can be measured at 412 nm wavelength by a spectrophotometer.

Renal cortical MDA¹³

MDA is formed as a result of lipid peroxidation. It reacts with thiobarbituric acid at 90-100°C temperature and in acidic condition. The reaction yields a pink colored MDA-TBA adduct. The colored complex can be measured by a spectrophotometer using wavelength 532 nm.



Histological procedure

Transverse sections from three levels per kidney of each rat of different groups were taken transversely and placed in the fixing fluid (10% formalin), dehydrated in graded alcohol and embedded in paraffin wax, sectioned at 5 μm thickness and stained with Hematoxylin and Eosin (H & E) stain for light microscopic examination. To evaluate the level of damages, indices such as glomerular atrophy, tubular degeneration and necrosis, accumulation of desquamated cellular debris and cast into tubular lumen, mononuclear inflammatory cell infiltrations were observed. Arbitrary scoring was done as follows:¹⁴ 0 for no detectable lesion, 1 for less than 25% examined field revealed degenerative change (mild), 2 for less than 50% examined

field revealed degenerative change (moderate), 3 for less than 75% examined field revealed degenerative change (severe), and 4 for more than 75% examined field revealed degenerative change (devastating).

Statistical analysis

The results obtained from biochemical and histological findings were expressed as mean \pm SD. Data were analyzed by one-way ANOVA followed by Students unpaired 't' test to determine the significance between the different groups. The difference between groups was considered highly significant at $p < 0.001$, moderately significant at $p < 0.01$ and significant at $p < 0.05$.

Results

The groups of rats injected gentamicin intraperitoneally for 7 days and sacrificed on 8th, 22nd and 29th day showed significant ($p < 0.001$) increase of mean serum creatinine and urea levels while there was significant ($p < 0.001$) reduction of renal cortical glutathione and increase ($p < 0.001$) in malondialdehyde concentration (Figure 1). These suggest

that these rats were made model for nephrotoxicity. This was supported by histological observations of H & E stained transverse section of renal cortex which suggested significant ($p < 0.001$) level of structural damage of renal cortex as evidenced from glomerular atrophy, tubular degeneration, mononuclear inflammatory cell infiltration, presence of desquamated cellular debris and cast in the tubular lumen (Table I; Figure 2). The renal cortical sections of control group of rats showed normal appearance of glomeruli, renal tubules and interstitium.

The ethanol extract of *T. foenum-graecum*-treated nephrotoxic rat groups showed significant ($p < 0.001$) reduction of serum creatinine, urea and significant ($p < 0.001$) elevation of renal cortical glutathione and reduction ($p < 0.001$) of MDA level when compared to the corresponding gentamicin-treated nephrotoxic groups (Figure 1).

Hisopathological observations of the renal cortical architecture of *T. foenum-graecum* supplemented nephrotoxic rat groups had also shown a significant level of recovery when compared to corresponding gentamicin-treated groups (Table I; Figure 2). In only *T. foenum-graecum*-treated group, there was no

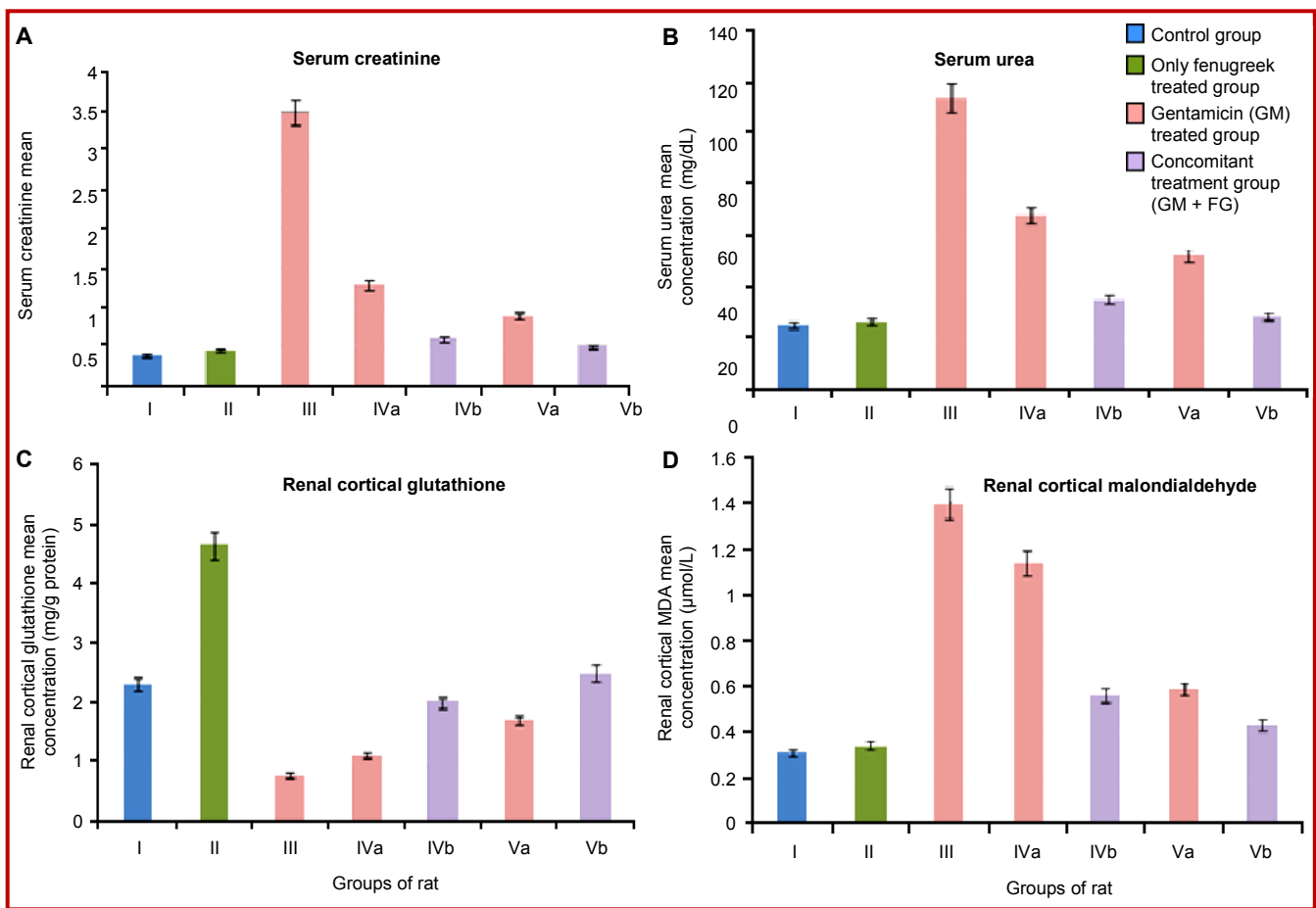


Figure 1: Bar diagram showing the mean concentrations of serum creatinine (A), urea (B), renal cortical glutathione (C) and malondialdehyde (D) levels in different groups of rat

Table I

Histology of renal tissues with qualitative changes and arbitrary score

Histopathological changes	Groups						
	I (C)	II (FG)	III (GM)	IVa (GM)	IVb (GM + FG)	Va (GM)	Vb (GM + FG)
Glomerular atrophy	0.0 ± 0.0	0.0 ± 0.0 ^c	1.3 ± 0.5 ^a	1.0 ± 0.1 ^{ad}	0.5 ± 0.5 ^{af}	0.9 ± 0.3 ^{adg}	0.4 ± 0.5 ^{bjl}
Tubular degeneration	0.0 ± 0.0	0.0 ± 0.0 ^c	2.7 ± 0.5 ^a	2.1 ± 0.3 ^{ad}	1.2 ± 0.3 ^{af}	2.0 ± 0.3 ^{adh}	1.1 ± 0.3 ^{aik}
Debris in the tubular lumen	0.0 ± 0.0	0.0 ± 0.0 ^c	1.5 ± 0.5 ^a	1.3 ± 0.5 ^{ae}	0.5 ± 0.5 ^{af}	1.2 ± 0.5 ^{aih}	0.4 ± 0.5 ^{ajk}
Mononuclear inflammatory cell infiltration	0.0 ± 0.0	0.0 ± 0.0 ^c	1.1 ± 0.3 ^a	0.8 ± 0.4 ^{ad}	0.2 ± 0.4 ^{bf}	0.7 ± 0.5 ^{adf}	0.2 ± 0.4 ^{bik}
Presence of cast in tubular lumen	0.0 ± 0.0	0.0 ± 0.0 ^c	1.5 ± 0.5 ^a	0.5 ± 0.5 ^{ad}	0.3 ± 0.5 ^{af}	0.1 ± 0.3 ^{bdf}	0.0 ± 0.0 ^{cil}

^ap<0.001, ^bp<0.05 and ^cp>0.05, when compared to control (I) group; ^dp<0.001 and ^ep<0.05 when compared to group (III); ^fp<0.001, ^gp<0.05 and ^hp>0.05 when compared to the group (IVa); ⁱp<0.001 and ^jp>0.05, when compared to the group (IVb); ^kp<0.001 and ^lp<0.05, when compared to the group (Va)

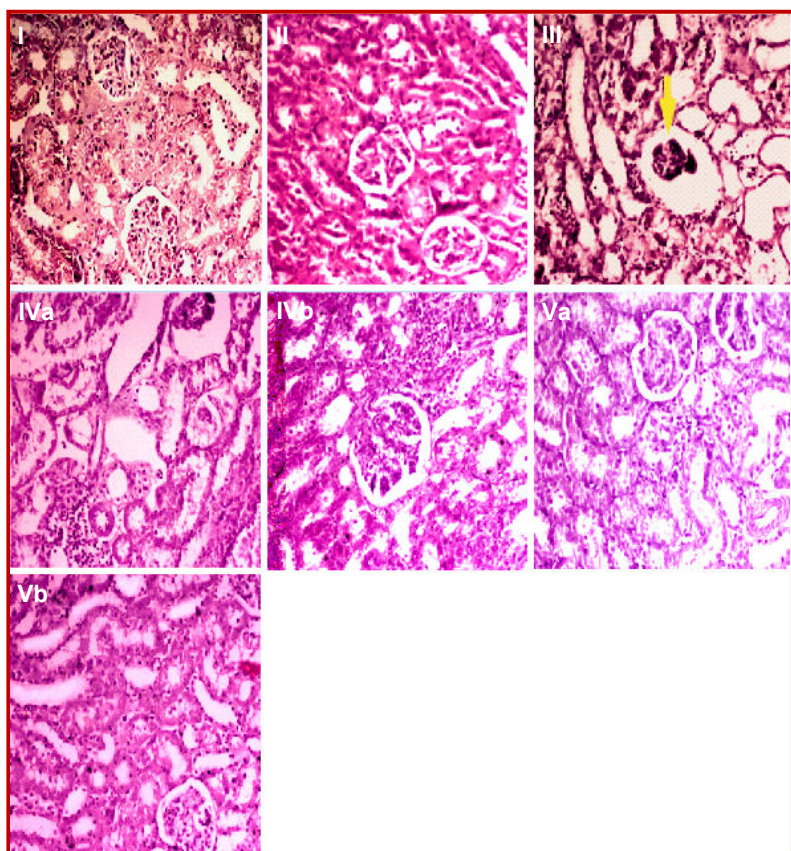


Figure 2: Representative photograph of sections of renal cortex under light microscope of rat treated with distilled water (I); treated with ethanol extract of *T. foenum-graecum* alone (500 mg/kg/day, 14 days) and sacrificed on 15th day (II); treated with gentamicin (80 mg/kg/day for 7 days) sacrificed subsequently on 8th day (III), 22nd day (IVa), 29th day (Va); treated with gentamicin (80 mg/kg/day for 7 days) along with ethanol extract of *T. foenum-graecum* (500 mg/kg/day) subsequently for 21 days and sacrificed on 22nd day (IVb), for 28 days and sacrificed on 29th day (Vb)(H/E, 200x).

significant change in the serum creatinine, serum urea and renal cortical MDA whereas significant

(p<0.001) elevation of renal cortical glutathione level (Figure 1) and the histological observation of the renal cortex showed almost similar renal architecture to those of control group rats (Table I; Figure 2).

Discussion

In the present study, nephrotoxicity was induced by gentamicin which was evident by increase in the serum creatinine, serum urea and renal cortical MDA levels and depletion of renal cortical glutathione level. This was supported by the histology of renal cortex. These biochemical and histological observations were similar to those of Atessahin et al., (2003);¹⁵ and Abdel-Raheem et al., (2010).¹⁴

The ethanol extract of *T. foenum-graecum* possess strong anti-oxidant properties⁹ that is why they were used in the present study to antagonize the oxidative damage to the renal cortex by free radicals during the course of gentamicin administration. Reports about similar ameliorating actions of antioxidants upon gentamicin nephrotoxicity are available.^{15,16}

The results of biochemical and histological observations indicate that the group of rats which were treated with *T. foenum-graecum* showed significant alleviation of toxic effects when compared to those of corresponding gentamicin-treated nephrotoxic groups. These observations appear similar to those of previous works reported by Begum et al. (2006);¹⁶ and Sushma and Devasena, (2010).¹⁷

Here, we also observed that the gentamicin nephrotoxicity in rats have weans in course of time. Similar observation found in previous works done by Begum et al., 2006);¹⁶ Houghton et al., 1976);¹⁸ Gonzalez and Spencer, 1998).⁴ But the corresponding *T. foenum-graecum*-treated groups showed the potentiation of ameliorating effect of nephro-

toxicity.

Like *T. foenum-graecum*, many parts of the plants such as *Ipomoea staphylina*, *Cinnamomum zeylanicum* and *Cestrum nocturnum* show nephroprotective effects.¹⁹⁻²¹

Conclusion

T. foenum-graecum extract may ameliorate the signs of toxic damage to the renal tubules.

References

- Choi JJ, Moffett BS, McDade EJ, Palazzi DL. Altered gentamicin serum concentrations in obese pediatric patients. *Pediatr Infect Dis J*. 2011; 30: 347-49.
 - Zembower TR, Noskin GA, Postelnick MJ, Nguyen C, Peterson LR. The utility of aminoglycosides in an era of emerging drug resistance. *Int J Antimicrob Agents*. 1998; 10: 95-105.
 - Balakumar P, Rohilla A, Thangathirupathi A. Gentamicin-induced nephrotoxicity: Do we have a promising therapeutic approach to blunt it?. *Pharmacol Res*. 2010; 62: 179-86.
 - Gonzalez S, Spencer JP. Aminoglycosides: A practical review. *Am Fam Physician*. 1998; 58: 1811-20.
 - Kandeel M, Abdelaziz I, Elhabashy N, Hegazi H, Tolba Y. Nephrotoxicity and oxidative stress of single large dose or two divided doses of gentamicin in rats. *Pakistan J Biol Sci*. 2011; 4: 627-33.
 - Yadav UC, Baquer NZ. Pharmacological effects of *Trigonella foenum-graecum* L. in health and disease. *Pharm Biol*. 2014; 52: 243-54.
 - Kaviarasan S, Naik GH, Gangabhairathi R, Anuradha CV, Priyadarsini KI. *In vitro* studies on anti-radical and anti-oxidant activities of fenugreek (*Trigonella foenum-graecum*) seeds. *Food Chem*. 2007; 103: 31-37.
 - Thirunavukkarasu V, Anuradha CV, Viswanathan P. Protective effect of fenugreek (*Trigonella foenum-graecum*) seeds in experimental ethanol toxicity. *Phytotherap Res*. 2003; 17: 737-43.
 - Bukhari SB, Bhangar MI, Memon S. Anti-oxidative activity of extracts from fenugreek seeds (*Trigonella foenum-graecum*). *Pakistan J Anal Environ Chem*. 2008; 9: 78-83.
 - Bartel H, Bohmer M. A micromethod for the creatinine assessment. *Int J Clin Chem Diagnostic Lab Med*. 1971; 32: 81-85.
 - Fawcett JK, Scott JE. A rapid and precise method for the determination of urea. *J Clin Pathol*. 1960; 13: 156-59.
 - Seldak J, Lindsay RH. Estimation of total, protein-bound, and nonprotein sulfhydryl groups in tissue with ellman's reagent. *Anal Biochem*. 1968; 25: 192-205.
 - Placer J, Cushman LJ, Johnson CB. Estimation of product of lipid peroxidation (malonyl dialdehyde) in biochemical systems. *Anal Biochem*. 1966; 16: 359-64.
 - Abdel-Raheem IT, El-Sherbiny GA, Taye A. Green tea ameliorates renal oxidative damage induced by gentamicin in rats. *Pakistan J Pharm Sci*. 2010; 23: 21-28.
 - Atessahin A, Karahan I, Yilmaz S, Ceribasi AO, Princi I. The effect of manganese chloride on gentamicin-induced nephrotoxicity in rats. *Pharm Res*. 2003; 48: 637-42.
 - Begum NA, Dewan JF, Nahar N, Mamun MIR. Effect of *n*-hexane extract of *Nigella sativa* on gentamicin-induced nephrotoxicity in rats. *Bangladesh J Pharmacol*. 2006; 1: 16-20.
 - Sushma N, Devasena T. Aqueous extract of *Trigonella foenum-graecum* (fenugreek) prevents cypermethrin-induced hepatotoxicity and nephrotoxicity. *Human Exp Toxicol*. 2010; 29: 311-19.
 - Houghton DC, Hartnett M, Campbell-Boswell M, Porter G, Bennett W. A light and electron microscopic analysis of gentamicin nephrotoxicity in rats. *Am J Pathol*. 1976; 82: 589-612.
 - Bag AK, Mumtaz SF. Hepatoprotective and nephro-protective activity of hydroalcoholic extract of *Ipomoea staphylina* leaves. *Bangladesh J Pharmacol*. 2013; 8: 263-68.
 - Ullah N, Khan MA, Khan T, Ahmad W. Bioactive traditional plant *Cinnamomum zeylanicum* successfully combat against nephrotoxic effects of aminoglycosides. *Bangladesh J Pharmacol*. 2013; 8: 15-21.
 - Saleem U, Ali N, Ahmad B. Protective and curative effects of *Cestrum nocturnum* on rabbit kidney. *Bangladesh J Pharmacol*. 2017; 12: 284-91
-