

## A 24 year old male patient with weakness in the left upper limb

Redoy Ranjan, Mayank Acharya, Heemel Saha, Dharmendra Joshi, Sanjoy Saha and Asit Baran Adhikary

### Article Info

Department of Cardiac Surgery, Faculty of Surgery, Bangabandhu Sheikh Mujib Medical University, Shahbag, Dhaka, Bangladesh

#### For Correspondence:

Redoy Ranjan  
redoy\_ranjan@yahoo.com

Received: 24 May 2018  
Accepted: 11 August 2018  
Available Online: 2 September 2018

ISSN: 2224-7750 (Online)  
2074-2908 (Print)

DOI: 10.3329/bsmmuj.v11i3.37703

**Keywords:** Aortic arch; Aortic dissection; Coarctation of aorta; Limb

#### Cite this article:

Ranjan R, Acharya M, Saha H, Joshi D, Saha S, Adhikary AB. A 24 year old male patient with weakness in the left upper limb. Bangabandhu Sheikh Mujib Med Univ J. 2018; 11: 236-240.

#### Copyright:

The copyright of this article is retained by the author(s) [Attribution CC-BY 4.0]

#### Available at:

www.banglajol.info

A Journal of Bangabandhu Sheikh Mujib Medical University, Dhaka, Bangladesh

### Presentation of Case

*Dr. Redoy:* A 24 year old male attended the outpatient department of a local hospital with the chief complaints of pain in the central chest for two years and easy fatigability of the left upper limb for one and half years. After performing various examinations and investigations, he was sent to Al Helal Specialized Hospital with the preliminary diagnosis of coarctation of the aorta. The pain was dull aching in nature, continuous in duration, mild in intensity mostly, but sometimes intense sharp stabbing, radiating to the back. There was no known aggravating factor but lying down relieved it partially. The pain was not associated with meal, palpitation, cough, fever. The patient also complained of easy fatigability of the left upper limb, which was aggravated by work and relieved by rest. It was not associated with shortness of breaths. The patient also complained of a headache which got aggravated by stress and relieved upon taking rest. He had no history of any chronic illness like diabetes, hypertension, jaundice, bronchial asthma, bleeding dyscrasias and had never undertaken any major surgical procedure.

His general examination revealed otherwise normal finding but for his blood pressure of 140/90 mmHg in the left upper limb, 130/80 mmHg in the right upper limb and radio-femoral, and brachiofemoral delay, and decreased pulse volume in the lower limb. Cardiac examination revealed a systolic murmur in the left infraclavicular area. His other systemic examinations including central nervous system, abdominal and respiratory examinations were normal.

With these complaints, he was further investigated by routine and specific investigations (Table I). All laboratory investigations, ECG, chest X-ray, ECHO and spirometry were performed. His serum creatinine was 1.2 mg/dL. ECHO revealed coarctation of the aorta. Then a magnetic resonance aortography was performed to evaluate and plan the further management (Figure 1).

The patient was admitted with a plan for

surgery. On the basis of history, physical findings and investigations I would like to draw my provisional diagnosis.

### Provisional Diagnosis

Coarctation of aorta

### Differential Diagnosis

*Dr. Redoy:* Coarctation of the aorta<sup>1</sup> is a condition characterized by narrowing in a part of aorta.<sup>2</sup> It is most exclusively congenital,<sup>3</sup> but can also be acquired extremely rarely.<sup>4</sup> Coarctation of aorta comprises 4-8% of congenital heart disease cases.<sup>5</sup> The usual reported incidence is estimated at 0.2-0.3 per 1000 live births.<sup>6-9</sup> It is twice as more common as in males than females.<sup>10</sup> The most common site of coarctation is juxtaductal, while the former classification of coarctation of aorta was based on the location of PDA viz. preductal, ductal and post-ductal.<sup>11,12</sup> Coarctation may be rarely present at other sites eg: abdominal aortic coarctation, either congenitally or acquired.<sup>13</sup>

The underlying pathophysiological mechanism of coarctation of the aorta is probably due to abnormal ductal tissue infiltrating onto the juxtaductal aorta. This contractile ductal tissue upon synchronous contraction during ductal closure results in luminal narrowing.<sup>14</sup>

Poststenotic dilatation and jet lesions of the descending aorta immediately distal to the coarctation segment is usually present.<sup>15,16</sup>

The sign and symptoms of coarctation of the aorta vary according to the age of presentation and constriction of the PDA.<sup>17</sup> Preductal subtype of coarctation is usually becomes symptomatic in the neonatal period and they often have hypoplasia of arch.<sup>11</sup> These patients with unsuspected critical coarctation may have systemic hypoperfusion, metabolic acidosis and congestive heart failure (tachypnea and feeding difficulty). After the closure of ductus, the patients may develop features of end-organ failure (renal dysfunction, hepatic failure,



Table I

## Laboratory data

Variable	Reference range	Finding
Hemoglobin (g/dL)	13-17	14.2
Total count (x10 <sup>3</sup> /μL)	4-11	9
<i>Differential count</i>		
Neutrophil (%)	40-75	67.1
Lymphocyte (%)	20-45	26.8
Monocyte (%)	2-10	4.9
Eosinophil (%)	1-6	1.1
Basophil (%)	<1	0.9
ESR (mm in 1 <sup>st</sup> hour)	0-10	38
ABO		'O' positive
VDRL		Non-reactive
HBsAG		Negative
Anti-HCV		Negative
Anti-HIV		Negative
Bleeding time (min)	2-7	3.3
Clotting time (min)	5-11	6.0
Serum creatinine (mg/dL)	0.7-1.4	1.2
SGPT (U/L)	<40	19
HbA <sub>1c</sub> (%)	<6.1	5.8

¶ Reference values are affected by many variables, including the demographics and the laboratory methods used. The ranges used at the Bangabandhu Sheikh Mujib Medical University Hospital are for adult who do not have medical conditions that could affect the results. They may, therefore, not be appropriate for all patients.

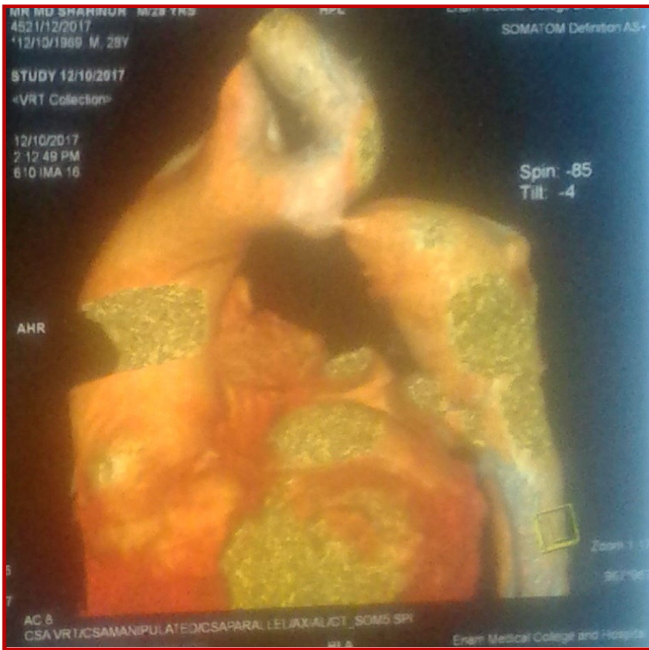


Figure 1: Magnetic resonance aortography of the patient showing coarctation after left subclavian artery

intestinal ischemia and severe metabolic acidosis) due to compromised blood flow to abdominal organ and lower limbs.<sup>17, 18</sup> On physical examination of the patient with coarctation of the aorta may have a difference in peripheral pulse examination with good volume upper limb pulse and weak lower limb pulse as seen in our case. As the symptomatic patient may have murmur or hypertension, headache, angina, exercise intolerance or hypertension not responding to antihypertensive medications are seen in the young adult. Brachiofemoral pulse delay, diminished or absent femoral pulse and difference in blood pressure in upper and lower limbs are commonly seen in all patients.<sup>19</sup>

*Dr. Heemel:* According to ACC/AHA 2008 guidelines (adapted), clinical evaluation and follow-up of coarctation of the aorta in adults should be done (Class I) by checking brachiofemoral pulse difference and ABPI. TEE is recommended for suspected aortic coarctation. Thoracic aorta and intracranial vessels should be evaluated by MRI or CT scan in all patients with coarctation of the aorta.

Class I recommendations for intervention and surgical treatment of coarctation of the aorta in adults depends upon peak to peak coarctation pressure gradient where  $\geq 20$  or  $< 20$  mmHg with radiological evidence of narrowing and collateral flow suggest intervention. Surgical procedure for previously repaired coarctation is recommended if a long segment is involved and there is concomitant aortic arch hyperplasia.

After surgical correction, it is recommended (Class I) to have long-term follow-up, at least once yearly. Post-operative thoracic aortic imaging is advised for assessing aortic dilatation or aneurysm formation. CT/MRI is suggested 5 yearly or less to evaluate repair site of coarctation.<sup>20</sup>

### Dissection of aorta

*Dr. Mayank:* Aortic dissection is a dreadful condition in which pulsatile blood passes in between and separates the aortic media and the adventitia.<sup>21</sup> The length of the lesion may be so variable that it may extend along the proximal or distal and even the whole aorta and its branches.<sup>22</sup> This intimal tear usually develops in the ascending aorta but may also develop in upper descending aorta just beyond the left subclavian artery origin.<sup>23</sup> Dissection of the aorta is classified according to DeBakey or Stanford classification based on the extent of progression of dissection.

Aortic dissection can be catastrophic, and patients may die even before reaching the emergency service or diagnosis is confirmed. An alternative presentation is a hypovolemic shock. It may be a result of recent blood loss or extravasation into periaortic

spaces or due to regurgitation if dissection causes aortic valve shear.<sup>24</sup> Most patients who die acutely are due to false channel rupture causing hemopericardium, hemomediastinum or hemothorax.<sup>25</sup> There is no definite sign or symptom to definitely identify acute aortic dissection. Classic clinical manifestation is a sudden onset of severe tearing or ripping chest pain. The site of pain can indicate the involving area. Neck or jaw pain results when the aortic arch is involved or the lesion is extended into the great vessels. When the anterior arch or aortic root dissection is involved, it results in anterior chest pain and dissection of descending aorta results in intrascapular pain. The chest pain may be mild or no pain in some cases.<sup>26</sup>

#### **Patent ductus arteriosus (PDA)**

*Dr. Dharmendra:* Based on the typical finding of systolic murmur in the left infrascapular area, this could be a case of PDA. PDA is a congenital defect in which the proximal part of the descending aorta is connected to the roof of the main pulmonary artery where the left branch of the pulmonary artery is originated. The ductus is essential for the survival of fetus but the patent ductus beyond the neonatal period is abnormal.<sup>27</sup>

Normally, after birth, the sudden increment of oxygen pressure causes the inhibition of ductal smooth muscle voltage-dependent potassium channels. Calcium enters the cell and the duct is constricted.<sup>28</sup> The placenta along with functioning lungs increase the metabolism of PGE<sub>2</sub> and PGI<sub>2</sub> that eliminates and decreases the level of the prostaglandins. The wall of the ductus is thickened and lumen is obliterated and shortened due to contraction of the medial smooth muscle fibers. Functional closure usually occurs in 24 to 48 hours after birth in term neonates and within the next 2 to 4 weeks, the endothelium is unfolded along with subintimal disruption and proliferation, which results in the permanent seal.<sup>29</sup> The resulting fibrous band with absent lumen is called as ligamentum arteriosum.

#### **Interrupted aortic arch**

*Dr. Heemel:* Absence of luminal continuity between the proximal aorta and the distal aorta is known as an interrupted aortic arch. Fibrous strands that are connecting two widely separated aortic ends are also included in interruption of the aortic arch and not under coarctation of the aorta. The aortic arch morphologically may be interrupted at three sites.<sup>30</sup> Type A is the interruption just distal to the left subclavian, with blood flowing to the descending aorta through the ductus arteriosus. It is seen in 40% of cases. Type B, seen in 55% of cases, is the interruption between the left subclavian and left common carotid arteries. Type C is the interruption located between the left common carotid and left brachiocephalic arteries, which is seen in 5% of cases. In all forms of interruption, the flow is

through the proximal ascending aorta through the ductus arteriosus to the distal descending aorta, except in rare cases when the ductus is absent or closes during fetal life.<sup>31</sup>

---

### **Dr. Mayank's Diagnosis**

---

Coarctation of aorta

---

### **Discussion**

---

*Dr. Heemel:* How will you then proceed with your diagnosis?

*Dr. Redoy:* Generally the provisional diagnosis of coarctation of aorta can be drawn on the basis of physical examination. Differential blood pressure and delay in pulse are pathognomic. The physical findings may be noted are frequently the patients have normal appearance except in cases when coarctation compromises origin of the left subclavian artery in which case the left upper limb may be smaller than the right upper limb. Also, there may be the presence of other associated physical deformities.<sup>19</sup>

Arterial pulses and blood pressure examination of upper and lower limbs may show delayed and diminished pulse and differential blood pressure like delayed brachial to femoral pulses. Typical murmurs and sounds on auscultation may be found like continuous or late systolic murmur may be heard over posterior part of the thoracic spine, aortic ejection sound, bilateral collateral arterial murmurs, early diastolic murmur of aortic regurgitation short mid systolic murmur.<sup>32</sup>

*Dr. Mayank:* What is the relevant anatomy of the region to consider planning for surgery?

*Dr. Dharmendra:* The arch of the aorta and great vessels and the insertion of ductus are the most relevant structures for understanding the coarctation of aorta.<sup>33</sup> As coarctation and interrupted aortic arch can occur anywhere along the arch aortography is essential to identify the emergence of the great vessels and especially ductus arteriosus.<sup>34</sup> The ductus is a remnant of the sixth left aortic arch which connects the aorta with the pulmonary trunk in the fetus. It is connected to the concave undersurface of the aortic arch directly opposite to either the left common carotid or left subclavian artery. The left recurrent laryngeal nerve hooks around the lower border of the ductus arteriosus. So, it may be easily injured during operation if care is not taken. Also due to the coarctation, there is post-stenotic dilatation, and the thoracic vessels may be dilated.<sup>35</sup>

*Dr. Heemel:* What investigative modalities will you choose to confirm your diagnosis?

*Dr. Mayank:* Aortography by CT or MRI can confirm the diagnosis, and other diagnostic modalities like chest X-ray may reveal 'inverted 3 sign'. Thoracic ECHO can and transesophageal ECHO may reveal coarctation site, narrowing dimensions, and pressure gradient determinations.<sup>36</sup>

*Dr. Dharmendra:* What are the treatment plan for this case?

*Dr. Mayank:* After adequate optimization of the patient, any of the following plans can be chosen based on the condition of the patient. Subclavian flap aortoplasty, Resection of the coarcted aorta with an end to end anastomosis, resection followed by an end to end anastomosis with subclavian aortoplasty, patch graft aortoplasty, aortosubclavian bypass, aorto bypass, balloon aortoplasty and stenting.<sup>37</sup>

*Dr. Redoy:* Why do you propose aortosubclavian bypass in this case?

*Dr. Asit:* The subclavian girth was larger, so a prosthetic conduit from subclavian to distal aorta was the best option and compared to all procedures this was the best suited for this patient.

*Dr. Redoy:* Would not there occur any complications, namely steal of blood?

*Dr. Dharmendra:* As the size of the subclavian vessel is large, there will not be any steal of blood by aorta from the subclavian, thus sparing any perfusion related complication from the left upper limb.

*Dr. Heemel:* How to manage this patient intra-operatively from the anesthetic point of view?

*Dr. Sanjoy:* From the anesthetic point of view, just like other cardiovascular system surgeries, we took optimal precaution and planning. The aspects like monitoring, adequate heparinization, acidosis and the other parameters were considered. As a side-biting clamp was used, there is the minimum to no risk of acidosis. In regards to heparinization for prosthetic conduit, it was discussed with surgeon previously during planning. To achieve a target ACT of 300, we used 1-1.5 mg/kg of heparin. For monitoring, we placed an arterial catheter in right as well as left hand. Right hand for pressure monitoring and left to see for occlusion. At the same time, a femoral catheter is ideal to assess distal perfusion.<sup>38-40</sup>

---

## Final Diagnosis

---

Coarctation of aorta

---

## References

---

1. Groenemeijer BE, Bakker A, Slis HW, Waalewijn RA, Heijmen RH. An unexpected finding late after

repair of coarctation of the aorta. Netherlands Heart J. 2008; 16: 260-63.

2. Rajbanshi BG, Joshi D, Pradhan S, Gautam NC, Timala R, Shakya U, Sharma A, Biswakarma G, Sharma J. Primary surgical repair of coarctation of the aorta in adolescents and adults: Intermediate results and consequences of hypertension. Eur J Cardiothorac Surg. 2018; 0: 1-8.
3. Wang R, Sun LZ, Hu XP, Ma WG, Chang Q, Zhu JM, Liu YM, Yu CT. Treatment of complex coarctation and coarctation with cardiac lesions using extra-anatomic aortic bypass. J Vasc Surg. 2010; 51: 1203-08.
4. Nijjar VS, Ali M, Jain N, Jaligam V, Glancy DL. Acquired atheromatous coarctation of the aortic arch In: Baylor University Medical Center Proceedings. 2011; 24: 15-16.
5. Hoffman JI. Congenital heart disease: Incidence and inheritance. Ped Clin N Am J. 1990; 37: 25-43.
6. Ismat FA, Weinberg PM, Rychik J, Karl TR, Fogel MA. Right aortic arch and coarctation: A rare association. J Cong Heart dis. 2006; 1: 217-23.
7. Agarwala BN, Bacha E, Cao QL, Hijazi ZM. Clinical manifestations and diagnosis of coarctation of aorta. Available from: URL: <http://www.uptodate.com/>. Accessed Dec 21, 2011.
8. Strickland MJ, Riehle-Colarusso T, Mahle WT, Correa A. Prevalence of Congenital Heart Defects in Metropolitan Atlanta, 1998-2005. J Obs Gyn Surv. 2009; 64: 156-57.
9. Hoffman JI, Kaplan S. The incidence of congenital heart disease. J Am Coll Card. 2002; 39: 1890-900.
10. Liu F, Huang GY, Liang XC, Sheng F, Lu Y, Wu L, Xu SM, Ning SB. Clinical features of coarctation of aorta: Analysis of 96 cases. Zhong xue zhi. 2006; 86: 1854-56.
11. Cotran R, Kumar V, Fausto N. Robbins Pathologic basis of disease (7th ed.). WB Saunders.
12. Völkl TM, Degenhardt K, Koch A, Simm D, Dörr HG, Singer H. Cardiovascular anomalies in children and young adults with Ullrich-Turner syndrome-the erlangen experience. Clin Card Int Indexed Peer Rev J Adv Trt Card Dis. 2005; 28: 88-92.
13. Rudolph AM, Heymann MA, Spitznas U. Hemodynamic considerations in the development of narrowing of the aorta. Am J Card. 1972; 30: 514-25.
14. Liberman L, Gersony WM, Flynn PA, Lamberti JJ, Cooper RS, Starc TJ. Effectiveness of prostaglandin E 1 in relieving obstruction in coarctation of the aorta without opening the ductus arteriosus. J Ped Car. 2004; 25: 49-52.
15. Wielenga G, Dankmeijer J. Coarctation of the aorta. J Path Bact. 1968; 95: 265-74.
16. Russell GA, Berry PJ, Watterson K, Dhasmana JP, Wisheart JD. Patterns of ductal tissue in coarctation

- of the aorta in the first three months of life. *J Thor Card Surg.* 1991; 102: 596-601.
17. Kabbani N, Kabbani MS, Al Taweel H. Cardiac emergencies in neonates and young infants. *Avicen J Med.* 2017; 7: 1-3.
  18. Johnson JN, Driscoll DJ. Clinical recognition of congestive heart failure in children. Heart failure in the child and young adult: From bench to bedside. 2018; 2: 161-65.
  19. Salahuddin N, Wilson AD, Rao PS. An unusual presentation of coarctation of the aorta in infancy: Role of balloon angioplasty in the critically ill infant. *Am Heart J.* 1991; 122: 1772-75.
  20. Warnes CA, Williams RG, Bashore TM, Child JS, Connolly HM, Dearani JA et al. ACC/AHA 2008 Guidelines for the management of adults with congenital heart disease: A report of the American College of Cardiology/American Heart Association Task Force on Practice Guidelines (writing committee to develop guidelines on the management of adults with congenital heart disease). *J Circ.* 2008; 118: e714-e833.
  21. Cohen R, Mena D, Carbajal-Mendoza R, Arole O, Mejia JO. A case report on asymptomatic ascending aortic dissection. *Int J Angio.* 2008; 17: 155.
  22. Mussa FF, Horton JD, Moridzadeh R, Nicholson J, Trimarchi S, Eagle KA. Acute aortic dissection and intramural hematoma: A systematic review. *JAMA.* 2016; 316: 754-63.
  23. Bahnson HT, Spencer FC. Excision of aneurysm of the ascending aorta with prosthetic replacement during cardiopulmonary bypass. *Ann Surg.* 1960; 151: 879.
  24. White A, Broder J. Acute Aortic Emergencies-Part 1: Aortic Aneurysms. *J Adv Emer Nur.* 2012; 34: 216-29.
  25. Fann JI, Smith JA, Miller DC, Mitchell RS, Moore KA, Grunkemeier G, Stinson EB, Oyer PE, Reitz BA, Shumway NE. Surgical management of aortic dissection during a 30-year period. *J Circ.* 1995; 92: 113-21.
  26. Spittell PC, Spittell JA, Joyce JW, Tajik AJ, Edwards WD, Schaff HV, Stanson AW. Clinical features and differential diagnosis of aortic dissection: Experience with 236 cases (1980 through 1990). In *Mayo Clinic Proceedings*, 1993; 68: 642-51.
  27. Silver MM, Freedom RM, Silver MD, Olley PM. The morphology of the human newborn ductus arteriosus: A reappraisal of its structure and closure with special reference to prostaglandin E1 therapy. *J Hum Path.* 1981; 12: 1123-36.
  28. Leonhardt A, Glaser A, Wegmann M, Schranz D, Seyberth H, Nüsing R. Expression of prostanoid receptors in human ductus arteriosus. *Br J Pharm.* 2003; 138: 655-59.
  29. Fay FS, Cooke PH. Guinea pig ductus arteriosus. II. Irreversible closure after birth. *Am J Phys Legacy Content.* 1972; 222: 841-49.
  30. Sandhu SK, Pettitt TW. Interrupted aortic arch. *J. Curr treat options cardiovas med.* 2002; 4: 337-40.
  31. Kirklin JK, Kouchoukos NT, Blackstone EH and Hanley FL. *Kirklin Barratt-Boyes Cardiac surgery.* 4<sup>th</sup> ed. Philadelphia, Elsevier Saunders, 2013, p 1755.
  32. Swartz MF, Atallah-Yunes N, Meagher C, Schiralli MP, Cholette J, Orie J, Gensini F, Kavey RE, Alfieri GM. Surgical strategy for aortic coarctation repair resulting in physiologic arm and leg blood pressures. *Cong Heart Dis.* 2011; 6: 583-91.
  33. Hutchins GM. Coarctation of the aorta explained as a branch-point of the ductus arteriosus. *Am J Path.* 1971; 63: 203.
  34. Roberts WC. Aortic dissection: Anatomy, consequences, and causes. *Am J Heart.* 1981; 101: 195-214.
  35. Matsui H, Adachi I, Uemura H, Gardiner H, Ho SY. Anatomy of coarctation, hypoplastic and interrupted aortic arch: Relevance to interventional/surgical treatment. *Expert Rev Cardiovas Ther.* 2007; 5: 871-80.
  36. Solinas M, Mengozzi G, De LL, Rossi AM, Masullo M, Giustarini C. Aortic coarctation is correlated with bicuspid aortic valve and intracranial aneurysm: A case report and review of the literature. *J Ital Card.* 2006; 7: 151-54.
  37. Omeje IC, Poruban R, Šagát M, Nosál M, Hraška V. Surgical treatment of aortic coarctation. *Img Ped Card J.* 2004; 6: 18.
  38. Fisher A, Benedict CR. Adult coarctation of the aorta: Anaesthesia and postoperative management. *J Anes.* 1977; 32: 533-38.
  39. Scott HW, Bahnson HT. Evidence for a renal factor in the hypertension of experimental coarctation of the aorta. *J Surg.* 1951; 30: 206-17.
  40. Weiss BM, Garcia E, Turina MI. Reduction and elimination of systemic heparinization during cardiopulmonary bypass. *J Thorac Cardiovasc Surg.* 1992; 103: 790-98.
-