

A 48 year old postmenopausal woman with dull aching lower abdominal pain and heaviness in the abdomen

Sayada Fatema Khatun, Towhida Nazneen and Sabera Khatun

Article Info

Department of Obstetrics and Gynecology, Faculty of Surgery, Bangabandhu Sheikh Mujib Medical University, Shahbag, Dhaka, Bangladesh

For Correspondence:

Sayada Fatema Khatun
sayadafatemakhatun@yahoo.com

Received: 18 June 2018
Accepted: 30 July 2018
Available Online: 2 September 2018

ISSN: 2224-7750 (Online)
2074-2908 (Print)

DOI: 10.3329/bsmmuj.v11i3.37801

Keywords: Cotyledonoid dissecting leiomyoma; Postmenopause; Ovarian tumor

Cite this article:

Khatun SF, Nazneen T, Khatun S. A 48 year old postmenopausal woman with dull aching lower abdominal pain and heaviness in the abdomen. Bangabandhu Sheikh Mujib Med Univ J. 2018; 11: 241-245.

Copyright:

The copyright of this article is retained by the author(s) [Attribution CC-BY 4.0]

Available at:

www.banglajol.info

A Journal of Bangabandhu Sheikh Mujib Medical University, Dhaka, Bangladesh



Presentation of Case

Dr. Towhida Nazneen: A 48 year old postmenopausal lady, para-6 (alive) came to the outpatient department as a diagnosed case of ovarian tumor with history of incomplete surgery. The patient was reasonably well two years back, then she developed dull aching lower abdominal pain and heaviness in abdomen.

For that reason, she went to a local doctor and diagnosed as a case of ovarian tumor by ultrasonography. She had laparotomy on 22 May 2016 at Mymensingh private clinic but the tumor was not removed completely due to extensive adhesion. Few tissues were taken and sent for histopathology and found fibroma of ovary. The patient again developed the same type of complaints one year back after operation. She had no family history of ovarian tumor.

On examination, she was mildly anemic and vitally stable. On abdominal examination, a lump was felt, occupying left iliac and left lumbar, part of hypogastric extending up to umbilicus; measuring (15 x 10 cm), solid in consistency, mobile, mildly tender, with irregular margin and nodular surface. There was no ascities and no history of weight loss. On per vaginal examination, the cervix was broad and apparently healthy. Uterus was normal size and deviated to the right. A mass was felt through left and anterior fornix; right fornix was free and other findings correspond to abdominal examination.

Examination of the cardiovascular, respiratory and other systems revealed no abnormality. Complete blood count, tumor markers such as CA-125, CEA, CA 19-9 were within normal range.

Report of ultrasonography of the whole abdomen was a large complex mass (predominant solid) occupying almost the whole abdominal cavity and could not be separated from the uterus, most likely left ovarian origin with bulky nonhomogeneous uterus. The spiral CT scan of the whole abdomen showed a large

abdominopelvic calcified mass, left ovarian in origin with bulky uterus.

Magnetic resonance imaging (MRI) of the whole abdomen revealed a pelvic mass (Figure 1), measuring (4 x 10 x 8 cm), situated in the left posterolateral uterine wall with extension to the pelvic cavity.

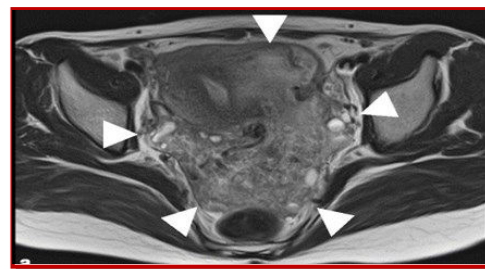


Figure 1: Magnetic resonance imaging shows a pelvic mass, located in the left posterolateral myometrial wall, with extrauterine extension to the pelvic cavity

Intravenous urography (IVU) was normal. After evaluating the clinical data, physical findings and investigations results, the case was provisionally diagnosed.

Provisional Diagnosis

Ovarian tumor

Differential Diagnosis

Dr. Fatema: The patient presented with a history of incomplete surgery due to extensive adhesion of tumor mass in the abdomen and her tumor markers were within normal range. So, there may be a differential diagnosis of leiomyomatosis peritonealis disseminata and peritoneal carcinomatosis.

Leiomyomatosis peritonealis disseminate

This is a rare condition characterized by the presence of smooth muscle nodules across the peritoneum and abdominal organs.¹ The possible causes of this are hormonal (exogenous and endogenous female gonadal steroids),²⁻⁴ sub-

Table I

Laboratory findings

| Parameters | Patient | Reference value |
|--|---------|-----------------|
| Hemoglobin (g/dL) | 12.8 | 13.5 |
| Erythrocyte sedimentation rate (mm/1st hour) | 30 | 0-10 |
| Random blood sugar (mmol/L) | 4.7 | <7.8 |
| Platelet (x10 ⁹ /L) | 230 | 150-400 |
| WBC (x10 ⁹ /L) | 9.8 | 4-10 |
| Neutrophil (%) | 60 | 40-80 |
| Lymphocyte (%) | 30 | 20-40 |
| Monocyte (%) | 3 | 2-10 |
| Tumor marker: | | |
| Ca125 (U/mL) | 23.2 | <35 |
| Carcinoembryonic antigen (ng/mL) | 3.2 | <5 |
| Ca19-9 (U/mL) | 15.9 | <37 |

peritoneal mesenchymal stem cells metaplasia or genetic. This can only be confirmed by a biopsy of the nodule which generally demonstrates a benign smooth muscle cells with no atypia.⁵⁻⁸

Peritoneal carcinomatosis

Peritoneal carcinomatosis is intraperitoneal dissemination of any tumor but it is not originated from the peritoneum itself. One of the important causes of peritoneal carcinomatosis is the ovarian tumor (46%). So, the primary site of this disease should be evaluated. CT scan can detect either primary or secondary peritoneal tumor.⁹ Typically, the patient has associated weight loss, ascites, and rapid progression of the disease.

Dr. Sabera Khatun: As the MRI report reveals that the mass has extended from the myometrium of uterus into the pelvic cavity, other differential diagnosis may be cotyledonoid dissecting leiomyoma, uterine leiomyosarcomas, endometrial stromal sarcoma, intravenous leiomyomatosis. Histopathology and immunohistochemistry markers help to differentiate the diagnosis.

Cotyledonoid dissecting leiomyoma

cotyledonoid dissecting leiomyomas is a rare atypical leiomyoma. It presents clinically and radiologically as an apparent malignant growth. Usually it extends into the upper abdomen from the pelvic cavity. Our patient complaints of lump and heaviness in lower abdomen. Ultrasonography shows the lump most likely adnexal origin. The patient had a history of incomplete surgery due to extensive adhesion. Ca125 is normal. MRI of this patient showed that the mass arise from the left lateral side of uterus into the abdomen from the pelvic cavity.

Frozen section was negative for malignancy.

Uterine leiomyosarcomas

In this case, the clinical features indicate it may be a case of uterine leiomyosarcomas. But this tumor grows and spreads quickly. The diagnosis is confirmed by histopathological analysis.

Endometrial stromal sarcoma

Endometrial stromal sarcoma is a rare cancer of the uterus. It is mostly seen in the premenopausal women and the age range is 42 to 53 years. The patient mainly presents with the abnormal uterine bleeding and the uterine enlargement may be present. There may be a history of taking tamoxifen tablet or history of radiation of the uterus or pelvic area. Our patient has no such history of abnormal uterine bleeding or uterine enlargement or history of such chemo- or radio-therapy.

Intravenous leiomyomatosis is the rarely reported leiomyoma that is characterized by the vascular invasion into the uterine and parametrial veins, with rare extension into the systemic veins and cardia.¹⁰ The typical gross appearance of intravenous leiomyomatosis is multiple nodules protruding into the broad ligament. These features were not present in this case.

Dr. Towhida's Diagnosis

Cotyledonoid dissecting leiomyoma of the uterus

Discussion

Dr. Towhida: William Sternberg originally studied the tumor as "a red seaweed lesion". So, cotyledonoid dissecting leiomyomatosis is also termed as Sternberg tumor. In 1996, cotyledonoid dissecting leiomyomas was first described by Roth et al.¹¹ which is a rare atypical leiomyoma. It may be clinically a malignant growth. In 2003, this disease was included in the WHO classification of tumors of female reproductive organs.¹²

The age distribution of cotyledonoid dissecting leiomyomas ranges from 23 to 73 years (mean, 40.3 years).¹³ It has no typical clinical symptoms. The majority of patients present with palpable abdominal masses and abnormal uterine bleeding. Gynecological examinations reveal a palpable pelvic mass that may be detected by ultrasound scan of uterus corpus or adnexal origin. It usually extends to abdominal cavity from the pelvic cavity, adnexal organs, surfaces of the uterine cervix, bladder and broad ligaments, retroperitoneum as in this case. No tumor marker is increased in this disease.¹⁴⁻¹⁵

Macroscopically, in case of cotyledonoid dissecting

leiomyomas, the myometrium of the lateral side of the uterus and the cornua are thinner compared to the normal myometrium. It enables the tumor to protrude from the uterus into the pelvic cavity. The extrauterine component exhibits exophytic, lobulated, congested, reddish placenta-like mass (Figure 2). In the majority of cases, the extrauterine component of the cotyledonoid dissecting leiomyomas gets attachment to the posterolateral uterine myometrium or cornua with a narrow fundus or soft fibrous vascular pedicle.¹⁶

The tumor usually extends but does not invade the surrounding organs.

Dr. Fatema: The diagnosis is confirmed by the histological findings (Figure 2). Histologically it is composed of fascicles and nodules of bland smooth muscle cells, prominent hydropic degeneration and exhibit increased vascularity. Nuclear atypia, increased mitotic activity and necrosis, are absent.¹⁷

Immunohistochemical study confirmed the smooth muscle nature of the tumor.¹⁸

Dr. Towhida: Surgery is the best treatment for cotyledonoid dissecting leiomyomas. Frozen section is mandatory due to the bizarre appearance of the lesion during operation to avoid overtreatment. According to the age, the desire for fertility of the patient, and the involvement of the disease, the following surgical methods are considered, at present.¹⁹⁻²⁴ For patients of a reproductive age that may or may not desire children, a myomectomy with removal of the mass as far as possible is appropriate.²⁵ For older patients a total abdominal hysterectomy and with or without bilateral salpingo oophorectomy is the best alternative.

Dr. Sabera Khatun: Laparotomy was done which was followed by total abdominal hysterectomy and bilateral salpingo oophorectomy with removal of

the pelvic tumor as far as possible.

Operative Findings

There was presence of ugly looking placenta like tissue covering the entire pelvic and abdominal cavity (Figure 2). Biopsy from the growth was taken and sent for frozen section which revealed negative for malignancy. Large soft solid mass, irregular surface arising from the left cornua of uterus extend up to epigastric region and covering the whole abdominal cavity. The mass was highly vascular and adhered to the surrounding tissue, There was no ascitis. The uterus was 18 weeks size and bicornuate. Both sided ovaries and fallopian tubes were normal. The mass seemed to be arise from the left sided cornue of the uterus. The small gut was compressed and pushed upwards by the ugly looking placenta like tissue.

Histopathological Findings

The section made from the nodules of uterine wall and extrauterine mass showed a benign tumor composed of bundles of smooth muscle which were arranged in fascicles and whorled pattern. The tumor was protruded through the uterine wall. No malignancy was seen. Adenomyosis was also present in the uterus. The histopathology findings suggested cotyledonoid dissecting leiomyoma of uterus.

Dr. Nusrat: Why it is called cotyledonoid dissecting leiomyomas?

Dr. Fatema: The disease usually dissects the muscle fibers of uterus. They arise from the subserosal myometrium of uterus especially the uterine cornua

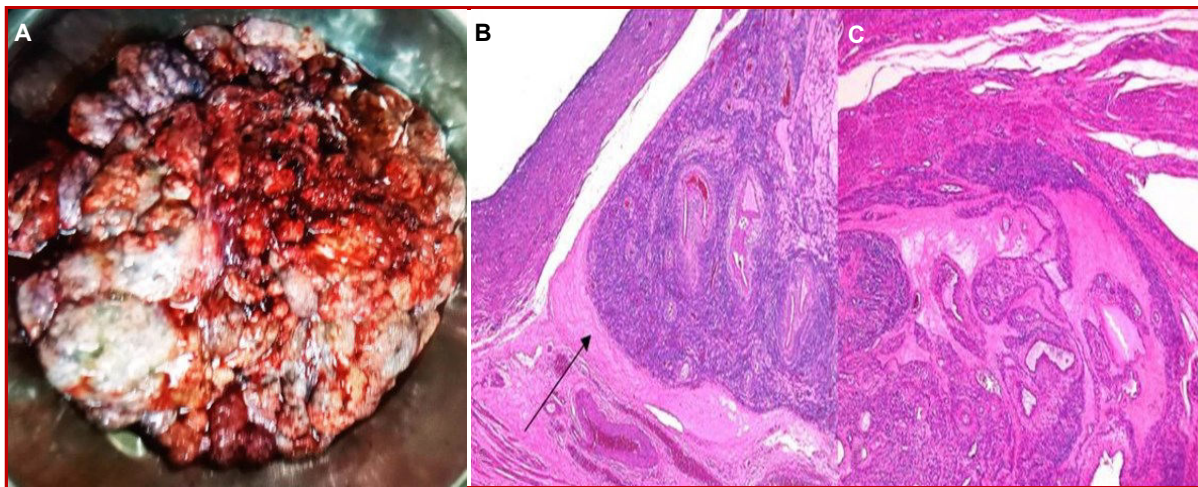


Figure 2: Exophytic, lobulated, congested, reddish cauliflower placenta like mass was removed (A); Bundles of smooth muscle arranged in fascicles and whorled pattern (black arrow) at the cornua (B); Hydropic degeneration was seen. Nuclear atypia, increased mitotic activity and necrosis were absent (C)

and extends into the broad ligament and pelvic cavity. The name "cotyledonoid" leiomyoma originated is due to gross morphology of this mass such as dark red, spongy, bulbous (cotyledonoid) protuberances like placenta.

Dr. Nipa: What is the prognosis of cotyledonoid dissecting leiomyomas of uterus?

Dr. Towhida: Cotyledonoid dissecting leiomyomas of uterus is a benign tumor. So, the prognosis is generally excellent in a majority of cases. The prognosis depends on the surgical resectability of the tumor and involvement of the vital organs.

Dr. Tithi: What is the recurrence rate of cotyledonoid dissecting leiomyomas?

Dr. Towhida: In this lesion, no malignant behavior or recurrence has been described even follow-up up to 41 years.²

Dr. Sabera Khatun: How will you do the final diagnosis of this patient?

Dr. Towhida: The diagnosis and management of cotyledonoid dissecting leiomyomas are difficult because of its malignant like bizarre gross appearance. So, the histopathological guideline and immunohistochemistry are needed for the final diagnosis.

Dr. Asma: Which one is better for the diagnosis of cotyledonoid dissecting leiomyomas of uterus, either by MRI or by CT scan of the whole abdomen?

Dr. Fatema: MRI is better. MRI shows soft tissue shadow better. Here, the MRI report reveals that the mass has extended from the left posterolateral side of uterus with the pelvic extension of mass. It correlates with our operative finding.

Final Diagnosis

Cotyledonoid dissecting leiomyoma of uterus

References

- Quade BJ, McLachlin CM, Soto-Wright V, Zuckerman J, Mutter GL, Morton CC. Disseminated peritoneal leiomyomatosis: Clonality analysis by X chromosome inactivation and cytogenetics of a clinically benign smooth muscle proliferation. *Am J Pathol.* 1997; 150: 2153-66.
- Drake A, Dhundee J, Buckley CH, Woolas R. Disseminated leiomyomatosis peritonealis in association with oestrogen-secreting ovarian fibrothecoma. *BJOG.* 2001; 108: 661-64.
- Surmacki P, Sporny S, Tosiak A, Lasota J. Disseminated peritoneal leiomyomatosis coexisting with leiomyoma of the uterine body. *Arch Gynecol Obstet.* 2006; 273: 301-03.
- Ramesh L, Edozien L. Not all disseminated intra-abdominal lesions are malignant: A case of leiomyomatosis peritonealis disseminata. *J Obstet Gynaecol.* 2005; 25: 409.
- Al-Talib A, Tulandi T. Pathophysiology and possible iatrogenic cause of leiomyomatosis peritonealis disseminata. *Gynecol Obstet Invest.* 2010; 69: 239-44.
- Minassian SS, Frangipane W, Polin JI, Ellis M. Leiomyomatosis peritonealis disseminata. *J Reprod Med.* 1986; 31: 997-1000.
- Nguyen GK. Disseminated leiomyomatosis peritonealis: Report of a case in a postmenopausal woman. *Can J Surg.* 1993; 36: 46-48.
- Demir MK. Disseminated peritoneal leiomyomatosis: Magnetic resonance imaging and differential diagnosis. *Aust Radiol.* 2007; 51: B268-71.
- Singh S, Devi YS, Bhalothia S, Gunasekaran V. Peritoneal carcinomatosis: Pictorial review of computed tomography findings. *Int J Adv Res.* 2016; 4: 735-48.
- Raga F, Sanz-Cortés M, Casañ EM, Burgues O, Bonilla-Musoles F. Cotyledonoid dissecting leiomyoma of the uterus. *Fertil Steril.* 2009; 91: 1269-70.
- Roth LM, Reed RJ, Sternberg WH. Cotyledonoid dissecting leiomyoma of the uterus: The Sternberg tumor. *Am J Surg Pathol.* 1996; 20: 1455-61.
- Tavassoli F, Devilee P. Pathology and Genetics of Tumours of the Breast and Female Genital Organs. IARC Press; Lyon: 2003. World Health Organization Classification of Tumours, p 241.
- Ersöz S, Turgutalp H, Mungan S, Güvendı G, Güven S. Cotyledonoid leiomyoma of uterus: A case report. *Turk Patoloji Derg.* 2011; 27: 257-60.
- Smith CC, Gold MA, Wile G, Fadare O. Cotyledonoid dissecting leiomyoma of the uterus: A review of clinical, pathological and radiological features. *Int J Surg Pathol.* 2012; 20: 330-41.
- Makharoblidze E, Goishvili N, Mchedlishvili M, Khakhutaishvili I, Jangavadze M. Unusual types of smooth muscle tumors of uterine corpus: Case reports and literature review. *Georgian Med News.* 2013; 216: 7-11.
- Majd Soleymani H, Ismail L, Desai SA, Reginald PW. Epithelioid cotyledonoid dissecting leiomyoma: A case report and review of the literature. *Arch Gynecol Obstet.* 2011; 283: 771-74.
- Kim MJ, Park YK, Cho JH. Cotyledonoid dissecting leiomyoma of the uterus: A case report and review of the literature. *J Korean Med Sci.* 2002; 17: 840-44.
- Bas S, Selcuk I. Cotyledonoid myoma: A distinct entity and a diagnostic dilemma in gynecology. *J Cases Obstet Gynecol.* 2015; 2: 91-93.
- Tanaka H, Toriyabe K, Senda T, Sakakura Y, Yoshida K, Asakura T, Taniguchi H, Nagao K. Cotyledonoid dissecting leiomyoma treated by

- laparoscopic surgery: A case report. *Asian J Endosc Surg.* 2013; 6: 122-25.
20. Kim NR, Park CY, Cho HY. Cotyledonoid dissecting leiomyoma of the uterus with intravascular luminal growth: A case study. *Korean J Pathol.* 2013; 47: 477-80.
21. Chávez Martínez S, Arias González ML, Silva López RM, Villagrán Uribe JA. Cotyledonoid dissecting leiomyoma of the uterus. A malignant-looking benign tumor. *Ginecol Obstet Mex.* 2012; 80: 528-33.
22. Gezginç K, Yazici F, Selimoğlu R, Tavli L. Cotyledonoid dissecting leiomyoma of the uterus with intravascular growth in postmenopausal woman: A case presentation. *Int J Clin Oncol.* 2011; 16: 701-04.
23. Majd HS, Ismail L, Desai SA, Reginald PW. Epithelioid cotyledonoid dissecting leiomyoma: A case report and review of the literature. *Arch Gynecol Obstet Arch.* 2011; 283: 771-74.
24. Weissferdt A, Maheshwari MB, Downey GP. Cotyledonoid dissecting leiomyoma of the uterus: A case report. *Diagn Pathol.* 2007; 2: 18.
25. Saeki H, Suzuki C, Yamasaki S, Hashizume A, Izumi H, Suzuki F, Ishi K, Nojima M, Hino O. Cotyledonoid dissecting leiomyoma of the uterus: Report of two cases. *Arch Gynecol Obstet.* 2015; 291: 357-61.
-