

A 60-year-old diabetic patient presented with post coronary artery bypass grafting status with persistent pain and stiffness of left shoulder joint

Md. Mahbubul Islam, Sheikh Muhammad Bin Faruque, Md. Nuruzzaman Khandaker and Redoy Ranjan

Article Info

Department of Physical Medicine and Rehabilitation, Faculty of Medicine, Bangabandhu Sheikh Mujib Medical University, Shahbag, Dhaka, Bangladesh (MMI, MNK); Department of Cardiac Surgery, Faculty of Surgery, Bangabandhu Sheikh Mujib Medical University, Shahbag, Dhaka, Bangladesh (SMBF, RR)

For Correspondence:

Redoy Ranjan
redoy_ranjan@bsmmu.edu.bd

Received: 25 January 2020
Accepted: 22 May 2020
Available Online: 17 June 2020

ISSN: 2224-7750 (Online)
2074-2908 (Print)

DOI: 10.3329/bsmmuj.v13i2.47601

Cite this article:

Islam MM, Faruque SMB, Khandaker MN, Ranjan R. A 60-year-old diabetic patient presented with post coronary artery bypass grafting status with persistent pain and stiffness of left shoulder joint. *Bangabandhu Sheikh Mujib Med Univ J.* 2020; 13: 63-67.

Copyright:

The copyright of this article is retained by the author(s) [Attribution CC-BY 4.0]

Available at:

www.banglajol.info

A Journal of Bangabandhu Sheikh Mujib Medical University, Dhaka, Bangladesh

Presentation of Case

Dr. Md. Mahbubul Islam (MD Resident): A 60-year-old diabetic male patient presented with persistent left shoulder joint pain for the last 6 months following coronary artery bypass graft (CABG) surgery. The pain was insidious onset, non-radiating, and dull which aggravated by movement as well as on left lateral position during sleep. However, the pain was not associated with morning stiffness. He had been treated with oral anti-diabetic medications for diabetes mellitus for the last 15 years. However, recently he required to switch to premixed insulin injection for good control of his glycemic status. Apart from post CABG status and diabetes mellitus, he was relatively well and had no other significant medical records like direct trauma over the shoulder joint. General examinations revealed normal findings except his pale complexion with moderate anemia. Moreover, cardiovascular system examinations revealed normal findings like pulse was 70 beats/min (regular), and blood pressure was 140/80 mmHg. Examination of the musculoskeletal system revealed normal gait but restricted shoulder movement in all directions on the Apley's screening test, and wasting of shoulder girdle muscle especially in supraspinatus, infraspinatus, and deltoid muscle. Moreover, the passive range of motion of the shoulder joint was also markedly limited and painful. Examination of the cervical spine as well as other systemic examinations demonstrated normal physiological findings.

Furthermore, after careful physical examinations, he was also evaluated with hematological, biochemical as well as radiological investigations (Table I). Hematological investigations demonstrated normal hemoglobin and erythrocyte sedimentation rate. Thyroid function tests and fasting lipid profiles were within normal limits. Biochemical investigations demonstrated elevated fasting as well as 2 hours after breakfast blood sugar level. Imaging report illustrated normal X-ray findings of the left shoulder joint (Figure 1), but presence of pathological Q and T inversion wave in II, III

and aVF lead of electrocardiogram. Furthermore, 2D and M-mode echocardiography revealed left ventricular dysfunction with regional wall motion abnormality, and left ventricular ejection fraction was 38%.

Based on the history, physical examinations, and investigation findings, we would like to draw a provisional diagnosis.

Provisional Diagnosis

Post CABG adhesive capsulitis of the left shoulder joint

Differential Diagnosis

Post-sternotomy pain

Dr. Redoy Ranjan: The pathophysiology of post-sternotomy pain commonly caused by osteomyelitis of the sternum, fracture or incomplete healing of the bone, sternocostal chondritis, costal fracture, injury to the brachial plexus and entrapment of the nerves due to sternal wire sutures.^{1,2} Hypersensitivity reaction against the metal wire is also another cause of post-sternotomy pain. Perhaps, the harvesting of internal mammary artery would increase the risk of chronic post-sternotomy pain. Typical criteria of post-sternotomy pain include pricking, aching, lancinating and allodynic which may cause restriction of movements of either shoulder joints. The clinical examinations of the patient with post-sternotomy pain may be normal except tenderness over the parasternal area and restriction of shoulder movements. Chest X-ray may be normal or may show pleural effusion, pulmonary infiltration, and pericardial effusion.^{2,3}

Post CABG left-sided spinal accessory nerve palsy

Dr. Md. Nuruzzaman Khandaker: Although spinal accessory nerve injury is sometimes a complication of carotid endarterectomy, it may also occur after coronary artery bypass grafting



Table I

Laboratory data

Investigations	Patient	Normal value
<i>Complete blood count</i>		
Red blood cell ($\times 10^{12}/L$)	3.7	4.5-5.4
White blood cell ($\times 10^9/L$)	10.5	4.0-11.0
Neutrophil (%)	72	50-70
Lymphocyte (%)	22	20-40
Monocyte (%)	5	2-8
Eosinophil (%)	1	1-4
Basophil (%)	0	0-4
Platelet ($\times 10^9/L$)	350	150-500
Hemoglobin (g/dL)	11.5	14-17
Erythrocyte sedimentation rate (mm in 1 st hour)	15	0-10
Serum creatinine (mg/dL)	0.6	0.3-1.0
Fasting blood sugar (mmol/L)	7.5	<5.5
2 Hour after breakfast (mmol/L)	9.0	<7.8
HbA1C (%)	8.2	4.0-5.9
<i>Serum lipid profile</i>		
Total cholesterol (mg/dL)	180	150-200
Low-density lipoprotein (mg/dL)	190	50-130
Triglycerides (mg/dL)	140	60-150
<i>Thyroid function test</i>		
FT3 (pmol/L)	3.7	2.8-9.5
FT4 (pmol/L)	14	9.5-25.5
TSH (mIU/L)	1.5	0.5-5.0
Rheumatoid factor (IU/mL)	4.7	0-14

surgery.^{3,4} Clinical features revealed limited arm abduction, winging of scapula, and weakened shoulder shrugging. There is also marked muscular atrophy, especially supraspinatus, infraspinatus, and trapezius muscles with a normal passive range of motion of the shoulder joint. Prolong neck extension accompanied by excessive stretching of the spinal accessory nerve while under anesthesia may have resulted in ischemia and subsequent injury secondary to traction. Typically, X-ray of the shoulder joint reveals normal findings and nerve conduction study of the spinal accessory nerve demonstrates diminished amplitude to the upper trapezius. Prolong latencies to right upper, middle trapezius and an absent response to lower trapezius are other findings of nerve conduction study. Electromyography of the left upper limb reveals no other abnormalities except in the upper portion of the trapezius muscle, where fibrillation potentials and positive sharp waves are present.^{3,5}

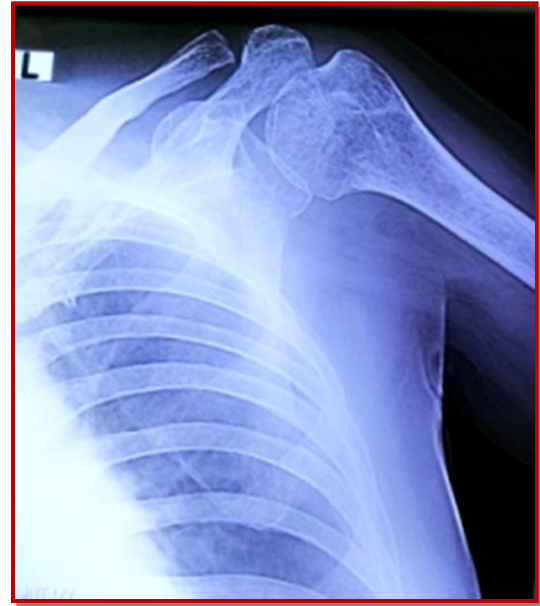

Figure 1: Plain X-ray of left shoulder joint anteroposterior view

Post CABG pain syndrome

Dr. Sheikh Muhammad Bin Faruque: Post CABG pain syndrome is characterized by atypical and chronic pain that restricts daily physical activity and may cause depressive illness. This pain usually occurs in the left anterior chest wall, although post CABG pain can also be located at the midline scar as well as the right chest wall.^{1,2,5} So that, we should consider post CABG pain syndrome as a potential etiology for left shoulder pain following cardiac surgery.

Dr. Islam's Diagnosis

Post CABG adhesive capsulitis of left shoulder joint

Discussion

Dr. Khandaker: Adhesive capsulitis or frozen shoulder is one of the long-term complications of diabetes mellitus. It is presented by stiffness of the joint as well as progressively increasing pain involving the shoulder joint. It takes several months to resolve spontaneously.^{6,7} There is fibroblastic and myofibroblastic proliferation in the rotator interval, anterior capsule and coracohumeral ligament of the shoulder joint. Its diagnosis is clinical. There is a painful restriction (both active range of motion and passive range of motion) of the shoulder joint in the presence of normal X-ray and normal progression of 3 stages that are freezing, frozen and thawing.^{7,11} While the prevalence of adhesive capsulitis is only 2-5% in the general population; but increased incidence about 10%-20% were reported among

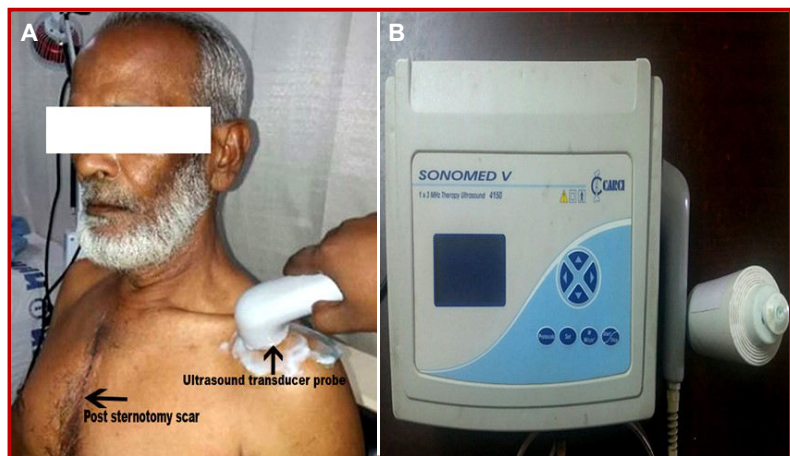


Figure 2: Illustrates application of ultrasound transducer over shoulder joint (A); SONOMED V-4150 ultrasound physiotherapy machine (B)

diabetes mellitus patients.¹⁰⁻¹² Several studies have shown that adhesive capsulitis is caused by glycosylation of the collagen tissues within the shoulder joint which is triggered by the presence of hyperglycemia. Most common medical treatments include NSAIDs (non-steroidal anti-inflammatory drugs), oral corticosteroids or intra-articular glucocorticoid injections and physiotherapy, which has demonstrated adequate pain relief as well as the return of the joint activities.^{6-9, 11}

Dr. Islam: As adhesive capsulitis is considered as self-limiting disease, prognosis following therapeutic management is good. However, patients with symptoms like severe pain as well as functional limitations initially in the disease process have a relatively poor outcome. To prevent the development of adhesive capsulitis, physicians usually recommend maintaining of joint mobility particularly following surgery and trauma. Physiotherapy and regular exercises are the key strategies to prevent the development of adhesive capsulitis especially following cardiac surgery.¹³⁻¹⁵

Dr. Ranjan: How will you evaluate a case of adhesive capsulitis to reach a diagnosis?

Dr. Islam: For diagnosis, we need to achieve proper medical history, physical examinations as well as hematological, biochemical, and radiological investigations profile. History of past medical records like trauma, fever, pain, and medications especially for uncontrolled diabetes mellitus should be evaluated. Examination of the contralateral right shoulder should be performed for any asymmetry or pathological sign. Apley screening test, neck screening, as well as examinations of the precordium should be done to evaluate underlying conditions. Routine hematological, biochemical, and radiological investigations like X-ray, ultrasonogram as well as magnetic resonance imaging (MRI) scan of the left shoulder joint should be performed. However, 12 lead ECG and echocardiography should be

performed to exclude potential cardiac co-morbidities.^{7, 12-16} Regarding this case, there was a history of prolonged immobilization with uncontrolled diabetes mellitus. Furthermore, there was restriction of both active range of motion as well as passive range of motion of the shoulder joint in all directions and Apley screening test indicated diagnosis of the adhesive capsulitis.

Dr. Ranjan: What are the investigations plan to confirm the diagnosis?

Dr. Faruque: We worked up to exclusion of underlying any inflammatory condition as well as to see the glycemic status of the patient. Complete blood count with ESR, C-reactive protein, rheumatoid factor, fasting blood sugar, serum creatinine and HbA1c were carried out. Radiological investigations like an X-ray of the left shoulder joint in both anteroposterior and lateral view, as well as X-ray of the cervical spine in anteroposterior, lateral, and oblique view were performed. Imaging reports help to exclude any local pathology in bones of the shoulder joint or present of osteophyte in the cervical vertebrae and any foraminal encroachment to ping the exiting cervical nerve. Moreover, we should evaluate the shoulder joint by high-resolution musculoskeletal ultrasound machine to exclude any localized pathology like rotator cuff tendinopathy, a partial rupture of rotator cuff tendon and subacromial bursitis.¹⁵⁻¹⁸ Furthermore, ECG and echocardiography should also consider evaluating underlying cardiac conditions like angina. Many studies had been investigating the prevalence of post CABG pain syndrome in connection its onset and pathophysiological mechanism.^{2, 7-10} The mechanism of post CABG pain is believed to be chest wall trauma-induced musculoskeletal nociceptive pain and neuropathic pain from the secondary origin. During harvesting of the internal mammary artery, the anterior branch of the intercostal nerve is most likely to be injured, triggering stepwise central neuropathic pain.^{2, 5, 12}

Dr. Ranjan: How can a physiatrist help the patient for his ailment like a adhesive capsulitis?

Dr. Khandaker: The holistic approach to manage this case is a conservative treatment that includes pharmacological agent, therapeutic exercise, application of physical agents if pain not well controlled then intra-articular steroid injection. Firstly, reassurance and counseling should be done with pharmacological therapy, including non-steroidal anti-inflammatory drugs (NSAID) and opioids, as well as shoulder mobilizing exercises and ultrasound therapy (Figure 2) are the initial modes of management. Moreover, phonophoresis and infra-red radiation (IRR) can also be given as physical therapy. Therapeutic exercise, active and passive range of exercise, Codman pendular exercise, wall climbing, wand exercise, and pulley exercise are key

management plan to improve the joint mobility of the shoulder.^{6, 17-20} Furthermore, adequate management of diabetes mellitus to control blood sugar levels within the physiological limit is very much important in the management of the adhesive capsulitis. It may be suggested that regular post-operative physiotherapy to the upper limbs should be given either self or provided by the physiotherapist. It is helpful to prevent the development of adhesive capsulitis in the immediate postoperative period.⁹⁻¹⁴ Early diagnosis with immediate referral and multi-disciplinary team (MDT) management may prevent further progression of chronic and treatment-resistant adhesive capsulitis. Several research articles observed that early diagnosis of the adhesive capsulitis could be managed by the application of heat to the affected area, giving NSAIDs and intra-articular corticosteroid injections.^{6, 9, 18-21} On the top, physiotherapy as well as stretching exercises can widen the range of the shoulder movement. Regular physiotherapy is associated with a significantly lower risk of developing adhesive capsulitis with 76% of LAM (Lateral rotation, abduction, and medial rotation) score negative participants being in the regular follow-up group.^{2, 8-12, 20}

Dr. Faruque: How does ultrasound therapy work in the shoulder joint?

Dr. Islam: Ultrasound based physiotherapy works by utilizing a deep heating modality which is given as continuous mode, commonly with 1MHz in frequency, 0.8-1 watt/cm² in intensity, and two to three times per week for 10-15 times.²¹ This high-frequency acoustic energy vibration which is >20,000 Hz produces thermal as well as non-thermal physiological effects on human body tissue. A therapeutic beam with a wide-angle of divergence produces by the transducer of ultrasound machine and utilization of therapeutic frequencies depends upon the diameter of the transducer. The World Health Organization recommends limiting spatial average intensity (SAI) to 3 W/cm² and the commonly used therapeutic ultrasound intensities are ranging from 0.1 to 2.5/3 W/cm². The therapeutic wavelength and temperature in deep tissues are about 6 cm and 114. 8°F respectfully and usually persist for 5-10 min in each location to attain the optimal thermal effect of the tissues situated just in the front of the bone.²⁰⁻²³

Dr. Khandaker: What might be the cause of adhesive capsulitis for this patient?

Dr. Faruque: The etiology of the primary frozen shoulder is unknown, but increased occurrence with systemic metabolic disorders. Secondary adhesive capsulitis usually developed following trauma and surgery. However, most common associated factors for adhesive capsulitis are uncontrolled diabetes mellitus, thyroid function disorders, hyperlipidemia, Dupuytren's disease, cardiovascular dis-

eases like hypertension, ischemic heart disease, hemiplegia as well as cardiac surgery. In this case, the cause of adhesive capsulitis was due to prolonged immobilization after cardiac surgery as well as long time uncontrolled diabetes mellitus which was concordance to existing research articles.^{8, 10, 13, 22-25}

Dr. Ranjan: What are the complications we should keep in mind for this patient?

Dr. Islam: As patients remain unable to move his shoulder joint due to pain and joint stiffness, it may be resulting in the development of joint deformities like wasting and atrophy of the muscles. This condition leads to reduce power and loss of performing activities of daily living as well as psychological complications like anxiety and depression. A total of 15% patients develop permanent loss of full range of motion.^{2, 11, 25} Post CABG patients commonly develop shoulder complications like wasting, atrophy of the muscles due to their prolonged immobilization. Psychological complication like depression may develop due to their exposure to intensive care management and long duration of hospital stay. Several prospective studies also have documented about upper limb neurological complications following CABG surgery.^{2, 5, 26, 27}

Follow-up

Pain and stiffness usually resolve spontaneously within 18 months. Advice for follow-up was given in the next 1st, 3rd, 6th, and 12th months to see the improvement of severity of pain as well as range of movement of the joints.^{2, 26-28}

Final Diagnosis

Post CABG adhesive capsulitis of the left shoulder joint

Conflict of Interest

Authors declare no conflict of interest.

References

1. Kalso E, Mennander S, Tasmuth T, Nilsson E. Chronic post-sternotomy pain. Acta Anaesthesiol Scand. 2001; 45: 935-39.
2. Kwon SY, Joo JD, Kim JH, Jeong JT. Sympathetically mediated upper back pain after coronary artery bypass graft surgery. Korean J Anesthesiol. 2013; 65: 135-36.
3. Marini SG, Rook JL, Green RF, Nagler W. Spinal

- accessory nerve palsy: An unusual complication of coronary artery bypass. *Arch Phys Med Rehabil.* 1991; 72: 247-49.
4. Keleş Z, Zinnuroğlu M, Beyazova M. Impairment of upper trapezius branch of the spinal accessory nerve during bypass grafting: A stretch injury? *Muscle Nerve.* 2010; 41: 144-47.
 5. Khan MU, Ahmed I. Role of stellate ganglion block in post CABG sympathetically mediated chest pain. *J Pakistan Med Assoc.* 2007; 57: 470-72.
 6. D'Amato KE, Rogers M. Frozen shoulder: A difficult clinical problem. *Osteopathic Fam Physician.* 2012; 4: 72-80.
 7. Mamun KA, Md Nurullah Husain MA, Mansur F, Alam MS. Adhesive capsulitis of shoulder (frozen shoulder) among the diabetic patients with rheumatic complaints. *Med Today.* 2020; 32: 67-69.
 8. Kelley MJ, McClure PW, Leggin BG. Frozen shoulder: Evidence and a proposed model guiding rehabilitation. *J Orthop Sports Phys Ther.* 2009; 39: 135-48.
 9. Tighe CB, Oakley JW. The prevalence of a diabetic condition and adhesive capsulitis of the shoulder. *South Med J.* 2008; 101: 591-95.
 10. Milgrom C, Novack V, Weil Y, Jaber S, Radeva-Petrova DR, Finestone A. Risk factors for idiopathic frozen shoulder. *Isr Med Assoc J.* 2008; 10: 361-64.
 11. Lewis J. Frozen shoulder contracture syndrome: Aetiology, diagnosis and management. *Man Ther.* 2015; 20: 2-9.
 12. Uppal HS, Evans JP, Smith C. Frozen shoulder: A systematic review of therapeutic options. *World J Orthop.* 2015; 6: 263-68.
 13. Dias R, Cutts S, Massoud S. Frozen shoulder. *BMJ.* 2005; 331: 1453-56.
 14. Chokkalingam M, Saradha S, Navitha A, Nayar PG. Incidence and clinical profile of patients with frozen shoulder after cardiac surgery. *J Clin Prev Cardiol* 2017; 6: 142-46.
 15. Hand C, Clipsham K, Rees JL, Carr AJ. Long-term outcome of frozen shoulder. *J Shoulder Elbow Surg.* 2008; 17: 231-36.
 16. Khan MS, Rahman N, Ferdousi M, Khatoon R, Taher MA. Ultrasonographic findings in patients with shoulder pain. *BIRDEM Med J.* 2019; 9: 218-22.
 17. Li JQ, Tang KL, Wang J, Li QY, Xu HT, Yang HF, Tan LW, Liu KJ, Zhang SX. MRI findings for frozen shoulder evaluation: Is the thickness of the coracohumeral ligament a valuable diagnostic tool?. *PLoS One.* 2011; 6: e28704.
 18. Park GY, Park JH, Kwon DR, Kwon DG, Park J. Do the findings of magnetic resonance imaging, arthrography, and ultrasonography reflect clinical impairment in patients with idiopathic adhesive capsulitis of the shoulder? *Arch Phys Med Rehabil.* 2017; 98: 1995-2001.
 19. Lin HC, Chiang SY, Lee K, Kan YC. An activity recognition model using inertial sensor nodes in a wireless sensor network for frozen shoulder rehabilitation exercises. *Sensors (Basel).* 2015; 15: 2181-204.
 20. Khan MS, Ahmed A, Zaman A, Haque H, Hosain M, Doza A. Pattern of musculo-skeletal disorders in diabetic and non-diabetic patients attending in a tertiary care hospital in Dhaka. *BIRDEM Med J.* 2017; 8: 68-71.
 21. Yan J, Zhang XM. A randomized controlled trial of ultrasound-guided pulsed radiofrequency for patients with frozen shoulder. *Medicine (Baltimore).* 2019; 98: e13917.
 22. Haque S, Rahman MF, Yousuf M, Karim MR, Hasan MK. A comparison of ultrasound therapy and microwave diathermy on patients with adhesive capsulitis of shoulder joint. *JAFMC Bangladesh.* 2019; 11: 30-35.
 23. Barua SK, Alam Z. Phonophoresis in adhesive capsulitis (frozen shoulder). *CMOSHMCJ.* 2014; 13: 60-64.
 24. Manhal S, Sirajudeen MS, Pillai PS, Nair HR, Marla J. Occurrence of shoulder disorders among post-coronary artery bypass surgery patients in India. *Arch Med Health Sci.* 2015; 3: 34-39.
 25. Ebadi S, Forogh B, Fallah E, Babaei Ghazani A. Does ultrasound therapy add to the effects of exercise and mobilization in frozen shoulder? A pilot randomized double-blind clinical trial. *J Bodyw Mov Ther.* 2017; 21: 781-87.
 26. Kivimäki J, Pohjolainen T, Malmivaara A, Kannisto M, Guillaume J, Seitsalo S, Nissinen M. Manipulation under anesthesia with home exercises versus home exercises alone in the treatment of frozen shoulder: A randomized, controlled trial with 125 patients. *J Shoulder Elbow Surg.* 2007; 16: 722-26.
 27. Cho CH, Bae KC, Kim DH. Treatment strategy for frozen shoulder. *Clin Orthop Surg.* 2019; 11: 249-57.
 28. Manske RC, Prohaska D. Diagnosis and management of adhesive capsulitis. *Curr Rev Musculoskelet Med.* 2008; 1: 180-89.
-