

# An Unusual Cause of Rectal Bleeding - Report of Three Cases and Literature Review

Zahidul Haq<sup>1</sup>, RA Chowdhury<sup>2</sup>, M Saief Uddin<sup>3</sup>, Mohsen Chowdhury<sup>4</sup>, Gulzar Ahmed<sup>5</sup>, Shahidul Islam<sup>5</sup>, Iqbal Hussain Talukder<sup>5</sup>

<sup>1</sup>Professor, Department of Surgery, Bangabandhu Sheikh Mujib Medical University, Dhaka, <sup>2</sup>Associate Professor of Surgery, Bangladesh Medical College, <sup>3</sup>Resident Medical Officer, <sup>4</sup>Associate Professor, <sup>5</sup>Medical officer, Department of Surgery, Bangabandhu Sheikh Mujib Medical University, Dhaka.

## Abstract:

Haemangioma of the rectum and colon is very rare malformation with only around 100 cases have been reported so far. Most commonly young adult is affected. Common site is recto sigmoid junction. Here we present three cases of rectal haemangioma affecting two males and one female patient. All were having cavernous type of haemangioma at rectum and recto sigmoid junction with one involving additional caecum and ascending colon. All the cases were misdiagnosed previously. Colonoscopy is the cornerstone for evaluation of these patients showing bluish discoloration with engorged mucosa. Rectum and sigmoid colon are commonly affected. Abdominoperineal resection was the favored procedure in the past. At present, definitive treatment of diffuse cavernous haemangioma (DCH) of rectum and sigmoid colon is excision of the involved bowel with sphincter saving procedure with either stapling or hand sewn anastomosis of colon and anal canal.

**Key words :** Rectal haemangioma, sphincter saving surgery.

*[BSMMU J 2009; 2(2): 92-94]*

## Introduction:

Cavernous haemangioma of the rectum and colon is an uncommon benign vascular lesion<sup>1</sup>. Accurate diagnosis is often missed because of lack of awareness of classical features. Repeated episodic rectal bleeding, a suspicious mind of a surgeon and careful clinical examination with a colonoscopy, all that are needed for the diagnosis of this rare disease. Patients with cavernous haemangioma usually present with painless rectal bleeding and anaemia and about 80 % of the patient are subjected to unnecessary surgical procedure before the correct diagnosis is made<sup>4</sup>. Most of the patient with diffuse cavernous haemangioma of rectum have been treated with abdominoperineal resection in the past.<sup>5</sup> Some author reported pull-through procedure with high mortality and morbidity.<sup>2</sup> There are reports with acceptable result following colo-anal sleeve procedure. Emphasis should be given on functional preservation of the anal sphincter mechanism in this young, otherwise healthy patient<sup>4</sup>.

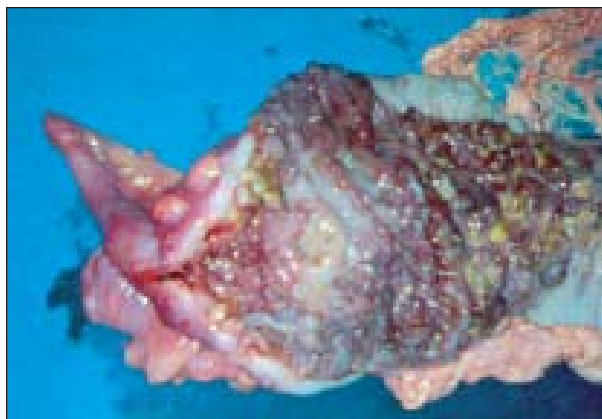Here we report three cases of rectal haemangioma which were treated in surgical department of Bangabandhu Sheikh Mujib Medical University from January 2004 to April 2009.

**Correspondence to :** Prof. Zahidul Haq, Professor of Surgery, Bangabandhu Sheikh Mujib Medical University, Dhaka, E-mail-zhaq92@hotmail.com

All the cases were misdiagnosed as case of haemorrhoid and had previous haemorrhoid surgery.

## First case:

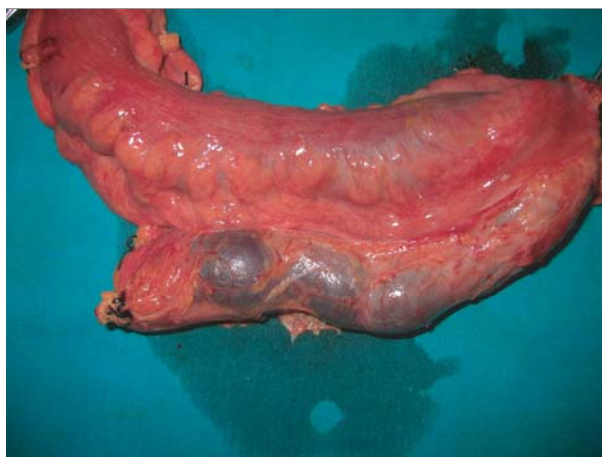A young male patient of 27 years presented with intermittent per rectal fresh bleeding since his childhood. He had several hospital admissions for blood transfusion. He was operated twice for rectal bleeding with the diagnosis of haemorrhoid. As he grew up, he became lethargic and weak to such an extent that he has given up his study. On physical examination, he was very pale and severely anemic. Abdominal examination revealed no abnormality. Digital rectal examination revealed gross blood, sponge like rectal mucosa without any palpable mass. Colonoscopy showed swollen rectal mucosa with bluish discoloration extending up to proximal sigmoid colon. There was another lesion in the caecum and proximal ascending colon (Fig. 1). Upper GI endoscopy was normal. At laparotomy the rectum and sigmoid colon had dilated tortuous vessels over the serosal surface. Mesorectum was thickened and oedematous. Caecum and proximal part of the ascending colon also showed dilated, engorged veins over the surface. Right haemecolecotomy and low anterior resection of rectum along with mesorectum was done. Gut continuity was restored. Post operative was uneventful.



**Fig. -1 :** Part of the right hemicolectomy specimen showing cavernous haemangioma of caecum and ascending colon

### Second case:

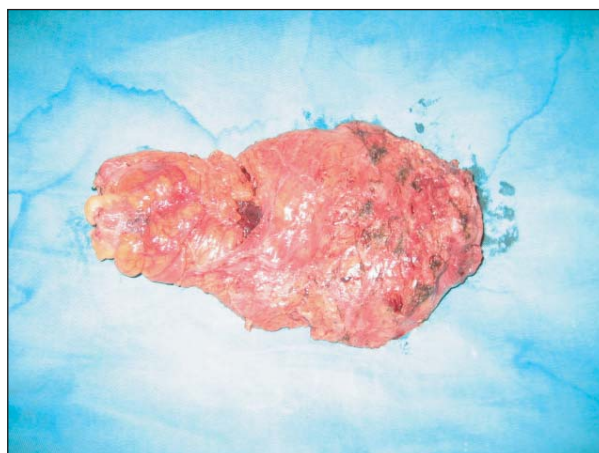A female patient of 20 years presented with similar features like that of first case. She also had several units of blood transfusion. She under went haemorrhoidectomy 3 years back. Clinical examination revealed moderate anaemia. Abdominal examination was normal. Digital rectal examination revealed fresh blood, spongy rectal mucosa. Colonoscopy revealed thick, edematous bluish discolored rectal mucosa extending from dentate line up to 30cm. After preparation of the patient, laparotomy was done. Rectum and sigmoid colon was found thickened with engorged vein on the surface. Inferior mesenteric vein was hugely dilated (Fig. 2) involving rectum and lower part of the sigmoid colon. The involved gut was excised along with mesorectum. Gut continuity was established with hand sewn coloanal anastomosis with a covering ileostomy. Post operative recovery was uneventful.



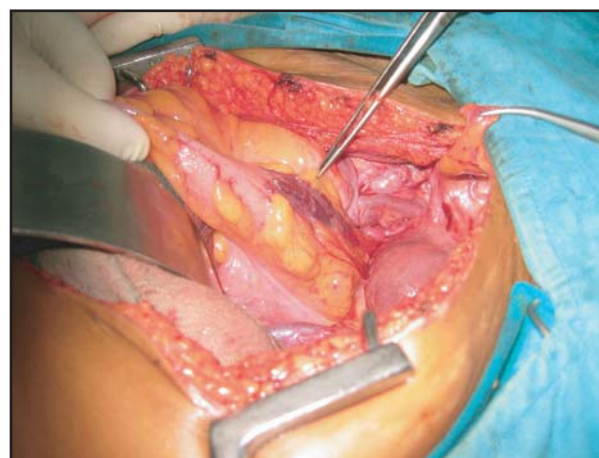
**Fig.-2:** Engorged veins in mesorectum

### Third case:

This was a young male patient of 23 years. He presented with an acute onset of rectal bleeding for which he was transfused several units of blood. Similar intermittent episode had occurred in the past since his early childhood. He was operated in the past for rectal bleeding. Except anemia, there were no abnormal physical findings. Rectal examination revealed fresh blood with smooth, soft spongy mucosa. Colonoscopy revealed angry looking engorged mucosa with bluish discoloration extending from lower rectum up to lower sigmoid colon. On laparotomy, mesorectum was found very thick, swollen and edematous (Fig. 3). Dilated veins were present over the serosal surface (Fig. 4). Mobilization of the thick mesorectum was very difficult through narrow pelvic cavity. With slow and meticulous dissection an ultralow anterior resection with stapling anastomosis was done. Histopathological examination revealed cavernous haemangioma in all the



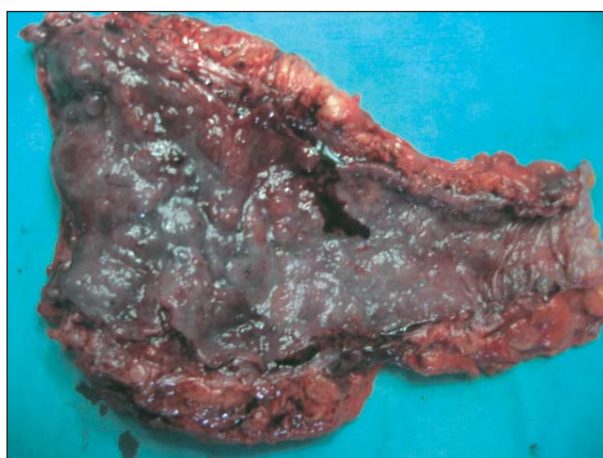
**Fig-3 :** Excised rectum with thick edematous mesorectum



**Fig.-4:** Dilated tortuous vessels over the serosal surface of recto sigmoid junction

three cases invading all the layers of rectum and colon with involvement of mesorectum.

Dilated engorged veins and bluish discoloration of the mucosa were found in all cases (figure no. 5). All these patients were followed up from one month to four and half years. All maintained good health with no further attack of rectal bleeding.



**Fig.-5 :** Engorged mucosa with dilated vessels.

#### Discussion:

Diffuse cavernous haemangioma (DCH) of the rectum and rectosigmoid junction is an extremely rare malformation usually seen in young adult with male to female ratio 2:1.<sup>6</sup> We have reported two male and one female patients. All our patients were young between 23 to 27 years. The most common site of DCH is rectosigmoid junction. However, there may be involvement of skin and mucosa and may be associated with Kalippel- Trenaunay<sup>7</sup> or Ben's syndrome.<sup>8</sup> Skin is most commonly affected and should alert the clinician to exclude rectal haemangioma. Colonic lesions are most often distal and in 70% of cases involvement occur in rectum. Colonic haemangioma are cavernous type and have no capsule<sup>9</sup> Patients usually suffer from painless rectal bleeding and anaemia. There may be diarrhoea, haematuria and constipation.<sup>10</sup> Endoscopy is the method of choice for diagnosis. Upper GIT endoscopy should be done to exclude any other synchronous haemangioma.<sup>11</sup>

Other investigations like angiography, barium enema, endoanal ultrasound and MRI may be helpful.<sup>6</sup>

Definitive treatment of DCH is excision of the involved bowel with sphincter saving procedure avoiding damage to peri- rectal neural structures.<sup>6</sup> Vascular malformation that remains in the proximal anal canal can be managed with sclerotherapy, laser or argon.<sup>1</sup>

---

*This article is republished according to the decision of the editorial board because of displacement of the photographs which was published in BSMMUJ 2009; 2(1): 36-38.*

---

#### References:

1. Cunningham JA, Gracia VF, Quispe G. Diffuse cavernous haemangioma-Sphincter saving approach to therapy. *Dis Colon Rectum* 1989; 32: 344-47.
2. Perez C, Andreu J, Illaiger J. Haemangioma of rectum: CT appearance *Gastrointest Radiol* 1987; 12: 347-49.
3. Parker GW, Murney JA, Kenoyer WL. Cavernous haemangioma of rectum and Recto-sigmoid junction-a case report review. *Dis Colon Rectum* 1960; 3: 358-63.
4. Jeffery PJ, Hawley PR, Parks AG. Colo-anal sleeve anastomosis in the treatment of Diffuse cavernous haemangioma involving rectum. *Br J Surg* 1976; 63: 678-82.
5. Parks GW, Murney JA, Kenoyer W L. Cavernous haemangioma of the rectum and recto-sigmoid junction : a case report and review. *Dis Colon Rectum* 1960; 3: 358-63.
6. Bugra D, Bulut T, Yamaner S. Soft tissue images. Diffuse cavernous rectal hemangioma. *Can J Surg* 2002; 45:365-66.
7. Perez C, Andreu J, Vallas J, Haemangioma of the rectum: CT appearance. *Gastrointest Radiol* 1987; 12: 347-49.
8. Djouhri H, Arrive L, Bouras T. Diffuse cavernous haemangioma of the rectosigmoid colon: imaging findings. *J comput Assist Tomogr* 1998; 22: 851-55.
9. Lyon DT, Mantia AG Large bowel haemangiomas. *Dis Colon Rectum* 1984; 27: 404-14.
10. Demircan O, Sonmez H, Zeren S. If cavernous haemangioma of the rectum and sigmoid colon. *Dig Surg* 1998; 15: 713-15.
11. Oner Z, Altaca G. Diffuse Cavernous Rectal Hemangioma-clinical appearance, diagnostic modalities and sphincter saving approach to therapy ; report of 2 and a collective review of 79 cases (review). *Acta Chir Belg* 1993; 93: 173-6.