

Ocular manifestations of dengue fever in Bangladesh during its out break

Shams Mohammed Noman, Md Sharfuddin Ahmed, Syed Asif, Shahnaz Hassan, Masud Parvez, Chandra Sekhar Mazumder, Umme Salma Akbar

Article Info

Department of Ophthalmology, BSMMU, Dhaka (SMN); Department of Community Ophthalmology, BSMMU, Dhaka (MSA), National Institute of Ophthalmology & Hospital, Dhaka (SA); Department of Ophthalmology, Birdem General Hospital Dhaka(SH); Department of Ophthalmology, Chattogram Medical College Hospital, Chattogram (MP), Department of Ophthalmology, Sir Salimullah Medical College & Mitford Hospital, Dhaka (CSM); Chittagong Eye Infirmary & Training Complex (USA)

For Correspondence:

Shams Mohammed Noman
E-mail: drshams_noman@yahoo.com

Received: 05 October 2021
Accepted: 30 November 2021
Available Online: 01 February 2022

ISSN: 2224-7750 (Online)
2074-2908 (Print)

DOI: <https://doi.org/10.3329/bsmmuj.v15i1.58422>

Keywords: Dengue fever, ocular manifestations, subconjunctival hemorrhages.

Cite this article:

Noman SM, Ahmed MS, Asif S, Hassan S, Parvez M, Mazumder CS, Akbar US. Ocular manifestations of dengue fever in Bangladesh during its out break. *Bangabandhu Sheikh Mujib Med Univ J*. 2022; 15(1): 16-19

Copyright:

The copyright of this article is retained by the author(s) [Attribution CC-BY 4.0]

Available at:
www.banglajol.info

A Journal of Bangabandhu Sheikh Mujib Medical University, Dhaka, Bangladesh



Abstract

Dengue fever, borne by *Aedes aegypti* mosquito, is one of the most common and most prevalent forms of flavivirus infections in humans, endemic in tropics and warm temperate regions of the world. We report a spectrum of ocular manifestations of dengue fever along with its associated laboratory findings. To study the ocular manifestations associated with dengue fever. This study was conducted in 600 patients hospitalized with diagnosis of dengue fever over a period of 3 months from March 2019 to May 2019. All patients underwent complete evaluation with respect to systemic and ophthalmic examination in different institutions of Bangladesh. A total of 600 patients were diagnosed with dengue fever; of which, 375 (62.5%) were men and 225 (37.5%) were women. Mean age was 32 years (20–60 years). Only 195 patients (32.7%) had complaints of retrobulbar pain in the eyes. 10 patients (1.67%) had blurring of vision. Ocular findings were present in 340 patients (56.7%). Most common anterior segment findings were subconjunctival haemorrhage in 275 patients (45.8%). Posterior segment findings were present in 80 patients (13.3%); of which, 70 (87.5%) had retinal haemorrhages. Ocular changes had resolved in all the cases, which came for follow-up in 8–10 weeks. It was mostly attributed to the improving platelet count. The incidence of ocular complications in dengue fever is increasing, hence all patients with dengue should be referred to an ophthalmologist to prevent any sight-threatening

Introduction

Dengue fever is one of the most common viral disease of the humans, transmitted by bite of infected female *Aedes aegypti* mosquito. The highest incidence occurs in Southeast Asia and the American tropics. Worldwide cases of illness exceed 50–100 million per year.¹ Dengue infection is characterized by an abrupt onset of fever along with symptoms of malaise, sore-throat, rhinitis and cough, headache, muscle ache, retro-orbital pain, lumbosacral pain and rash. Other clinical manifestations of dengue are related to the bleeding diathesis from thrombocytopenia.² Ophthalmic manifestations in dengue fever were previously not well described but now can be seen with increasing frequency in recent literature.³⁻⁹ The main ocular manifestations included conjunctival hemorrhages, macular oedema and retinal hemorrhages. Less common features included exudative retinal detachment, anterior uveitis, periphlebitis, branch retinal vein occlusion and vitreous haemorrhage. A majority of patients were reported to have

residual visual impairment secondary to maculopathy and optic neuropathy.⁵⁻⁸ The main objective of this study was to evaluate the ophthalmic manifestations associated with dengue fever.

Methods

A prospective observational study was conducted in 600 patients in different institutions of Bangladesh like Chittagong Medical College, Sir Salimullah Medical College, Birdem Hospital, Chittagong medical college, Dhaka Medical College and Bangabandhu Sheikh Mujib Medical University. The diagnosis was based on the presence of fever with other characteristic symptoms and signs. It was confirmed with serological testing with IgM and IgG antibody assay and decreasing platelet counts. The study was carried out for a period of 3 months from March 2019 to May 2019. All patients were asked detailed history with importance

to visual symptoms. Detailed systemic examination and laboratory findings were recorded. All patients' best-corrected visual acuities were measured with Snellen acuity chart for both distance and near. Further, they were evaluated in detail with slit lamp examination using +90 D and +78 D lens. Dilated fundus examination was carried out with indirect ophthalmoscope using +20 D lens and fundus photos were taken with fundus camera. The patients with positive ophthalmic findings were asked to follow-up weekly.

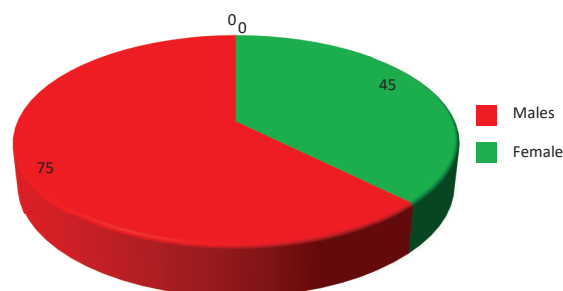


Figure - 1: Gender distribution of the Dengue patients (N=600)

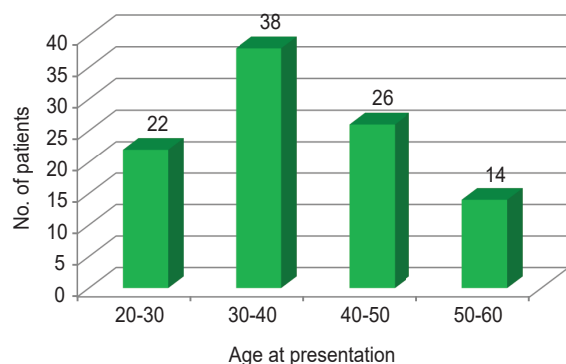


Figure - 2: Age distribution of the Dengue patients (N=600)

Results

Of the 600 patients diagnosed with dengue, 375 (62.5%) were men and 225 (37.5%) were women (Figure - 1) with mean age of 32 years (20–60 years) (Figure - 2). All patients presented with fever, with 550 (92%) patients presenting with myalgia. Other uncommon systemic findings were vomiting, lumbosacral pain, and bleeding gums. Retrobulbar pain was present in 195 (32.5%) patients and 520 (87%) patients were found to have marked thrombocytopenia $<50,000/\mu\text{l}$. Ocular manifestations were seen in patients with thrombocytopenia $<35,000/\mu\text{l}$ [Figure 3] with maximum in range between 15,000/ μl and 35,000/ μl .

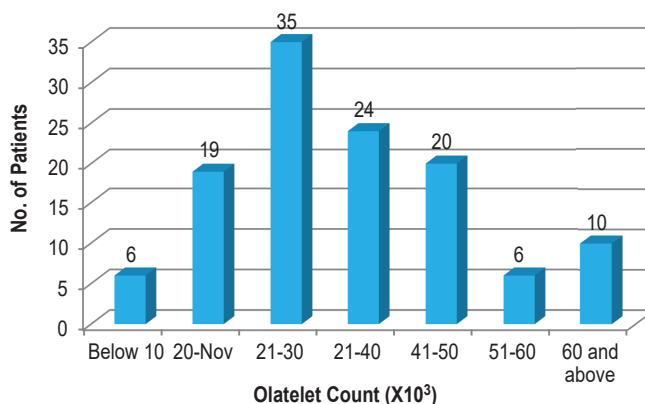


Figure - 3: Platelet count of the Dengue patients (N=600)

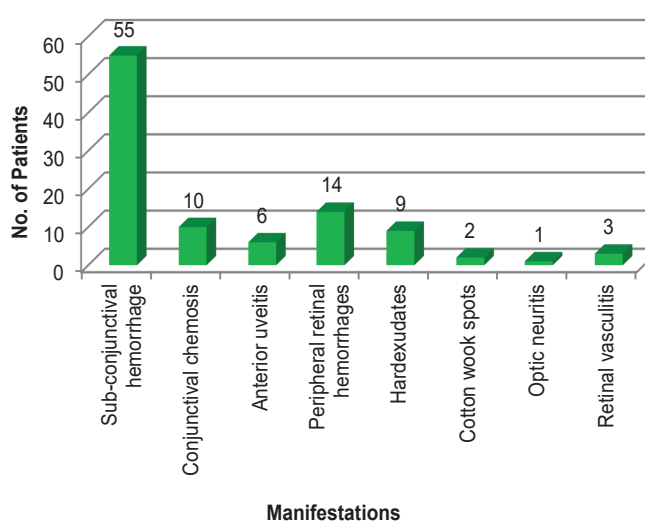


Figure - 4: Ocular manifestations of the Dengue patients (N=600)

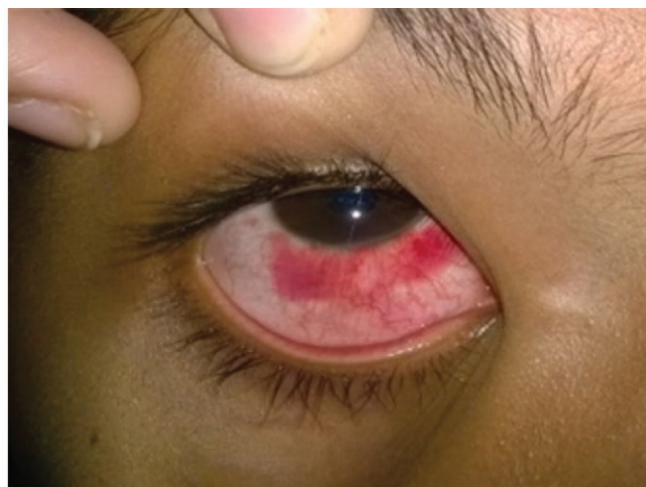

Figure - 5: Subconjunctival hemorrhage in right eye of a 24-year-old female diagnosed with dengue fever.

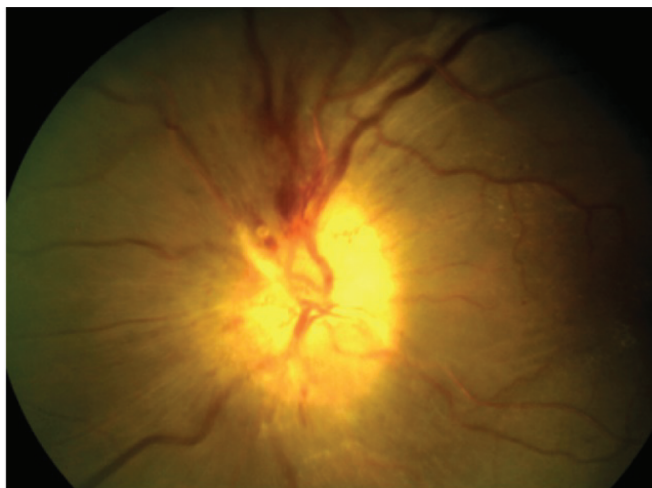

Figure - 6: Fundus photograph of left eye showing disk swelling, hyperemia and hemorrhages suggesting dengue-related optic neuropathy

The mean time interval of presentation of ocular features was eighth day with range of 5–11 days. Ocular findings were present in 340 patients; of which, 275 (45.8%) [Figure 5] had subconjunctival hemorrhage as the most common anterior segment findings. Of the 275 patients, 200 had petechial type and the rest diffuse type of hemorrhage.

Other uncommon anterior segment findings were conjunctival chemosis and anterior uveitis. Posterior segment findings were present in 80 patients (13.3%), of which 14(87.5%) had peripheral retinal hemorrhages. Other uncommon findings were retinal vasculitis, cotton wool spots and hard exudates. Only one patient had optic neuritis [Figure 6]. Of the 340 patients having ocular manifestations [Figure 4], 300 patients who could be followed up had completely resolved ocular findings within 8–10 weeks. It was mainly attributed to the improving platelet counts.

Discussion

Dengue is one of the most important emerging viral diseases affecting the humans, especially in Southeast Asian countries posing a public health problem.¹⁰ It is a communicable disease transmitted by the bite of an *Aedes* mosquito infected with any one of the four dengue viruses (DEN-1, DEN-2, DEN-3, and DEN-4). Recovery from infection by one provides lifelong immunity against that particular serotype. Subsequent infections by other serotypes increase the risk of developing severe dengue (previously known as dengue hemorrhagic fever).¹

The mechanism of the varied ophthalmic manifestation of dengue fever ranging from subconjunctival haemorrhage to

optic neuritis is not well known but indicative of an immune mediated process and possibly infective aetiology.¹¹ The causes of haemorrhage could be thrombocytopenia with coagulation defects, capillary fragility, consumptive coagulopathy, and platelet dysfunction.¹² Generally, there is complete resolution of ocular changes in dengue fever.

Ocular manifestations reported to be associated with dengue infection are mostly posterior segment, such as macular oedema, vascular occlusion, vitreous haemorrhage, optic neuropathy, chorioretinitis, vasculitis with retinal haemorrhages and cotton wool spots.^{4,5,8,13,14} Anterior segment manifestation has been mostly reported in the form of subconjunctival haemorrhages and anterior uveitis.^{15,16} Other very rare associations are ptosis, periorbital ecchymosis and globe rupture.^{3,17,18}

Our study is similar to that by Kapoor et al.¹⁵ and Hussain et al.³ with regard to male preponderance. The mean age group of our study is 32 years that is also similar in other studies.^{3,15}

A total of 87% of our patients had platelet count <50,000/ μ l and all our patients with ocular complications had platelet count of <35,000/ μ l as compared to the study reported by Kapoor et al.,¹⁵ which had 90.7% of similar association. The onset of ocular manifestations in our study correlated with the nadir of thrombocytopenia as seen in other studies.^{3,9,13,18}

The most common ocular manifestation in our patients was subconjunctival haemorrhage followed by retinal haemorrhages. It was similar to the studies by Kapoor et al.¹⁵ and Hussain et al.³ however, in contrast, one patient presented with optic neuropathy in our study.

Less common findings were anterior uveitis and conjunctival chemosis, hard exudates, cotton wool spots and retinal vasculitis. In our study, the ocular findings were varied involving both anterior and posterior segments in contrast to study reported by Lim et al.⁸ where in the ocular features were mainly limited to the macula.

None of the patients in our study presented with bilateral periorbital ecchymosis or unilateral ptosis and proptosis, secondary to anterior orbital and retrobulbar haemorrhage, respectively, or globe rupture as compared to other previously reported studies.^{3,15} The patients in our study even included patients with diabetes and hypertension, so the retinal manifestations per se could not be attributed to dengue fever, but just as an association with dengue fever that forms a limitation to our study. Because there is expected increase in epidemicity of dengue fever, hence even the ophthalmic manifestations are expected to rise, so the treating physician should be aware and promptly refer any such case to the ophthalmologist as early as possible.

Conclusion

Dengue fever can result in varied ocular manifestations ranging from subconjunctival haemorrhage to optic neuropathy. Though most common manifestation is subconjunctival haemorrhage, retinal haemorrhages can also occur. Hence, thrombocytopenia should be corrected at the earliest to avoid ocular complications.

Conflict of Interest: None

References

- World Health Organization. Dengue and Severe Dengue. Available at: <http://www.who.int/mediacentre/factsheets/fs117/en/> (last accessed on November 4, 2012).
- Yip VC, Sanjay S, Koh YT. Ophthalmic complications of dengue fever: a systematic review. *Ophthalmol Ther* 2012; 1(1):2
- Hussain I, Afzal F, Shabbir A, Adil A, Zahid A, Tayyib M. Ophthalmic manifestation of dengue fever. *Ophthalmology Update* 2012; 10:93-6.
- Nainiwal S, Garg SP, Prakash G, Nainiwal N. Bilateral vitreous haemorrhage associated with dengue fever. *Eye (Lond)* 2005;19:1012-3.
- Cruz-Villegas V, Berrocal AM, Davis JL. Bilateral choroidal effusions associated with dengue fever. *Retina* 2003;23: 576-8.
- Chlebicki MP, Ang B, Barkham T, Lande A. Retinal haemorrhages in 4 patients with dengue fever. *Emerg Infect Dis* 2005; 11:770-2.
- Siqueira RC, Vitral NP, Campos WR, Orefice F, de Moraes Figueiredo LT. Ocular manifestations in dengue fever. *Ocul Immunol Inflamm* 2004;12:323-7.
- Lim WK, Mathur R, Koh A, Yeoh R, Chee SP. Ocular manifestations of dengue fever. *Ophthalmology* 2004; 111: 2057-64.
- Wen KH, Sheu MM, Chung CB, Wang HZ, Chen CW. The ocular fundus findings in dengue fever. *Gaoxiong Yi Xue Ke Xue Za Zhi* 1989;5:24-30.
- National Vector Borne Disease Control Programme. Dengue Cases and Deaths in the Country Since 2008. Available at: <http://nvbdcp.gov.in/den-cd.html> (last accessed on November 4, 2012).
- Teoh SC, Chan DP, Nah GK, Rajagopalan R, Laude A, Ang BS, et al. Are-look at ocular complications in dengue fever and DHF. *Dengue Bull* 2006;30:184-93.
- Chhina DK, Goyal O, Goyal P, Kumar R, Puri S, Chhina RS. Haemorrhagic manifestations of dengue fever and their management in a tertiary care hospital in north India. *Indian J Med Res* 2009;129:718-20.
- Chan DP, Teoh SC, Tan CS, Nah GK, Rajagopalan R, Prabhakaragupta MK, et al. Ophthalmic complications of dengue. *Emerg Infect Dis* 2006;12:285-9.
- Sanjay S, Wagle AM, Au Eong KG. Optic neuropathy associated with dengue fever. *Eye* 2008;22:722-4.
- Kapoor HK, Bhai S, John M, Xavier J. Ocular manifestations of dengue fever in an East Indian epidemic. *Can J Ophthalmol* 2006;41:741-6.
- Gupta A, Srinivasan R, Setia S, Soundravally R, Pandian DG. Uveitis following dengue fever. *Eye* 2009;23:873-6.
- Kumar V, Ghosh B, Raina UK, Goel N. Bilateral periorbital ecchymosis in a case with dengue fever. *Indian J Ophthalmol* 2009;57:242-3.
- Nagaraj KB, Jayadev C, Yajmaan S, Prakash S. An unusual ocular emergency in severe dengue. *Middle East Afr J Ophthalmol* 2014;21(4):347-9.