

RESEARCH ARTICLE

Effectiveness of low energy extracorporeal shock wave therapy in the treatment of chronic insertional Achilles tendinopathy



Md. Abirul Islam¹ | Md Shawkat Hossain¹ | Mohammed Arman² |
AMM Ashrafur Islam³ | Shakir Ur Rashid⁴ | Md. Asad Raihan⁵

¹Department of Physical Medicine and Rehabilitation, Chittagong Medical College Hospital, Chattogram, Bangladesh

²Department of Physical Medicine and Rehabilitation, Chattagram International Medical College, Chattogram, Bangladesh

³Department of Physical Medicine and Rehabilitation, Marine City Medical College and Hospital, Chattogram, Bangladesh

⁴Department of Physical Medicine and Rehabilitation, Chattogram Maa-O-Shishu Hospital Medical College, Chattogram, Bangladesh

⁵Department of Physical Medicine and Rehabilitation, Southern Medical College and Hospital, Chattogram, Bangladesh

Abstract

Background: Insertional Achilles tendinopathy is a prevalent overuse disorder that often persists despite traditional interventions like rest, orthoses, and exercise therapy. When conservative measures fail, extracorporeal shockwave therapy (ESWT) serves as a promising non-invasive alternative. This study evaluated the effectiveness of low-energy ESWT for chronic insertional Achilles tendinopathy in a local hospital-based population.

Methods: This quasi-experimental study was conducted at Chittagong Medical College Hospital from October 2021 to April 2022. The study enrolled 39 adults with chronic symptoms lasting at least 3 months, a morning pain visual analogue scale (VAS) score above 5, and a history of failed conservative treatment. Participants received four weekly ESWT sessions; corticosteroids were prohibited. Outcomes were measured using the VAS for pain and the Roles and Maudsley score (RMS) for functional status, with follow-ups at 1, 2, and 3 months post-treatment. Data were analysed using repeated-measures ANOVA with Bonferroni-adjusted post hoc comparisons.

Results: The mean baseline VAS score was 7.9 (0.8), decreased to 4.6 (0.7) at 1 month and 2.3 (0.5) at 3 months ($P<0.001$). The mean RMS improved from 2.9 (0.7) at baseline to 0.9 (0.6) at 3 months ($P<0.001$). Post hoc analysis showed significant improvement from baseline to each follow-up for both outcomes; for VAS, all pairwise comparisons remained significant, whereas for RMS the difference between 2 and 3 months was not significant after adjustment.

Conclusion: Low-energy ESWT provides substantial short-term pain relief and functional recovery for patients with recalcitrant insertional Achilles tendinopathy.

Key messages

Low-energy extracorporeal shockwave therapy significantly reduces pain and improves functional outcomes in patients with chronic insertional Achilles tendinopathy who have failed previous conservative treatments. This non-invasive intervention was well-tolerated over a three-month follow-up period, demonstrating its efficacy as a viable clinical alternative for resistant cases.

Correspondence

Md. Abirul Islam
abir48cmc@gmail.com

Publication history

Received: 6 Feb 2026
Accepted: 10 May 2026
Published online: 1 June 2026

Responsible editor

Tahniah Haq
0000-0002-0863-0619

Reviewers

C: Anonymous
E: Anonymous

Keywords

extracorporeal shock wave therapy, Achilles tendinopathy, visual analogue scale, Roles and Maudsley score

Funding

None

Ethical approval

Approved by Institutional Review Board of Chittagong Medical College Hospital (No. CMC/PG/20211/734, Dated 30 May 2021).

© The Author(s) 2025; all rights reserved.

Published by Bangladesh Medical University (former Bangabandhu Sheikh Mujib Medical University).

Introduction

Chronic Achilles tendinopathy (AT) is a prevalent overuse injury of the foot and ankle, marked by pain, swelling, and impaired performance. It is commonly classified into mid-portion AT (mid-AT) and insertional AT (ins-AT), with mid-AT being more common (55–65%) than ins-AT (20–25%) [1]. AT is most frequently observed between ages 40–59 and is particularly prevalent among runners and other athletes [2, 3].

Conservative treatments for ins-AT include rest, nonsteroidal anti-inflammatory drugs, footwear modifications, stretching, eccentric strengthening, and corticosteroid injections. However, these approaches often yield suboptimal results in chronic cases. Extracorporeal shock wave therapy (ESWT) has emerged as a promising non-invasive alternative [4]. While its exact mechanisms remain incompletely understood, ESWT may promote tendon healing through mechanotransduction, neovascularization, modulation of nociceptor activity, and tissue remodeling [5, 6].

ESWT is often used after failure of first-line conservative management and may be more effective when integrated with structured loading programmes [6–8]. Several systematic reviews and meta-analyses have supported its use in chronic Achilles tendinopathy, although the magnitude of effect appears to vary by protocol and patient selection [5, 7, 8].

However, some recent high-quality studies have questioned its benefits. Mansur *et al.* [9] and Pinitkwandee *et al.* [10] conducted double-blind randomised controlled trials and found no significant additional effect of ESWT over eccentric training or sham therapy in chronic ins-AT, particularly in older adults.

Given this controversy, further research was warranted to clarify ESWT's role. The current study aimed to evaluate the effectiveness of low-energy ESWT in managing chronic insertional Achilles tendinopathy.

Methods

This quasi-experimental study was conducted in the Department of Physical Medicine and Rehabilitation, Chittagong Medical College Hospital, Chattogram, Bangladesh, from 19 October 2021 to 18 April 2022. Eligible participants were men or women aged 18–60 years with chronic ins-AT for at least 3 months, morning pain VAS score >5, history of failed conservative treatment, and willingness to participate. Failed conservative treatment was defined as persistent symptoms despite at least one standard non-operative modality such as activity modification, anti-inflammatory medication, therapeutic exercise, or physiotherapy before enrolment.

This was a consecutive, feasibility-based hospital study. Instead of a formal sample size calculation, all eligible patients presenting during the predefined study period were enrolled using a consecutive sampling approach, resulting in a final sample of 39 participants. This approach was chosen to maximise data capture in an exploratory setting where prior estimates required for sample size calculation were

limited. However, the study may be underpowered to detect small-to-moderate associations.

Outpatients of Physical Medicine and Rehabilitation were evaluated through history, physical examination, and relevant investigations. These included complete blood count, C-reactive protein, rheumatoid factor, serum uric acid, serum thyroid-stimulating hormone, fasting blood glucose, 2-hour postprandial blood glucose, plain X-ray (anteroposterior and lateral views of the involved calcaneus), and ultrasonography of the affected heel. Exclusion criteria were previous Achilles tendon rupture or surgery, inflammatory arthritis, acute infection, uncontrolled diabetes mellitus, severe neurologic deficit affecting the limb, pregnancy, bleeding disorder or anticoagulant use, local corticosteroid injection within the previous 3 months, current systemic corticosteroid therapy, and unwillingness to complete follow-up.

Face-to-face interviews were conducted using a semi-structured questionnaire to collect socio-demographic data, clinical history, previous treatment details, and baseline scores of the visual analogue scale (VAS; 0=no pain, 10=worst imaginable pain) and Roles and Maudsley score (RMS; 1=excellent, 2=good, 3=fair, 4=poor). Past treatment and investigation records were verified through patient reports and available documents.

Table 1 Baseline clinical characteristics of the patients (n=39)

Variables	Number (%)
Age in years, mean (SD) ^a	44.5 (10.6)
Male, sex	24 (61.5)
Body mass index, mean (SD)	22.1 (1.6)
Duration of disease in months, median (range)	5 (3–9)
Side of involvement, right	13 (33.3)
Treatment received	
Physiotherapy	12 (30.8)
Therapeutic exercise	18 (46.2)
Anti-inflammatory medications	39 (100.0)
Laboratory investigations	
Haemoglobin (g/dL)	13.1 (1.2)
Red blood cell count ($\times 10^{12}/L$)	4.7 (0.5)
Total white blood cell count ($\times 10^9/L$)	7.4 (1.6)
Platelet count ($\times 10^9/L$)	265 (58)
Erythrocyte sedimentation rate (mm in 1st hour)	16.8 (7.2)
C-reactive protein (mg/L)	3.2 (1.5)
Rheumatoid factor (IU/mL)	8.1 (3.4)
Thyroid-stimulating hormone (mIU/L)	2.5 (0.9)
Fasting blood glucose (mmol/L)	5.2 (0.6)
2 hour postprandial blood glucose (mmol/L)	6.7 (0.8)
Serum uric acid (mg/dL)	5.1 (1.0)
Calcaneal spur on X-ray	7 (18.0)
Ultrasonography of involved heel	
Hypo-echogenicity	32 (82.1)
High-echogenic calculi	7 (18.0)
Baseline VAS ^b score, mean (SD)	7.9 (0.8)
Baseline RMS ^c score, mean (SD)	2.9 (0.7)

^aStandard deviation; ^bvisual analogue scale; ^cRoles and Maudsley score

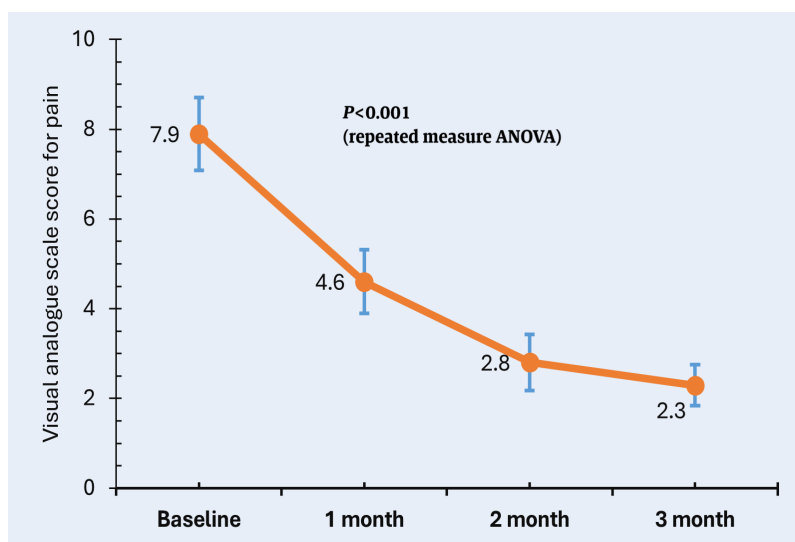


Figure 1 Mean visual analogue scale score at different time points of treatment with extracorporeal shock wave therapy in patients with chronic insertional Achilles tendinopathy. Error bars indicate standard deviation (n=39)

Treatment was carried out using low-energy ESWT with an Enraf-Nonius Endopuls 811 device. A 15 mm radial probe was applied over the most tender point at the Achilles tendon insertion using ultrasound gel, with the patient in prone position. Shockwaves were delivered tangentially in a lateral-to-medial direction while the ankle was gently mobilised in all planes to target the entire tendon insertion and surrounding tissue.

Each patient received 4 weekly ESWT sessions (4 Hz frequency, 0.06 mJ/mm² energy flux density, 800 pulses/session). Participants were advised not to start any additional tendon-directed intervention during the treatment period; specifically, no corticosteroid injection or oral steroid was prescribed as co-intervention. Outcomes were assessed using VAS and RMS at 1, 2, and 3 months after treatment. Data were recorded in a pretested questionnaire and analysed statistically.

Collected data were compiled in Microsoft Excel and analysed using SPSS version 28. Categorical variables were presented as frequencies and

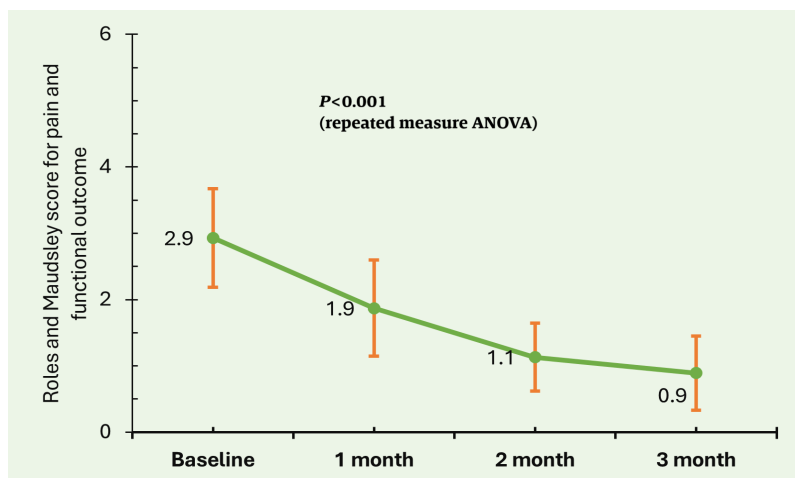


Figure 2 Mean Roles and Maudsley score at different time points of treatment with extracorporeal shock wave therapy in patients with chronic insertional Achilles tendinopathy. Error bars indicate standard deviation (n=39)

percentages, while continuous variables were expressed as mean (standard deviation) (SD). Repeated-measures analysis of variance (ANOVA) was used to compare mean VAS and RMS values across time, followed by Bonferroni-adjusted post hoc pairwise comparisons (baseline vs 1, 2, and 3 months; 1 versus 2 months; 1 versus 3 months; and 2 versus 3 months). A two-sided $P < 0.05$ was considered statistically significant.

To ensure data quality, a detailed work manual was prepared and the questionnaire was pretested for clarity and completeness. Data collection, analysis, and report writing were conducted under supervision of the study guide. Because the study was single-arm and exploratory, internal validity was strengthened by restricting enrolment to patients with chronic symptoms who had not improved with prior conservative treatment and by using repeated within-patient assessment at prespecified follow-up points.

Results

The mean age of the patients at enrolment was 44.5 (10.6) years, and 61.5% were aged 41–60 years. Male patients predominated (61.5%). Disease duration ranged from 3 to 9 months, with a median duration of 6 months. On plain X-ray, 7 patients (18.0%) had a calcaneal spur at the insertional region; ultrasonography showed corresponding high-echogenic calculi with posterior acoustic shadowing in the same 7 patients (Table 1).

The VAS pain score decreased from 7.9 (0.8) at baseline to 4.6 (0.7) at 1 month, 2.8 (0.6) at 2 months, and 2.3 (0.5) at 3 months. Repeated-measures ANOVA showed an overall significant change across follow-up ($P < 0.001$). Bonferroni-adjusted post hoc analysis showed significant differences between baseline and each follow-up visit and between every consecutive pair of follow-up visits, including 2 vs 3 months (Figure 1).

The RMS is a 4-point functional outcome scale in which 1 indicates excellent and 4 indicates poor outcome. Before treatment, most patients had scores of 3 or 4, whereas after 3 months of treatment 87.3% scored 1, indicating marked reduction in disability.

The mean RMS improved from 2.9 (0.7) at baseline to 1.9 (0.7) at 1 month, 1.1 (0.5) at 2 months, and 0.9 (0.5) at 3 months. Repeated-measures ANOVA showed a significant overall difference across time ($P < 0.001$). Bonferroni-adjusted post hoc analysis showed significant differences between baseline and all follow-up visits and between 1 month and both later follow-up visits; the difference between 2 and 3 months was not statistically significant after adjustment (Figure 2).

Discussion

Ins-AT is difficult to treat once symptoms become chronic, because mechanical overload, degenerative tendon change, and persistent pain sensitisation may coexist at the tendon-bone junction. In that setting, ESWT is attractive because it is non-invasive and can be delivered after failure of routine conservative care. The present study therefore focused on a clinically relevant subgroup: patients with chronic ins-AT who had remained symptomatic despite prior non-operative treatment.

The absence of a control group is the main limitation of this study and restricts causal inference. We attempted to reduce this threat by enrolling only patients with persistent symptoms after failed conservative treatment, then following the same individuals prospectively at fixed intervals after a standardised ESWT protocol. Although spontaneous improvement cannot be excluded, this design makes simple regression to the mean a less satisfactory explanation for the consistent stepwise improvement observed across repeated assessments.

The observed reduction in pain and improvement in function are biologically plausible. ESWT is thought to act through a combination of pain modulation, stimulation of local circulation, and promotion of tissue remodeling [5, 6]. Clinically, this may translate into gradual pain reduction over weeks rather than an immediate effect, which matches the temporal pattern seen in this cohort, with progressive improvement from month 1 through month 3.

Our findings are broadly consistent with prior case-series and some controlled studies reporting benefit of ESWT in chronic Achilles tendinopathy [7, 11]. At the same time, more recent randomised trials have shown mixed results, especially when ESWT is compared against active loading programmes or sham procedures [9, 10, 12]. This inconsistency likely reflects heterogeneity in energy level, number of sessions, chronicity, baseline severity, and whether ESWT was used alone or as an adjunct to eccentric loading.

The post hoc results add an important clinical nuance. For pain, significant differences were present not only between baseline and follow-up visits but also between successive follow-up assessments, suggesting continued symptomatic improvement through 3 months. Previous studies also demonstrated significant improvement in pain and functional outcomes following ESWT [13, 14]. For function, most of the gain occurred by 2 months, after which improvement plateaued, as the 2- versus 3-month RMS comparison was not significant. This pattern suggests that pain relief may continue after functional recovery begins to stabilise.

These findings have practical implications for rehabilitation services in resource-constrained settings. In patients who do not respond to usual conservative measures, low-energy ESWT may offer a non-surgical option that can be delivered in an outpatient department with short-term follow-up. However, the present results should be interpreted as supportive rather than definitive evidence, because the study cannot determine whether ESWT is superior to continued exercise-based care, sham therapy, or natural recovery.

Strengths of the study include the clearly defined patient group, use of validated outcome measures, standardized treatment protocol, and complete short-term follow-up. The single-centre design, feasibility-based sample, and 3-month follow-up limit external validity and do not address durability of response. In addition, eccentric loading was not delivered as a structured co-intervention, which may have influenced the magnitude of response relative to some comparative trials [7, 9].

Overall, the study supports the short-term clinical usefulness of ESWT in chronic ins-AT after failed conservative treatment, while also highlighting the need for controlled studies with longer follow-up and clearer comparison against established loading-based interventions. Low-energy ESWT was associated with short-term improvement in pain and function in patients with chronic insertional Achilles tendinopathy, particularly among those who had not improved with prior conservative treatment.

Conclusion

Low-energy ESWT was associated with short-term improvement in pain and function in chronic ins-AT, particularly among patients who had not improved with prior conservative treatment.

Acknowledgments

We thank the Department of Physical Medicine and Rehabilitation, Chittagong Medical College Hospital, for support, the patients for participation, and colleagues for valuable academic input during this study.

Author contributions

Concept or design of the work; or the acquisition, analysis, or interpretation of data for the work: MAI, MSH, MA. *Drafting the work or reviewing it critically for important intellectual content:* MAI, MSH, MA, AAMAI, SUR, MAR. *Final approval of the version to be published:* MAI, MSH, MA, AAMAI, SUR, MAR. *Accountable for all aspects of the work in ensuring that questions related to the accuracy or integrity of any part of the work are appropriately investigated and resolved:* MAI.

Conflict of interest

We do not have any conflict of interest.

Data availability statement

We confirm that the data supporting the findings of the study will be shared upon reasonable request.

AI disclosure

ChatGPT (OpenAI) was used for language editing and formatting assistance. The authors verified all content and are fully responsible for the accuracy and integrity of the manuscript.

Supplementary file

None

References

- Järvinen TA, Kannus P, Maffulli N, Khan KM. Achilles tendon disorders: etiology and epidemiology. *Foot Ankle Clin.* 2005 Jun;10(2):255-266. doi: <https://doi.org/10.1016/j.fcl.2005.01.013>
- Yasui Y, Tonogai I, Rosenbaum AJ, Shimozone Y, Kawano H, Kennedy JG. The Risk of Achilles Tendon Rupture in the Patients with Achilles Tendinopathy: Healthcare Database Analysis in the United States. *Biomed Res Int.* 2017;2017:7021862. doi: <https://doi.org/10.1155/2017/7021862>
- Martin RL, Chimenti R, Cuddeford T, Houck J, Matheson JW, McDonough CM, Paulseth S, Wukich DK, Carcia CR. Achilles Pain, Stiffness, and Muscle Power Deficits: Midportion Achilles Tendinopathy Revision 2018. *J Orthop Sports Phys Ther.* 2018 May;48(5):A1-A38. doi: <https://doi.org/10.2519/jospt.2018.0302>
- Irwin TA. Current concepts review: insertional achilles tendinopathy. *Foot Ankle Int.* 2010 Oct;31(10):933-939. doi: <https://doi.org/10.3113/FAI.2010.0933>
- Gerdesmeyer L, Mittermayr R, Fuerst M, Al Muderis M, Thiele R, Saxena A, Gollwitzer H. Current evidence of extracorporeal shock wave therapy in chronic Achilles tendinopathy. *Int J Surg.* 2015 Dec;24(Pt B):154-159. doi: <https://doi.org/10.1016/j.ijsu.2015.07.71826327530>

6. Waugh CM, Morrissey D, Jones E, Riley GP, Langberg H, Screen HR. In vivo biological response to extracorporeal shockwave therapy in human tendinopathy. *Eur Cell Mater*. 2015 May 15;29:268-280; discussion 280. doi: <https://doi.org/10.22203/ecm.v029a20>
7. Al-Abbad H, Allen S, Morris S, Reznik J, Biroš E, Paulik B, Wright A. The effects of shockwave therapy on musculoskeletal conditions based on changes in imaging: a systematic review and meta-analysis with meta-regression. *BMC Musculoskelet Disord*. 2020 Apr 28;21(1):275. doi: <https://doi.org/10.1186/s12891-020-03270-w>
8. Irby A, Gutierrez J, Chamberlin C, Thomas SJ, Rosen AB. Clinical management of tendinopathy: A systematic review of systematic reviews evaluating the effectiveness of tendinopathy treatments. *Scand J Med Sci Sports*. 2020 Oct;30(10):1810-1826. doi: <https://doi.org/10.1111/sms.13734>
9. Mansur NSB, Matsunaga FT, Carrazzone OL, Schiefer Dos Santos B, Nunes CG, Aoyama BT, Dias Dos Santos PR, Faloppa F, Tamaoki MJS. Shockwave Therapy Plus Eccentric Exercises Versus Isolated Eccentric Exercises for Achilles Insertional Tendinopathy: A Double-Blinded Randomized Clinical Trial. *J Bone Joint Surg Am*. 2021 Jul 21;103(14):1295-1302. doi: <https://doi.org/10.2106/JBJS.20.01826>
10. Pinitkwamdee S, Laohajaroensombat S, Orapin J, Woratanarat P. Effectiveness of Extracorporeal Shockwave Therapy in the Treatment of Chronic Insertional Achilles Tendinopathy. *Foot Ankle Int*. 2020 Apr;41(4):403-410. doi: <https://doi.org/10.1177/1071100719898461>
11. Pavone V, Cannavò L, Di Stefano A, Testa G, Costarella L, Sessa G. Low-Energy Extracorporeal Shock-Wave Therapy in the Treatment of Chronic Insertional Achilles Tendinopathy: A Case Series. *Biomed Res Int*. 2016;2016:7123769. doi: <https://doi.org/10.1155/2016/7123769>
12. Paantjens MA, Helmhout PH, Backx FJG, van Etten-Jamaludin FS, Bakker EWP. Extracorporeal Shockwave Therapy for Mid-portion and Insertional Achilles Tendinopathy: A Systematic Review of Randomized Controlled Trials. *Sports Med Open*. 2022 May 13;8(1):68. doi: <https://doi.org/10.1186/s40798-022-00456-5>
13. Wheeler PC, Tattersall C. Novel Interventions for Recalcitrant Achilles Tendinopathy: Benefits Seen Following High-Volume Image-Guided Injection or Extracorporeal Shockwave Therapy-A Prospective Cohort Study. *Clin J Sport Med*. 2020 Jan;30(1):14-19. doi: <https://doi.org/10.1097/JSM.0000000000000580>
14. Yan B, Wan Y, Zhang H, Pan M, Zhou C. Extracorporeal Shockwave Therapy for Patients with Chronic Achilles Tendinopathy in Long or Short Course. *Biomed Res Int*. 2020 Aug 11;2020:7525096. doi: <https://doi.org/10.1155/2020/7525096>