

Recent Advancement in Non-surgical Interventional Treatment in Congenital Heart Disease at National Institute of Cardiovascular Disease (NICVD)-a Tertiary Care Hospital of Bangladesh

ABMA Salam¹, AMA kamali², KA Hasan³, Ataul H¹, M Selim¹, H Shariar¹, N Somayra¹, H Zahidul³, MK Hassan², SA Mita¹, Rezaul¹, ABM Habibullah¹, SA Razzaque¹, NU Zakia¹, MF Islam², B Ananya¹, KA Syfullah¹, AK Beg⁴, M Rahman⁴, R Shahnaz⁴, M Marjan⁴, KK Karmakar⁴, M Alauddin⁴, MK Lutful⁴, AM Soufi⁴, M Ullah⁵, M Ali⁵, AAS Majumder⁵.

¹Department of Pediatric Cardiology, NICVD, Dhaka, ²Department of Pediatrics & Pediatric Cardiology. Dubai Govt. Health center, Dubai, ³Department of Pediatric Cardiac Surgery, NICVD, Dhaka, ⁴Department of Anesthesiology. NICVD, Dhaka, ⁵Department of Cardiology, NICVD, Dhaka

Abstract

Key Words :
Congenital heart disease,
Device closure,
ASD, VSD,
PDA, PTMC.

Background: Treatment of Congenital Heart Disease (CHD) is either Surgical or Interventional. Medical management is mainly symptomatic / palliative. Although surgery is the main mode of treatment but in the recent past non-surgical Interventional method is replacing it because of its multiple advantages over surgical procedures. Since 2005, we started our journey in National Institute of Cardiovascular Diseases with a PDA device closure. In this article we tried to review the success rate of the interventional procedures in this hospital.

Methods: The aim of this retrospective study is to review the short term & Intermediate outcome of the non surgical interventional treatment of congenital heart diseases. We included all the interventional rocedures done in this Institute since 2005 upto December 2013.

Results: During this period, we performed total 150 cases of patent ductus arteriosus (PDA) device, 20 cases of PDA Coil closure, 60 cases of atrial septal defect (ASD) device, 90 cases of Balloon Pulmonary Valvuloplasty (BPV), 20 cases of Balloon Aortic Valvuloplasty (BAV), 22 cases of Coarctation Balloon Angioplasty, 35 cases of Mitral Valvuloplasty (PTMC), 15 cases of Balloon Atrial Septostomy. Almost all of our intervention procedures were successful except one case of mortality related to procedure of PDA device closure, 4 device embolization (2 ASD & 2 PDA) and one case of PDA coil with persistent Intravascular hemolysis. All the embolized devices were subsequently retrieved surgically with repair. All other patients of interventional treatment are enjoying new life without any morbidity.

Conclusion: Thus, we concluded that interventional methods of suitably selected case of congenital heart disease may be an alternative lucrative safe & effective option of remedy for many of the congenital heart diseases.

(*Cardiovasc. j.* 2014; 6(2): 133-142)

Introduction:

Surgical method of treatment of CHD is an established method. But non-surgical device closure is an alternative mode replacing the surgical method.¹ Surgical method has the more morbidity and mortality than the device closure. Surgery is subjected to complication of cardio pulmonary by pass (CPB) which not infrequently leads to perfusion injury to brain and other vital organs.² Moreover, the hazards of blood transfusion, prolonged anesthesia, prolonged hospital stay, & psychological trauma to the

patients/parents, finally the ugly scar on chest preclude the final outcome of surgical closure.³ Device closure is a new mode of treatment of shunt anomalies particularly PDA, ASD (secondum), ventricular septal defect (VSD). The era of intervention in pediatric cardiology started in 1966 by Dr. William Rashkind with the advent of balloon atrial septostomy & by Portsman et al in 1967 with non-surgical PDA closure by Ivalon plug.^{4,5} Since then lot of innovations/ bioengineering modifications of different devices with animal studies were done to ensure the

safety & efficacy of devices for human use until 2001, when FDA has approved this method of treatment.⁶ The area of pediatric cardiac interventional treatment has been extended from closure ASD/VSD/PDA & valvuloplasty to closure of Rupture sinus of valsalva,⁷ Aorto-Pulmonary (AP) window,⁸ Coronary Cammeral fistula,⁹ PDA stenting in Pulmonar atresia,¹⁰ Percutaneous Pulmonary Valve Replacement (PPVR),¹¹ & Percutaneous Aortic Valve Replacement (PAVR).¹² Further it has been extended up to Hybrid procedures along with surgeon for the treatment large VSD/ ASD closure in very young Infant, Palliation in Hypoplastic Left heart syndrome with PDA stenting & surgical bilateral pulmonary artery banding,¹³ & Fontan Completion.¹⁴ As the interventional procedure is costly compared to surgical one, so the number of intervention is less in our center with respect to total patient load. We are presenting our initial experiences & outcome of pediatric cardiac interventions at NICVD.

Methods & Materials:

Patients with congenital heart diseases both inpatient and outpatient department of NICVD were scrutinized with Echocardiography to find out the suitable candidate for Interventional treatment. In January 2005, we first performed the device closure method with PDA. Since then, till December 2013, we performed 150 cases of PDA device closure, 60 cases of ASD device closure, 20 cases of PDA coil closure, 90 cases of Balloon Pulmonary Valvuloplasty, 20 cases of Aortic Balloon Valvuloplasty, 22 cases of Coarctation Balloon Angioplasty, 35 cases of PTMC & 15 cases of BAS. Among these, double interventions, ASD device closure with BPV was done in 2 cases & PDA device with Coarctation Balloon Angioplasty done in 4 cases, Aortic Balloon Valvuloplasty & PDA device closure in 2 patients & one case of Double ASD device closure in a single patient. Two cases of PM VSD closure were also attempted but one failed & one was successful with ADO II. Cases for device closure of PDA were selected on the basis of size & morphology of PDA determined with Echo & Angiocardiography. More than 2.5 mm sizes were selected for device closure with Amplatzer Duct Occluder (ADO) & less than 2.5 mm size PDA were subjected for coil closure with Cook's detachable coil. For ASD device closure, cases were selected with Trans-thoracic & Trans-esophageal Echo assessment of different rims of ASD for suitability of device closure as well as

sizing of the defect. Balloon sizing for selection of size of the ASD device was done in two cases only. ASD size was measured with TEE along with colour flow mapping (CFM) and then 2-4 mm more was added for appropriate size selection of ASD. For selection of size of PDA device, we added 2-3 mm more to the diameter of the pulmonary end of the PDA. Among PM VSD cases, one was 3x4 mm size with 3mm distance from Aortic valve & other was 5x6 mm in size having 4-5 mm distance from aortic valve. In first case we failed to cross the VSD but in second case it was , successful with 6/6 mm (Diameter/Length) Amplatzer Duct Occluder 11 (ADO II).

For pulmonary Balloon Valvuloplasty, size of the balloon was selected on the basis of Echo/ Angiographic measurement of the pulmonary valve annulus. In most of the cases of infant & pediatric patient we multiply with 1.25 times more than that of the pulmonary annulus. But in older patients than 10 years we selected multiplying 1.5 times than that of pulmonary annulus. For Aortic Balloon Valvuloplasty, the size of the balloon was determined on the basis of 0.8-0.9% of the aortic annulus or the size of the abdominal aorta at the level of Diaphragm measured by Echo/ Angiography. All but 6 of the Aortic balloon valvuloplasty were done with temporary overdrive pacing through right heart catheterization. For the Balloon Coarctoplasty, we measured the size of transverse arch/ size of the abdominal aorta at the level of Diaphragm to determine the size of the balloon. For PTMC, cases were selected on the basis of Echo findings, valve morphology of severity, pliability, absence of calcification & severity of mitral regurgitation. The size of the Innoe balloon was selected on basis of the height of the patients in centimeter divided by ten & then adding ten in mm. All the Balloon Atrial Septostomy patients were having d-TGA, IVS except one who has TAPVC with PFO. Most of our patients required general anesthesia except a few patients.

Results:

In January 2005, we performed the first device closure of PDA. Since then, till December 2013, we performed 150 cases of PDA device closure, 60 cases of ASD device closure, 20 cases of PDA coil closure, 90 cases of Balloon Pulmonary Valvuloplasty, 20 cases of Aortic Balloon Valvuloplasty, 22 cases of Coarctation Balloon Angioplasty, 35 cases of PTMC & 15 cases of BAS. Among these, double interventions, ASD

device closure with BPV was done in 2 cases & PDA device with Coarctation Balloon Angioplasty done in 4 cases, Aortic Balloon Valvuloplasty & PDA device closure in 2 patients & one case of Double ASD device closure in a single patient.

Out of 150 cases of PDA device closure patients (Table-I), 143 (95.3 %) resulted immediate complete closure of shunts. 7 (4.7 %) patients developed complications including one death of a young infant of 8 months old. The death was due to complication of anaesthesia and hypotension related to prolonged unsuccessful procedure to a large tubular PDA. In PDA Coil closure (Table-II) of 20 patients, 17 (85%) patients had complete closure, but only 2 (10%) patients had minor residual shunts after 6 months follow-up with Echo-color Doppler study. One embolized PDA device to right middle lobe artery was retrieved surgically with closure of PDA. In one case ADO embolized to right lower lobar branch of pulmonary artery to a 15 months old baby. We tried to retrieve it with an amplatzer goose neck snare but failed & patient became hemodynamically unstable & we abandoned the procedure. She was resuscitated with blood transfusion & kept overnight at ICU on monitor

along with heparin infusion & antibiotics with an intention to go for surgery. But on the following day, she showed no sign of desaturation, so the decision of surgery was deferred anticipating extensive tissue injury to explore out the embolized device from lower middle lobar pulmonary artery. Then the baby was taken again to cath lab & a larger size (10x8) ADO was implanted successfully with complete closure. Right Pulmonary angiogram showed partial obstruction to distal flow, so we abandoned the idea to retrieve the embolized device. On subsequent follow-up with CT pulmonary angiogram & Lung perfusion scan with Tech-99 after 3 month showed only 5 % less perfusion in right lung than the left lung & normal arterial blood gas analysis & SPaO₂. Two patients, one with device & another with coil closure developed intravascular hemolysis & hemoglobinuria resulting into anemia / mild jaundice requiring blood transfusion. Coil closure patient had residual shunt which was surgically retrieved but device patient had no obvious residual shunt across device on Echo-color Doppler study. On conservative treatment hemoglobinuria stopped on the 5th day.

Table-I
Results of PDA Device closure (n= 150).

No of pt.	Age Range	Sex ratio (F:M)	Size of PDA (mm)	Size of device (Mean)	Complete closure, immediately	Complications					P-value
150	6m-50y	1.9:1	3-12 mm	8#4-10#4mm	143 (95.3%)	7 (4.7 %)					<0.001
						Failed	Embolized	Hemoglobinuria shunt	Residual	Death	
						2(1.3 %)	2(1.3 %)	1(0.66%)	1(0.66%)	1(0.66%)	




Fig.1: *Different types of Amplatzer Duct Occluder (ADO)*

Table II
Results of PDA Coil closure (n=20).

No of patients	Age Range	Sex ratio M : F	Size of PDA (mm)	Size of Coil	Complete closure	Residual Shunt	Persisted Intravascular Hemolysis	P value
20	5m-1y	2 : 1	1.8-3.0 mm	3/5mm-4/5mm	85 %	10 %	5 %	<0.001

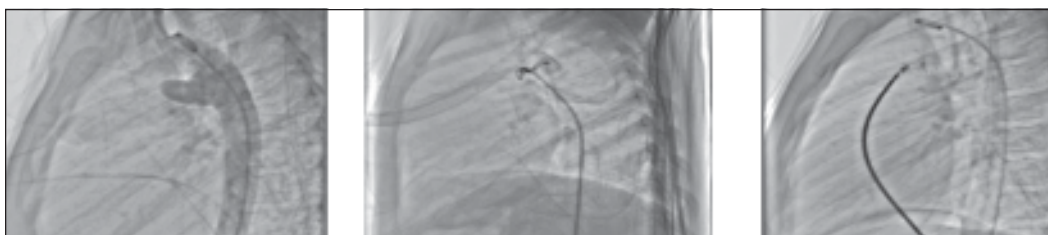


Fig.-2: 2A.PDA- Angio, B. PDA-Coil Closure, C. PDA-Device Closure

Out of 60 cases of ASD device closure (Table-III), 56 cases had successful implantations without any morbidity. 2 cases failed due to unsuitability of rims. In 2 cases of embolization of device occurred. A case of large ASD (24mm) in a 3 years old girl, 28 mm ASO was embolized to RV attaching partially on the Tricuspid valve. This was retrieved surgically with closure of ASD after 3 hours. Another case of 12 years old girl had embolization of 16 mm ASO after 24 hours to PA & it was successfully retrieved by our surgeons with patch closure of ASD. On follow-up, no patient has any residual problem.

We attempted device closure of two perimembranous VSD (PM VSD) cases, one was 3.0 x 4.0 mm size with 3mm distance from Aortic

valve & other was 5.0 x 6.0 mm in size having 4-5 mm distance from aortic valve. In first case we failed to cross the VSD but in second case it was successful with 6/6 mm (Diameter/Length) Amplatzer Duct Occluder II (ADO II) without any residual problem.

In pulmonary balloon valvuloplasty (Table-IV & Fig-5), out of 90 patients, the Mean pre-balloon, PV annular size was 14 ± 6.0 mm. Mean balloon diameter was selected 15 ± 5.0 mm. Mean pre balloon gradient was 67 ± 25 mmHg. Mean post balloon gradient was 28 ± 18 mmHg & after 1 year follow up it was 26 ± 15 mmHg with a significant p value <0.001 . Only 10 (9%) patients had trivial to grade I pulmonary regurgitation. Only 5 (4.5%) required re-intervention with surgery for significant restenosis.

Table-III

Results of ASD Device closure.

No of patients	Age Range	Sex ratio F:M	Size of ASD mm	Size of Device	Successful case	Failed case	Embolized	P value
60	3Y-55y	1.5:1	14-32 mm	18-34 mm	93 %	2 (3.5%)	2 (3.5 %)	<0.001

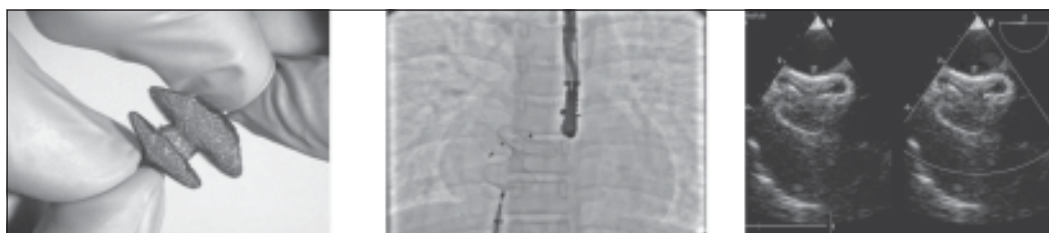

Fig.-3: A. ASD Device, B. Double ASD Device Closure, C. Confirmation on TEE

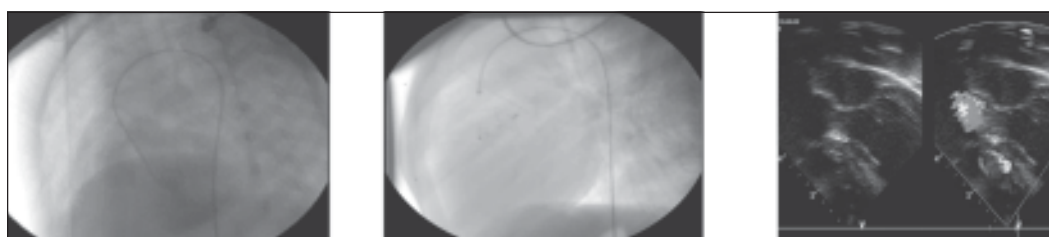


Fig.-4: A. PM VSD, B. VSD Closure, ADO-II in situ, C. Echo Confirmation

Table-IV
Results of Pulmonary Balloon Valvuloplasty (BPV)

No of patients	Age Range	Sex Ratio (F:M)	Mean PV Annulus	Mean Balloon size	Mean Pre-Balloon gradient	Mean post-Balloon gradient	P value
90	6m-24yrs	1.25:1	14± 6.0 mm	15± 5.0 mm	67± 25 mmHg	28±18 mmHg	<0.001

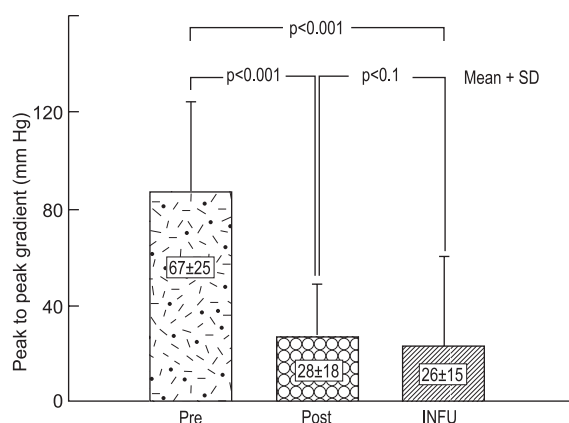


Fig.-5: Mean pressure gradient fallen from pre-balloon to immediate post-balloon & follow up after 1 year.

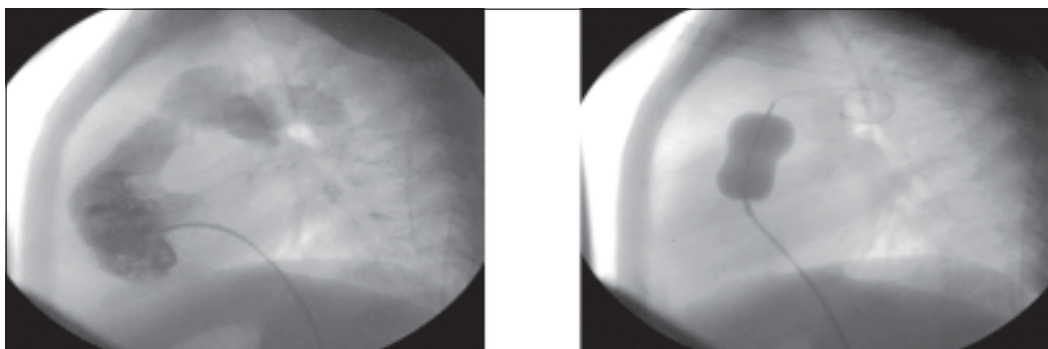


Fig.-6: percutaneous transluminal Pulmonary valvuloplasty.

In Aortic Balloon Valvuloplasty (Table-V) involving 20 cases, the mean pre-balloon AV annular size was 11 ± 3.0 mm. Mean balloon diameter was 12 ± 4.0 mm. Mean pre balloon gradient was 60 ± 25 mmHg. Mean post balloon gradient was 30 ± 15 mmHg. Only 2 (10%) patients developed trivial AR. All patients except 6 cases, the procedure were assisted with rapid RV pacing up to 180-210 with fall of BP around 50-60% of the baseline blood pressure for the maintenance of balloon stability across aortic valve. There was no complication associated with this overdrive rapid right ventricular (RV) pacing.

In Coarctation Balloon Angioplasty (Table-VI), out of 22 cases, the mean pre-balloon diameter

was 14 ± 4.0 mm, Mean pre balloon gradient was 70 ± 25 mmHg. Mean post balloon gradient was 40 ± 15 mmHg with a significant p value of <0.001 .

In 35 cases of Percutaneous Transvenous Mitral Commisurotomy (PTMC) (Table-VII), mean pre-balloon mitral valve area was 0.98 ± 0.3 cm², which increased to 2.16 ± 0.9 cm². Mean pre-balloon trans-mitral pressure gradient also significantly decreased from pre-balloon 22 ± 8.0 mmHg to post balloon 12 ± 4.0 mmHg with a p value of <0.001 . Out of 35 patients in one patient, we faced non-deflation problem of proximal part of the balloon after the procedure & locked within LA. It was due to fracture of the shaft. We tried to rupture the balloon putting Brochenbour

needle & succeeded. But there was minor episode of cerebral air embolism due to which patient became restless /agitated. After giving sedation with Midazolam and overnight monitoring in ICU keeping head down, patient recovered without any residual neurological deficit. There was no mortality/major morbidity.

In Balloon Atrial Septostomy (BAS), (Table-VIII), out of 15 patients, the procedure in one patient failed & in other one the procedure was abandoned due to anesthetic overdoses followed by cardiac arrest in cathlab but recovered after resuscitation. In 13 patients, the procedures were successful increasing Oxygen saturation mean of $60\% \pm 15\%$ to $78\% \pm 10\%$ with p value of <0.05 .

Table-V
Results of Balloon Aortic Balloon Valvuloplasty.

No. of patients	Age Range	Sex Ratio (F:M)	Mean AV Annulus	Mean Balloon size	Mean Pre-Balloon gradient	Mean post-Balloon gradient	P value
20	5months-5yrs	1.5:1	11±3.0 mm	12±4.0 mm	60±25 mmHg	30±15 mmHg	<0.001

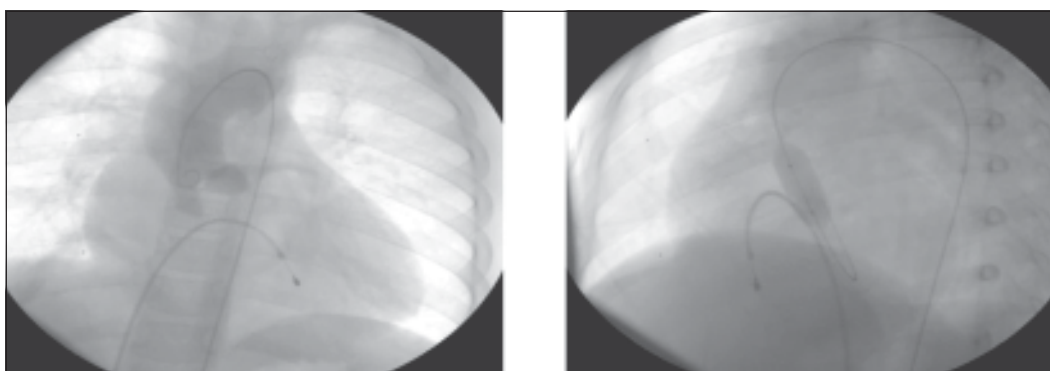


Fig.-7: *Percutaneous transluminal Aortic valvuloplasty.*

Table-VI
Results of Balloon Coarctoplasty

No of patients	Age Range	Sex Ratio (F:M)	Mean Transverse Arch diameter	Mean Balloon size	Mean Pre-Balloon gradient	Mean post-Balloon gradient	P value
22	1y-5rs	1:1.5	14±4.0 mm	14±4.0 mm	70±25 mmHg	40±15 mmHg	0.001

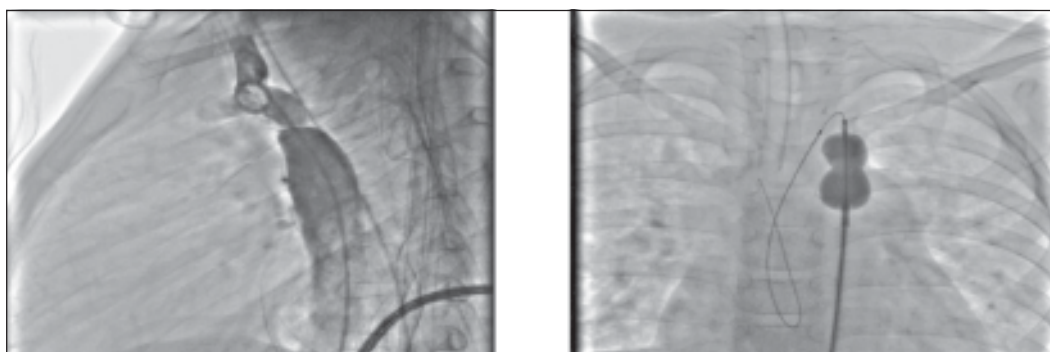

Fig.-8: *Balloon angioplasty of Coarctation of Aorta.*

Table-VII
Results of Percutaneous Transluminal Mitral Commissurotomy.

No	Age Range	Sex Ratio	Mean MVA cm2 area Pre- Balloon	Mean MVA cm2 area Post- Balloon	Mean Pre-Balloon gradient	Mean post-Balloon gradient	P value
35	7-15 Y	F:M2.1	0.98 +/-0.3	2.16+/- 0.9	22+/-8 mmHg	12+/-4 mmHg	<0.001

Table-VIII
Results of Balloon Atrial Septostomy (BAS)

No of patients	Age Range	Sex Ratio (M:F)	Pre-procedure SPAo2 Mean %	Post-procedure SPAo2 Mean %	Complication	P value
15	D1 -15	1.5:1	60 ±15	78 ± 10	Abandoned-1 Failed-1	<0.05

Discussion:

Surgery was the only gold standard method of treatment for treating congenital heart disease. But the recent advancement in Interventional methods of treating such lesions remarkably changed the scenario. There are a lot of advantages of interventional method over the surgical procedure particularly avoidance of cardiopulmonary bypass (CPB), prolonged anesthesia, thoracotomy / ugly scar & psychosocial trauma to the patients & parents. Although cost is an issue for interventional treatment but it can be minimized/subsidized with benevolent activity from government / Non-govt. organization.

The era of intervention in pediatric cardiac patient started with Balloon atrial septostomy in a TGA,IVS patient by Rashkind and Miller in 1966.⁴ Transcatheter closure of congenital cardiac shunt defect started with PDA closure by Portsmann et al by Ivalon plug in 1967⁵ followed by Raskind and Cuso by Umbrella type device in 1979.¹⁵ For smaller size PDA, use of coils started in 1992 by Cambier et al.¹⁶ For moderate to larger PDA closure subsequently newer safer devices & easy techniques of Transcatheter closure started with the advent of Amlatzer Duct Occluder (ADO),with least morbidity. Pas RH, Hijazi Z, Hsu DT et al in a multicenter study demonstrated the safety & efficacy of Transcatheter closure of PDA with ADO.¹⁷ In their series of 439 patients attempted,

435 were successful implantation of ADO. 78% had immediate closure, which increased up to 98% after one year. They had one peri-procedural death, 2.3% major events including 2 cases of embolization, bleeding in 2 patients requiring blood transfusion. In our series of 150 patients, we had one death resulting from anaesthetic hazard/hypotension due to prolonged procedural time. We had two cases device embolization. One case (10x8 mm size) was surgically retrieved with surgical ligation of PDA. Other 8x6 mm ADO device was embolized to lower middle lobe pulmonary artery was not retrieved. One case of PDA device resulted into Intravascular haemolysis with hemoglobinuria leading to anaemia/mild jaundice. As there were no obvious residual shunts across the device in Echo-Doppler study, we continue the conservative treatment & finally after 5 days haemoglobinuria ceased & patient was cured. Also, in one case of PDA coil closure with residual shunt developed into intravascular haemolysis with hemoglobinuria resulting into anemia/mild jaundice was surgically retrieved after 7 days. In a large series of 1291 patients from European Pediatric Cardiology Registry¹⁸ of PDA coil occlusion, 59% had immediate occlusion which increased up to 95% by one year follow-up. 10% had suboptimal outcome described as failure to implant, embolization, residual shunt or intravascular haemolysis/haemoglobinuria. In our series of 20 patients of

coil closures, 85 % had complete closure after 6 months follow-up with Echo. One randomized trial compared percutaneous closure of PDA to surgery. In this study from China, Chen et al¹⁹ compared 72 patients with device closure with 183 patients treated with surgery. More procedure related events were found in surgical group than device group (13.7% vs 1.4%), average recovery time was more prolonged in surgery group than device group (8.7 days vs 1.3 days). Freedom from residual shunt was higher in percutaneous group than surgery (98.6% vs 91.3%).

First ASD device closure was done by King & Mills in 1974.²⁰ Since then lot of research & modification of design of different devices occurred. Du ZD, Hijazi ZM, Klienmann CS et al in 2001 published the results of multi-center nonrandomized trial on Amplatzer Septal Occluder (ASO) indicating the safety & efficacy of percutaneous ASD closure with respect to surgical closure.²¹ Recently, Abaci & Unlu et al reported on multicenter meta analysis of 28,142 patients undergone ASD/PFO percutaneous device closure in 203 centers. Peri-procedural major complication found in 1.6% cases & most common were device embolization requiring surgery. The reported significant complication of ASD device closure include cardiac perforation, device malposition/ embolization, residual shunts, vascular trauma, thrombus formation with embolic events, AV valve or aortic valve regurgitation, atrial arrhythmia, infective endocarditis & sudden death.^{22,23} In our series, out of 60 patients attempted for ASD device closure, 56 were successful, in 2 patients abandoned the procedure due to unsuitable rims, in one patient, a 24 mm Amplatzer device embolized to RV, another 16 mm device embolized to PA, which were subsequently surgically removed with patch closure of ASDs. We had no mortality. On short term & intermediate follow up for 36 months one patient had trivial MR, two patients had nonspecific chest pain which subsequently improved.

Device closure of VSD started by Lock et al first in 1987.²⁴ There are two types of Amplatzer VSD devices, one for muscular device & one for PM VSD device having unequal LV/RV disc to avoid

injury to Aortic Valve. In both conventional methods arterio-venous loop is produced & ante grade approach via venous side is used for deployment of the device. In this method of PM VSD closure, incidence of complete heart block (CHB) is nearly 5%.²⁵ But recently non conventional use of ADO II in retrograde way for closure of PM VSD showed more promising result with no or very infrequent incidence of CHB.²⁶ We performed one case of PM VSD closure with ADO II with excellent outcome.

Pulmonary Balloon Valvuloplasty (BPV) provides long term relief of pulmonary valvular obstruction in the majority of patients. Brian W. McCrindle et al analyzed the long term outcome in 46 patients of BPV for congenital pulmonary valvular stenosis & found significant long-term reduction in trans-valvular gradient from 70 ± 36 mmHg to 23 ± 16 mmHg within 2 years & 20 ± 13 mmHg after 2 years.²⁷ In our series of 90 patients of BPV, we followed with Echo-color-Doppler up to 12 months and found significant reduction of transvalvular gradient from 67 ± 25 to 26 ± 15 mmHg ($p<0.001$) with symptomatic improvement.

First Balloon Aortic Valvuloplasty (BAV) for congenital Valvular AS was successfully performed by Lababidi in 1983.²⁸ Akbari Ashbag P, Shahmohammadi A in a comparative study of 115 patients between balloon valvuloplasty (48 cases) versus surgical (67 cases) aortic valvotomy showed the mean reduction in transvalvular gradient was greater in balloon group than surgical group (73.54 vs 45.03). Also there were less incidence of Aortic insufficiency; less morbidity & mortality in balloon intervention.²⁹ In our study we also found significant reduction in transvalvular gradient from 65 ± 25 to 30 ± 15 mmHg with symptomatic improvement. Rapid ventricular pacing to achieve balloon stability is also a safe & effective option & may reduce the degree of aortic incompetence by minimizing valve damage.³⁰ We also used this technique with good results.

Balloon Angioplasty in Coarctation of Aorta is an alternative to surgical repair in children. In a study of 8 neonates by Liang CD, Su WJ, Chang HT et al showed the significant reduction in transvalvular gradient from 36.4 ± 12.0 to $7.5 \pm$

6.0 mmHg ($p < 0.001$).³¹ In another study involving 26 patients by Hijazi, Z M, Fahey J T, Kleienman C S et al found Balloon Angioplasty useful in recoarctation.³² Our results involving 22 patients is comparable to these results with reduction of pre-balloon to post balloon transcoarctation gradient from 70 ± 25 to 25 ± 15 mmHg ($p < 0.05$) along with clinical improvement.

We also performed a few cases of multiple interventions in a single patient in a single setting without any morbidity & mortality.

Mitral stenosis is the commonest Rheumatic Valvular heart disease in developing countries including Bangladesh.³³ Until the early 1980s, surgery was the only possible treatment for severe valvular lesions; then a new alternative appeared as percutaneous balloon Valvuloplasty.³⁴ In moderate to severe form of MS, Percutaneous Transvenous Mitral commissurotomy (PTMC) may be the best way of palliation with good outcome and immediate relieve of symptoms. K. Inoue and colleagues were first to perform percutaneous mitral commissurotomy (PTMC) IN 1982.³⁵ In our series of 35 patients, we performed PTMC with Inoue balloon technique. There were significant increase in valvular area & decrease in transmitral valvular gradient with a p value < 0.001 . This result is comparable with the study of Kang & Park et al.³⁶ We had one incidence of hardware related complication which is rare in literature except in one article described by Gourage T, Subban V, Soliranjan R et al, who faced the similar problem of non deflation of proximal balloon.³⁷ This kind of hardware related complication is more common in multiple used/reused balloon. Korkmaz S, Sazmaz H, Aksu T et al in a large series of 577 cases of PTMC, found statistically significant increase in MVA than pre-procedural MVA with hemodynamic improvement in univariate & multivariate analysis ($p < 0.001$, HR:3.5).³⁸

Atrial septostomy is an emergency life saving procedure in many congenital heart diseases including d-TGA as a bridge to definitive procedure of Arterial Switch Operation (ASO). In a study of 192 patients of Balloon atrial septostomy (BAS) by Matter M et al shown that oxygen saturation increased from $65\% \pm 9\%$

$88\% \pm 3\%$ ³⁹. In our series of BAS there was significant increase in oxygen saturation from $65\% \pm 15\%$ to $78\% \pm 10\%$.

Conclusion:

It was evident from our studies that there is significant advancement in the field of pediatric cardiac interventional treatment. There is least morbidity & mortality in all kinds of pediatric cardiac interventional procedures. So in future more & more challenging interventional treatment, in structural & congenital heart disease can be performed successfully.

References:

1. Dugal TS, Jelty Sing C, Delta SK, et al. Amplatzer Device closure of ASD & Patent Ductus Arteriosus; Initial experience. *MJAFI* 2003; 59:218-222.
2. Welsby IJ, Bennett Guerrero E, Atwell D, et al. The association of complication type with mortality & prolonged stay after cardiac surgery with cardiopulmonary bypass. *Anesth Analg* 2002 May 94(5): 1072-1078.
3. Kazmi T, Sadiq M, et al. Intermediate & long term outcome of patients after device closure of ASD with specific reference to complication. *J Ayub Med Coll Abbottabad* 2009;21(3):117-121.
4. Rashkind WJ, Miller WW. Creation of an atrial septal defect without thoracotomy. A palliative approach to complete Transposition of Great Arteries. *JAMA* 1966; 196(11): 991-992.
5. Portsmann W, Wierny L, Warnke H. Closure of persistent ductus arteriosus without thoracotomy. *Ger Med Monthly* 1967; 12:259-261.
6. Barry Love. Nonsurgical Alternative to repair of congenital heart defects. *US Cardiology* 2005; 2(1): 1-6
7. Arora R, Trehan V, Mahash U, et al. Transcatheter Catheter closure of Rupture Sinus of Valsalva Aneurysm. *J Interv Cardiol* 2004; 17(1): 53-58.
8. Guruprashad DN, Subash VC, Shenoy A, et al. Transcatheter closure of A-P Window using Amplatzer device. *Catheter Cardiovasc Interv* 2003; 59(3): 402-405.
9. Stanton BP, Janathan R, John F, et al. Transcatheter closure of coronary artery fistulas. *J Am Coll Cardiol* 1992; 20(1): 205-209.
10. Alwi M, Haifa AL, Kandarella G, et al. Initial results & medium term follow-up of stent implantation of patent ductus arteriosus in duct dependent pulmonary circulation. *J Am. Coll Cardiol* 2004; 4 (2): 438-445 .
11. Mulder BJ, de Winter RJ, Wilde AAM, et al. Percutaneous Pulmonary Valve Replacement ; a new development in the life time strategy for patients with congenital heart disease. *Neth Heart J* 2007; 15(1) : 3-4.
12. Smith CR, Leon MB, Haache MJ, et al. Transcatheter versus Surgical Aortic Valve Replacement in high risk patients. *N Engl J Med* 2011; 364 : 2187-2198.

13. Honjo O, Christopher AC. Hybrid Palliation in Neonates with Hypoplastic Left Heart Syndrome; current strategy & out comes. *Korean Circ J* 2010; 40(3): 103-111.
14. Al Soufi B, Alfadley F, Al –Omrani et al. Hybrid management strategy for Percutaneous Fontan completion without surgery. *Ann Thorac Surg* 2011; 91(2): 566-572.
15. Rashkind WJ, Causo CC. Transcatheter closure of patent ductus arteriosus: successful use in a 3.5 kg infant. *Pediatr Cardiol* 1979; 1: 3-7.
16. Cambier PA, Kirby WC, Worthham DC, Moore JW. Percutaneous closure of the small (<2.5 mm) patent ductus arteriosus using coil embolization. *Am J Cardiol* 1992; 69: 815-816.
17. Pass RH, Hijazi Z, Hsu DT, Lewis V, Hallenbrand WE. Multicenter USA study, Amplatzer patent ductus arteriosus occlusion device trial: Initial and one year results. *J Am Coll Cardiol* 2004; 44: 513-519.
18. Magee AG, Huggon IC, Seed PT, et al. Transcatheter coil occlusion of arterial duct ; results of the European Registry. *Eur Heart J* 2001; 22(19): 1817-1821.
19. Chen ZY, Wu LM, Luo YK, et al. Comparison of long term clinical outcome between Transcatheter Amplatzer Occlusion & Surgical closure of isolated Patent Ductus Arteriosus. *Chin Med J (Engl)* 2009 ; 122 (10): 1123-1127.
20. King TP, Mills NL. Non-operative closure of Atrial Septal Defect. *Surgery* 1974; 75: 383-388.
21. Du ZD, Hijazi ZM, Klienmann CS, et al. Comparison between Transcatheter & surgical closure of Secundum Atrial Septal Defect in children & adult: results of multicenter nonrandomized trial. *J Am Coll Cardiol* 2002, 39: 1836-1844.
22. Abaci A, Unlu S, Alsancak Y, et al. Short & long term complications of device closure of Atrial Septal Defects & Foramen Ovale. *Catheter Cardiovasc Interv* 2013 Dec 1; 82(7):1123-1138.
23. Amin Z, Hijazi ZM, Bass JL, et al; Erosion of Amplatzer Septal Occluder device after closure of secundum atrial septal defects: review of registry of complication & recommendation to minimize future risk. *Catheter Cardiovasc Interv* 2004; 63: 4496-4502.
24. Lock JE, Black P, Mckay RG, et al. Transcatheter closure of ventricular septal defects. *Circulation* 1988; 78:361-368.
25. Satinder K Sandhu, Ziyad M Hijazi. Ventricular Septal Defect Closure: state of Art: Index FAC, Pediatric Cardiology, file://J:/Hijazi/VSD Hijazi.htm
26. Nageswer R K, Raghav P, Srinivas A, Karunakar V, et al. Retrograde Transcatheter closure of ventricular septal defects in children using the Amplatzer Duct Occluder II device. *J Am Coll Cardiol* 2012; 59(13s1):E814-E814.
27. Brian W, McCrindle, Jean S Kan. Long-term results after Balloon Pulmonary Valvuloplasty. *Circulation* 1991; 83:1915-1922.
28. Lababidi Z. Aortic balloon valvuloplasty. *Am Heart J* 1983; 104(4pt 1): 751-752.
29. Akbari Ashbag P, Shahmohammadi A. Assessment of balloon valvuloplast in comparison with surgical valvotomy for congenital aortic stenosis. *Acta Medica Iranica* 2004; 42(4): 289-294.
30. Metha C, Shebani S, Grech V, DeGiovani. How to achieve balloon stability in aortic valvuloplasty using rapid ventricular pacing. *Images Paediatr Cardiol* 2004; 6(4): 31-37.
31. Liang C D, Su WJ, Chang HT, et al. Balloon angioplasty for native coarctation of the aorta in neonates and infants with congestive heart failure. *Pediatr Neonatol* 2009; 50(4): 152-157.
32. Hijazi ZM, Fahey JT, Klienman CS, et al. Balloon Angioplasty for recurrent coarctation of aorta. Immediate & long-term results. *Circulation* 1991; 84: 1150-1156.
33. Carroll JD, Feldman T. Percutaneous mitral balloon Valvotomy and the new demographics of mitral stenosis. *JAMA* 1993; 270: 1731-1736.
34. Alec V, Igor F, Palacios. Review: Clinical Cardiology: New Frontiers; Percutaneous Approaches to Valvular Disease. *Circulation* 2004 ; 109:1572-1579 .
35. Ianoue K, Owaki T, Nakamura T, et al. Clinical application of transvenous mitral commurotomy by a new balloon catheter. *J Thorac Cardiovasc Surg* 1984; 87:394-402.
36. Kang DH, Park SW, Song JK, et al. Long term clinical & Echocardiographic outcome of percutaneous mitral Valvuloplasty randomized comparison of Inoue & double balloon technique. *J Am Coll Cardiol* 2000; 35(1):169-175.
37. George T, Subban V , Soliranjana R, et al. Interesting balloon hardware related complications in percutaneous balloon mitral vulvuloplasty ; Global Interventional oral presentation,(OP-022). *Turk Kardiyol Dern Arn* 2010;suppl 2 : 24.
38. Korkmaz S, Sasmaz H, Aksu T, Colak A, et al : Acute results of percutaneous mitral balloon valvuloplasty : A single center study; Global Interventional oral presentation,(OP-022). *Turk Kardiyol Dern Arn* 2010; suppl 2: 25.
39. Matter M, Almarsafawvy H, Hafez M, et al. Balloon atrial septostomy: The oldest cardiac interventional procedure in Mansoura. Downloaded from <http://journals.tums.ac.ir/> monday, December 09, 2013.