

# Isolated Protein S Deficiency –Cause of Recurrent Stent Thrombosis-A Case Report

A K Choudhury, M Khalequzzaman, S Hasem, M Akhtaruzzaman, S Jannat

Dept. of Cardiology, NICVD, Dhaka.

## Abstract:

**Key Words :**  
Stent  
thrombosis,  
Protein b  
deficiency.

*Stent thrombosis (ST) is one of the major complications that occur in percutaneous coronary interventions (PCIs) with stents. Various factors have been attributed to the development of ST, and several strategies have been recommended for its management. Protein C or protein S deficiencies may uncommonly be responsible for coronary arterial thrombosis. We report a young woman with recurrent stent thrombosis due to the deficiency of protein S. After coronary stenting, stent thrombosis occurred two times despite aggressive medical therapy. This report suggests that the deficiency of protein C or S should be born in mind in a young patient with recurrent thrombotic events, and that anticoagulants in addition to antiplatelet agents considered in the presence of their deficiency.*

*(Cardiovasc. j. 2014; 6(2): 175-179)*

## Introduction:

In 1977, Di Scipio et al in Seattle first purified a new glycoprotein from human plasma which was named protein S, in reference to its isolation and characterization in Seattle. Protein S is a vitamin K-dependent anticoagulant protein. Its major function is as a cofactor to facilitate the action of activated protein C on its substrates, activated factor V (F Va) and activated factor VIII (F VIIIa). Protein S deficiency usually manifests clinically as venous thrombo-embolism (VTE). A deficiency of Protein S predisposes to recurrent venous thromboembolism and fetal loss. Though few researchers have reported a relationship between protein S deficiency and arterial thrombosis, association of Protein S with arterial thrombosis is less appreciated.<sup>1,2</sup> Acute myocardial infarction due to Protein C and/or Protein S deficiency has been reported in the literature.<sup>3-10</sup> Here, we report a case of patient with ST-segment elevation myocardial infarction who underwent percutaneous coronary intervention (PCI) and developed recurrent ST despite optimal medical therapy. Protein S deficiency was found to be the precipitating factor for recurrent ST in this case.

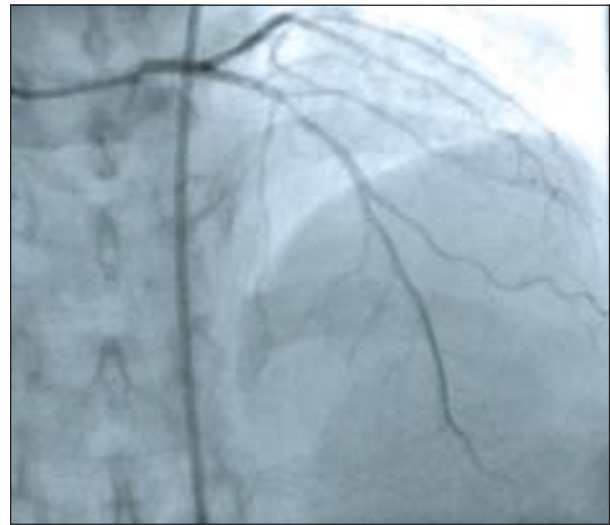
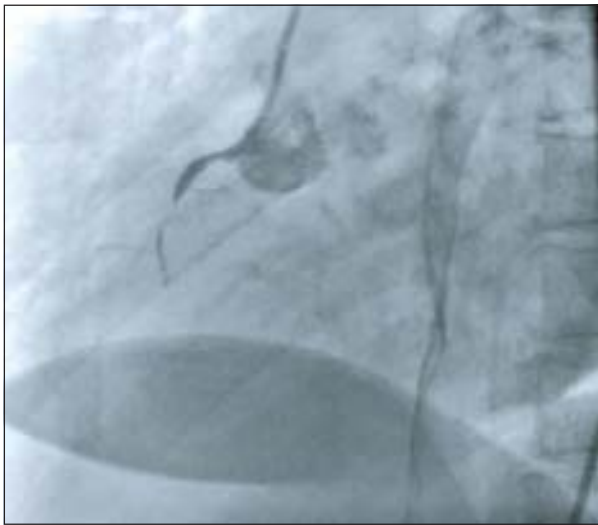## Case report:

A 36-year-old woman presented with chest tightness that had occurred 4 hours ago. She was regularly menstruating and had no major cardiovascular risk factor like hypertension,

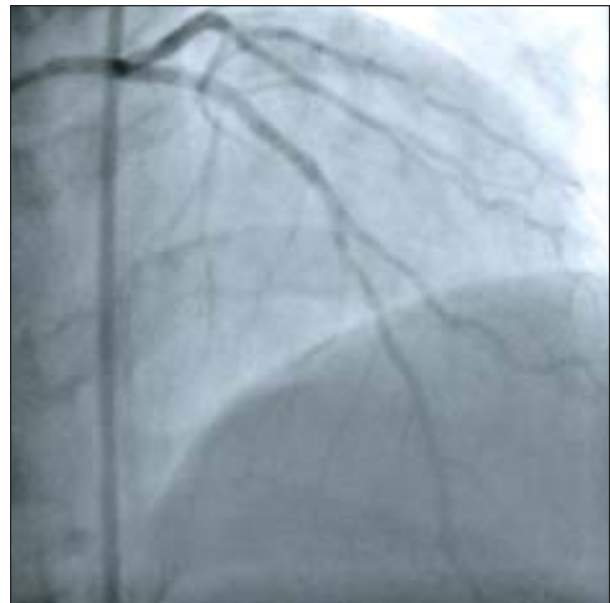
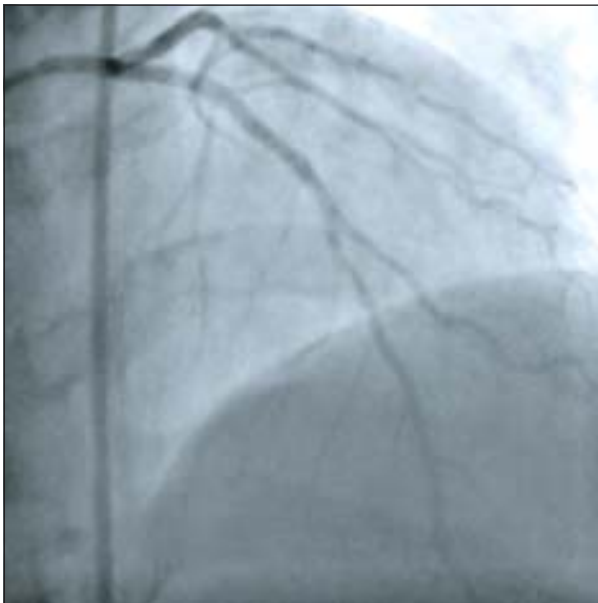
diabetes mellitus, dyslipidemia, smoking, family history of premature CAD. There was no history of taking oral contraceptives, cocaine or other drugs leading to thrombotic events. Further, she did not taking any drugs that could deteriorate the platelet function. Her blood pressure was 140/80 mmHg, and her pulse rate was 80 beats per minute. Electrocardiography (ECG) revealed a AMI (inferior) with RVI. Echocardiography revealed inferior wall hypokinesia with EF-56%. Her plasma Troponin I level was 8.9ng/mL. On admission, she received 300 mg aspirin and 300 mg clopidogrel with thrombolysis by streptokinase which was not successful. Subsequently, she continued to receive aspirin 75 mg/day and clopidogrel 75 mg/day. One month after admission, coronary angiography (CAG) revealed 70% stenosis in mid portion of the left anterior descending artery (LAD) and 100% stenosis in the proximal segment of the right coronary artery (RCA) (Fig. 1A & 1B). Cobalt Chromium (CC) stent in LAD (3.0/20mm) and RCA (3.0/20 mm) were implanted. TIMI grade 3 flow was established and there was no residual stenosis in final angiogram (Fig. 2A & 2B). Two months after the PCI, the patient admitted with chest pain and ECG evidence of ST segment elevation in leads V1- V4. The second angiography revealed total occlusion of stent in LAD and RCA (Fig. 3A & 3B). Angiographic appearance of occlusion site was compatible with thrombus. PCI using a Drug Eluting Stent (DES)

(3.0/24 mm) at 18 ATM in LAD and RCA (3.0/25mm) at 14 ATM was performed successfully (Fig.4A & 4B ). It is worthwhile to mention that she was getting dual antiplatelet therapy (DAPT) regularly. One month after this procedure patient developed anterior myocardial infarction with LVF. After stabilization Re-look CAG showed sub acute occlusion of stent by thrombus in LAD but RCA stent was patent (Fig .5A & 5B ). Revascularization was not possible at this time.

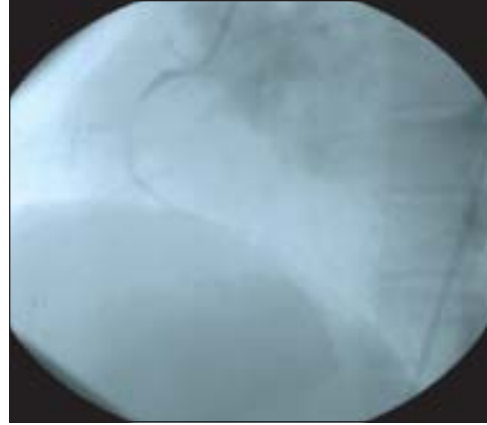
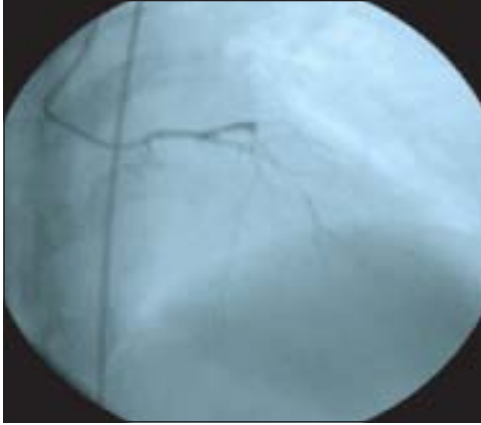Further laboratory investigations found that complete blood count, blood chemistry, lipid profile, homocysteine, ANA, ANCA, VDRL and thyroid stimulating hormone, were all within normal limits. Anticardiolipin antibodies, protein C, Platelet function assay, antithrombin III was also normal but her protein S concentration was 15 % of the mean value (normal 60–130%). Oral anticoagulant was started along with other cardiovascular drugs.



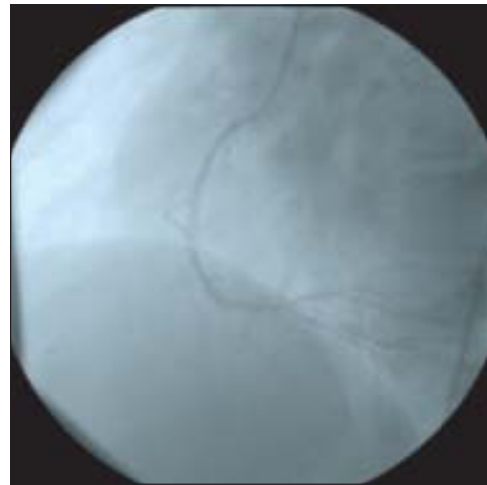
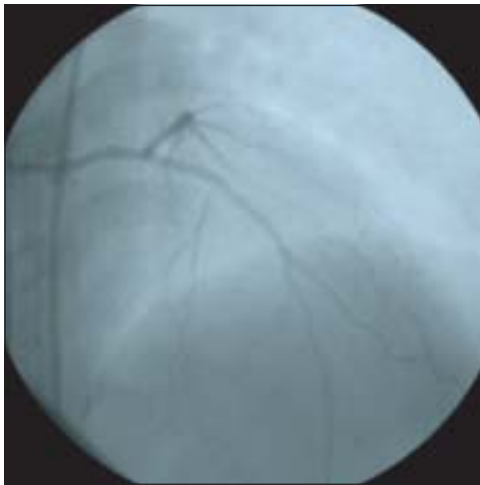**Fig.-1A & B:** CAG revealed 70% stenosis in mid LAD and 100% stenosis in the proximal RCA.



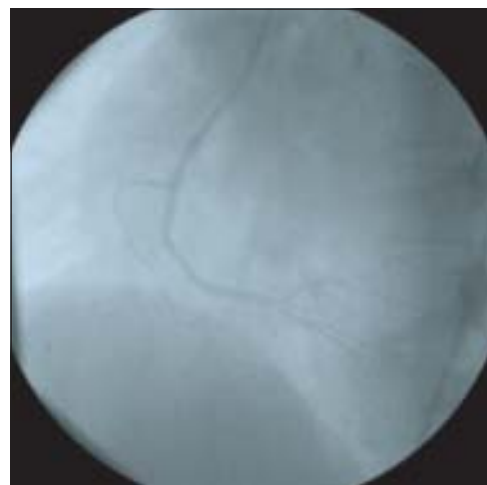
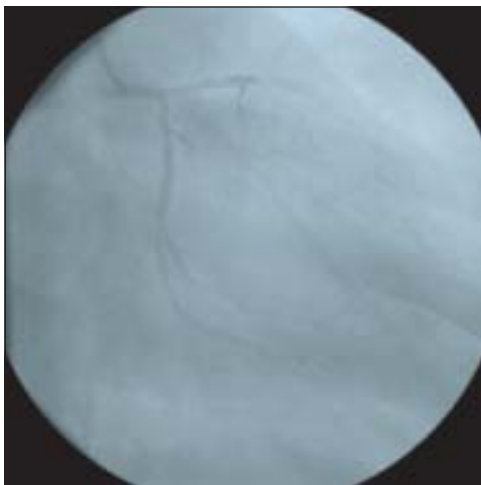
**Fig.-2A & B:** TIMI grade 3 flow established with no residual stenosis in LAD and RCA.



**Fig.-3A & B:** CAG revealed total occlusion of stent in LAD and RCA.



**Fig-4 A & B:** PCI using a Drug Eluting Stent in LAD (3.0/24mm) and RCA(3.0/25mm).



**Fig 5A & B:** CAG showed total occlusion of stent in LAD but RCA stent was patent.

**Discussion:**

Congenital protein S deficiency is an autosomal dominant disease, and the heterozygous state occurs in approximately 2% of unselected patients with VTE. Protein S deficiency is rare in a healthy population without abnormalities. The frequency is approximately 1 out of 700 based on extrapolations from a study of over 9000 blood donors who were tested for protein C deficiency. When looking at a selected group of patients with recurrent thrombosis or a family history of thrombosis, the frequency of protein S deficiency increases to 3-6%.<sup>8</sup> Very rarely, protein S deficiency occurs as a homozygous state, and these individuals have a characteristic thrombotic disorder, purpura fulminans. Purpura fulminans is characterized by small vessel thrombosis with cutaneous and subcutaneous necrosis, and it appears early in life, usually during the neonatal period or within the first year of life.<sup>9</sup> During physiological harmony, protein S (cofactor) combines with protein C (serine protease) which then binds to factor Va and VIIIa. Protein S/protein C complex splits factor Va and VIIIa preventing activation of factor X and thrombin, thus preventing thrombosis during the normal state. During deficiency the said mechanism fails, resulting in thrombosis. In healthy individuals, approximately 30–40% of total protein S is in the free state. Only free protein S is capable of acting as a cofactor in the protein C system. This distinction between free and total protein S levels is important and gives rise to the current terminology regarding the deficiency states. The congenital deficiencies of protein S are classified in three types.<sup>10,11</sup> Type I deficiencies correspond to reduced antigen levels of both total and free protein S; type II deficiencies are characterized by reduced protein S activity but with normal antigen levels of both total and free protein S; type III deficiencies are defined by a reduced antigen level activity of free protein S but the antigen level of total protein S remains normal. Acquired protein S deficiencies are associated with several clinical states: Oral warfarin therapy in initial few days, liver disease, disseminated intravascular coagulation, oral contraceptives, oestrogen therapy, acute phase inflammatory responses, pregnancy, HIV and

sickle cell disease. Venous thrombosis develops in 60–80% of patients who are heterozygous for protein S deficiency. The remaining patients are asymptomatic, and some heterozygous individuals never develop VTE. There is controversy regarding clear association between protein S deficiency and arterial thrombosis. Protein S deficiency is also associated with fetal loss in pregnant women. Protein S deficiency is a hereditary disorder, but the age of onset of thrombosis is different in heterozygous or homozygous state. Most venous thrombosis events in heterozygous protein S deficiency occur in persons younger than 40–45 years. The rare homozygous patients have neonatal purpura fulminans, with onset in infancy. Gurkan et al. reported a case of young woman of 33 years with recurrent acute stent thrombosis due to the deficiency of protein C and S. After coronary stenting, stent thrombosis occurred two times despite aggressive antiplatelet therapy, including aspirin, clopidogrel and glycoprotein IIb/IIIa inhibitor. This report suggests that the deficiency of protein C and S should be born in mind in a young patient with recurrent thrombotic events, and that anticoagulants in addition to antiplatelet agents considered in the presence of their deficiency.<sup>11</sup> Our case also similar in respect of age and sex who developed recurrent stent thrombosis. The exact incidence of the protein S deficiency in the Bangladeshi population is not known. The association of Protein S deficiency and thromboembolic diseases was reported in several families by Comp, Brokemans, Batard and P K Lieu.<sup>12</sup>

**Conclusion:**

A patient undergoing acute or subacute stent thrombosis in emergent percutaneous interventions may have fatal results. Though thrombophilia screening for the prevention of ST is unlikely to become routine, it might be considered on a case-to-case basis for the prevention of ST recurrence. Owing to the rarity of ST and of its clinical impact on patient prognosis, a complete evaluation of hemostasis (platelet and coagulation) might be justifiable to tailor the choice of anti-thrombotic prophylaxis, at least until validated guidelines to handle post-ST anti-thrombotic prophylaxis are available. We want to emphasize that protein S deficiency

should be considered as one of the etiological factor in a young patient with recurrent thrombotic events, and that anticoagulants in addition to antiplatelet agents considered in the presence of their deficiency.

---

**Conflict of Interest - None.**

---

**References:**

1. Schwartz HD, Fischer M, Hopneies P, Bartard MA, Griffin JH. Plasma protein S deficiency in familial thrombotic disease. *Blood* 1984; 64:1297-1300.
2. Comp PC, Nixon RR, Cooper MR, Esmon CT. Familial protein S deficiency is associated with recurrent thrombosis. *J Clin Invest* 1984; 74: 2082–2088.
3. Bertina RM, Reinolda Poot, Engesser L, Muller HP, Leeow J A. Hereditary protein S deficiency venous thromboembolism. A study in the dutch family. *Thromb Haemostasis* 2005; 1-7.
4. Coller BS, OwenJJ, Esty J, Horowitz D, Raitman MJ, SpearJ. Deficiency of plasma protein S , Protein C or Antithrombin III and arterial thrombosis. *Arteriosclerosis* 1987; 7(5): 456-462.
5. Manucci PM, Tripodi A, Bertina RM. Protein S deficiency associated with “juvenile” arterial and venous thrombosis. *Thromb Haemostasis* 1986; 55:440.
6. Israels SJ, Seshia SS. Childhood stroke associated with protein C or S deficiency. *J Pediatr* 1987;111: 562–564.
7. Siorioni P, Lasserro AR, Cordiano J. Severe arterial cerebral thrombosis in a patient with protein S deficiency. A family study. *Throm Haematology*.1989;61:144-147.
8. Lijfering WM, Ten Kate MK, Kluin-Nelemans HC, Veeger NJ , Vandermees J. High long term absolute risk of recurrent venous thromboembolism in patient with hereditary deficiency of protein C, protein S or Antithrombin. *Thromb Haemostasis* 2009; 101(1) :93-99.
9. Edlich RF, Cross CL, Dahlstream JJ, Long WB. 3<sup>rd</sup> Modern concept of the diagnosis and treatment of purpura fulminans. *J Environ Pathol Tox* 2008; 27(3):191-196.
10. Lane DA, Manucci PM, Bouer KA, Bertina RM, Bochkounp & Boulyjenkev V. Inherited thrombophilia. Part 1. *Haematology* 1996; 76:651-662.
11. Gurcan A, Abdullah D, Ahmet A & Yasin T. Recurrent cerebral thrombosis associated with protein C & S deficiencies. *Int J Cardiovas Imag* 2006; 22: 333-337.
12. Lieu PK, Lee SH, Tan CVB, Tan ES. Recurrent cerebral thrombosis associated with protein S deficiency in Chinese female. *Singap Med J* 1992; 33: 418-419.