

Role of Echocardiographic Imaging in Percutaneous Balloon Mitral Valvotomy

Satyavan Sharma, Satishkumar Suresh Kolekar

Department of Cardiology, Bombay Hospital Institute of Medical Sciences, Mumbai, India.

Abstract:

Key Words :

*Echocardiography,
Mitral valve,
Percutaneous
Balloon Mitral
Valvotomy.*

Mitral stenosis (MS) is a still frequently encountered in India and Bangladesh. Untreated MS contributes to the morbidity and mortality. Balloon mitral Valvotomy is effective and commonly used for relief of obstruction in symptomatic patients. The case selection is guided by clinical characteristics and imaging. Echocardiography is the most important imaging modality to assess severity of obstruction its hemodynamic consequences as well as valve morphology. Transthoracic two dimensional echocardiography is usually sufficient to provide the desired information. Trans esophageal echocardiography is used when the valve cannot be adequately assessed by trans thoracic echocardiography and to exclude intracardiac thrombi prior to intervention. Three dimensional transthoracic and trans esophageal echocardiographic assessment provides more elaborate physiological and morphological information.

(Cardiovasc. j. 2015; 7(2): 128-136)

Introduction:

The rheumatic fever (RF) and rheumatic heart disease (RHD) continue unabated in the regions of the world where poverty, overcrowding and low socioeconomic circumstances persist. Rheumatic mitral stenosis (MS) is the most common heart disease in the developing countries. Globally, there are more than 15 million cases of RHD, with 233,000 deaths each year and 282,000 new cases per year.¹ The MS is a progressive disease which leads to pulmonary hypertension (PH), congestive cardiac failure (CCF), atrial fibrillation (AF) or embolism and carries a poor prognosis without intervention.

The closed mitral commissurotomy (CMC) was first described by Harken and Bailey.² Subsequently after the advent of cardio-pulmonary bypass, the open surgical commissurotomy replaced the closed technique in many centers. Percutaneous balloon mitral Valvotomy (BMV) was introduced in 1984 by Japanese surgeon, Kanji Inoue and the technique has emerged as a safe and effective treatment for MS.³

The focus of this article is on echocardiographic imaging for the selection of suitable patients for BMV and on the periprocedural and the follow up

aspects of BMV. The echocardiographic imaging modalities which are available and useful in BMV procedure are shown below. The article will be discussed under the following heads:

1. Echocardiography in case selection.
2. Role of echo imaging during transseptal catheterization.
3. Utility of echocardiography in balloon mitral valvotomy procedure.
4. Echocardiography in assessment of results and follow up.

Echocardiographic modalities available for evaluation of Mitral valve:

- Trans thoracic M – mode, 2D, 3D echocardiography.
- Trans esophageal M-mode, 2D, 3D echocardiography.
- Doppler echocardiography (Continuous wave , Pulse wave, Color).
- Stress echocardiography.
- Intracardiac echocardiography.

1. Echocardiography in case selection :

Patient selection for the BMV is guided by both the clinical and anatomic features. It is usually recommended for the symptomatic individuals. The recent ACC, AHA guidelines provide elaborate recommendations for intervention in MS according to the symptomatic status, valve area and the morphology.⁴ Rheumatic MS results from the affection of commissures, cusps, chordae and the papillary muscles. Fibrotic process tends to involve all the structures resulting in a funnel shaped mitral orifice (Fig 1).

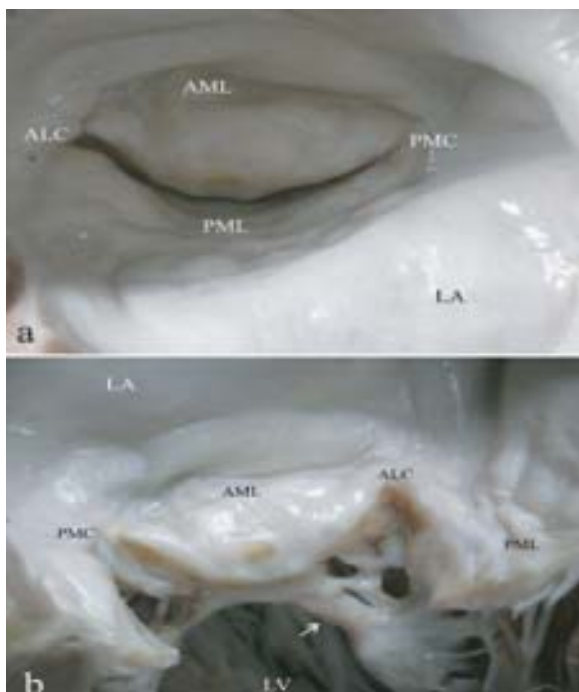


Fig.-1a and 1b: Pathology of mitral stenosis.

1a. Mitral valve viewed from left atrial (LA) aspect shows crescentic appearance of the valve orifice.
1b. The opened out valve highlights the commissural and chordal fusion (arrow) and leaflet thickening. (AML = Anterior mitral leaflet, PML = Posterior mitral leaflet, ALC = Antero-lateral commissure, PMC = Postero-medial commissure,

Two dimensional echocardiography (2DE) is the single most important imaging modality to evaluate the severity of mitral valve (MV) obstruction, its hemodynamic consequences, as well as valve morphology which defines the extent of the disease. Trans-thoracic echocardiography (TTE) is usually sufficient to grade MS severity and to define the

morphology of the MV. Trans-esophageal echocardiography (TEE) is indicated when the valve cannot be adequately assessed with TTE and to exclude intra-cardiac thrombi before a percutaneous intervention.

Indications for TEE in case selection:

- Past history of stroke or Transient Ischemic Attack (TIA).
- Atrial fibrillation (AF).
- Suspicion of clot or Spontaneous Echo Contrast (SEC) on TTE.
- Patients > 40 years.
- Inadequate imaging of MV apparatus.

A 3D TTE and TEE assessment promises to provide more detailed physiological and morphological information.⁵ The 3D Echocardiography improves the visualization of commissures, optimizes accuracy and reproducibility of planimetry, and could be used for guiding and monitoring the results of BMV in difficult cases.

A stress echo should be considered when there is a discrepancy between the resting Doppler echocardiographic measurements and symptoms. Dobutamine or preferably exercise echocardiography may provide additional information by assessing changes in transmitral gradient and pulmonary artery pressures. Increase in the mean transmitral gradient >15 mm Hg or estimated pulmonary artery systolic pressure (PASP) >60 mmHg on exercise justifies the need for balloon intervention.⁶ There is an emerging role for a stress echocardiography in evaluating women with mild to moderate MS who are contemplating pregnancy. Stress echo helps to assess how these patients will tolerate the pregnancy and further helps identify patients who may benefit from prophylactic BMV.

Echocardiography provides definitive information about the severity of MS, valve morphology and other valves. The data obtained by echocardiography helps to identify cases who need BMV, those who will benefit the most and the ones where BMV is contraindicated.

Assessment of severity:

It is recommended that the severity of MS should not be defined by a single parameter. It should be

assessed by a multi-modality approach that determines valve area, mean Doppler gradient and PA pressure.^{4,6} The mitral valve area (MVA) can be assessed by planimetry using either 2D or 3D imaging, pressure half time (PHT), the continuity equation and the proximal isovelocity surface area (PISA) method. The accuracy and reproducibility of each method is limited by associated lesions, heart rate, rhythm and technical factors. Direct 3D planimetry from the left ventricular (LV) side is the most accurate method for MVA evaluation. The PISA method was the most accurate of all 2D techniques, followed by the PHT method, and 2D planimetry. The transvalvular mean gradient is the major hemodynamic determinant of MS severity, however is heart rate and flow dependent. Doppler measurements using the continuous wave Doppler signal show good correlation with invasive measurements during TS catheterization.⁷

The degree of PH should be assessed by M mode echocardiography and Doppler interrogation. The PH severity is an important indicator of the overall hemodynamic consequence of MS, and is associated with an adverse prognosis.

Quantification of MS severity by echocardiography-

- Valve area (cm²) : Planimetry, PHT , continuity equation, Proximal Isovelocity Surface Area (PISA).
- Mean pressure gradient across the MV (MMHG) ; Doppler diastolic mitral flow
- Systolic PA pressure: Tricuspid regurgitation (TR) + Right Atrial Pressure (RAP).

Assessment of valve anatomy:

Evaluation of MV anatomy by echocardiography identifies the best treatment option. It helps in evaluating leaflet mobility, thickness, calcification, as well as in assessing subvalvular fusion, commissural fusion and calcification. These morphological features are assessed by different scoring systems (Table I) to describe the extent of the MV disease, to evaluate the suitability for BMV, and to predict the success and complications following BMV. No individual scoring system, however, is found superior to another. Thus, the scoring system should be used in a complementary fashion, as a part of the comprehensive

echocardiographic assessment. The most validated and commonly used score is the Wilkins score also called as the “splitability score”.⁸ This assessment by TTE grades of each parameter (leaflet thickness, leaflet calcification, leaflet mobility and involvement of the subvalvular apparatus) on a 1 to 4 scale (maximum total score = 16). An inverse relation exists between the total splitability score and BMV success with the cutoff of <8 reflecting best short and long term results. Figure 2 and 3 show examples of Wilkins score below and above 8. In our center, BMV is not denied to patients with a high overall Wilkins score if commissural fusion is present and other clinical features are favorable. The major drawback of Wilkins score is non inclusion of commissural assessment. Commissural calcification is a strong predictor of adverse outcome as well as the occurrence of severe MR following BMV.^{9,10} Therefore it is recommended that a commissure score (Table II) based on commissural morphology be used as an adjunct to Wilkins score to predict patient outcome after BMV.¹¹ A high score (Fig 3) indicates extensively fused, non-calcified commissures more likely to split and low score corresponds to calcified commissures which resist splitting .

Table-I

Scoring systems for assessment of Mitral valve before valvuloplasty.

Score method	Modality
Wilkins score ⁸	2D TTE
Commisural Calcium ⁹	2D TTE
Commisure ¹⁰	2D TTE
Grouping ²⁰	2D TTE + Fluoroscopy
Real time- Transthoracic 3D echo(RT -TT3DE) ²¹	3D TTE

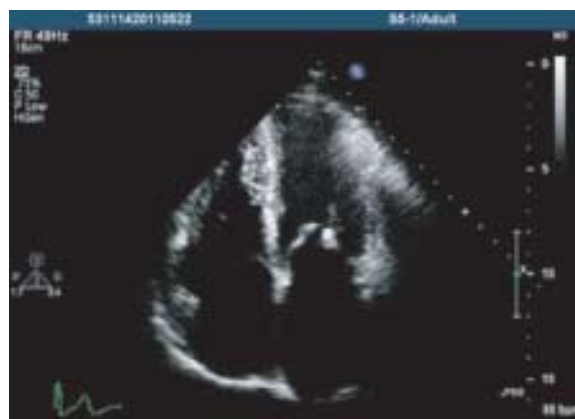

Fig.-2 : TTE shows MS with Wilkins score below 8 Valve anatomy favourable for BMV.

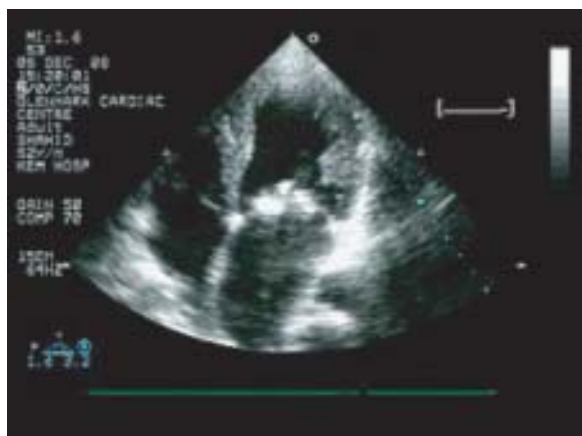


Fig.-3: TTE showing MS with high Wilkins score TTE shows valve morphology (thickened fused and calcified valve) not favourable for BMV.

Table-II

Commissure calcium score based on TEE
(Modified from ref 11).

Score	Morphology
0	No commissural fusion or Calcium (CA).
1	Partial fusion of one or absent fusion.
2	Extensive fusion of one, absent fusion or CA of other.
3	Extensive fusion of one, partial of other, no CA.
4	Extensive fusion of both, no CA.

Echocardiography also assesses other valves and defines hemodynamic severity of coexisting lesions. Aortic regurgitation (AR) grade 2 or less

and haemodynamically insignificant aortic stenosis (AS) are not a contraindication to BMV. Significant tricuspid valve regurgitation (TR) is not an uncommon finding in patients with severe MS and in the majority of the cases, it is secondary to right ventricular and tricuspid annular dilatation caused by long standing PH. The presence of such functional TR is not a contraindication for BMV but is an important technical consideration in view of dilated right atrium (RA).

Echocardiographic imaging also helps to exclude contraindications to BMV [MVA > 1.5 cm², LA thrombus, mitral regurgitation (MR) that is d” grade 2, bi-commissural calcification, absence of commissural fusion, and significant concomitant valve disease requiring surgery].^{4,6}

Contraindications (Echocardiographic) to BMV-

- MVA > 1.5 cm².
- LA Thrombus.
- e” Grade II MR.
- Severe or Bicommissural Calcification.
- Absence of commissural fusion.
- Severe Aortic or severe tricuspid valve disease requiring surgical intervention.
- Concomitant coronary artery disease (CAD) requiring CABG.

Fig 4 illustrates large clots seen on TTE and TEE in different patients and are a contraindication for BMV.

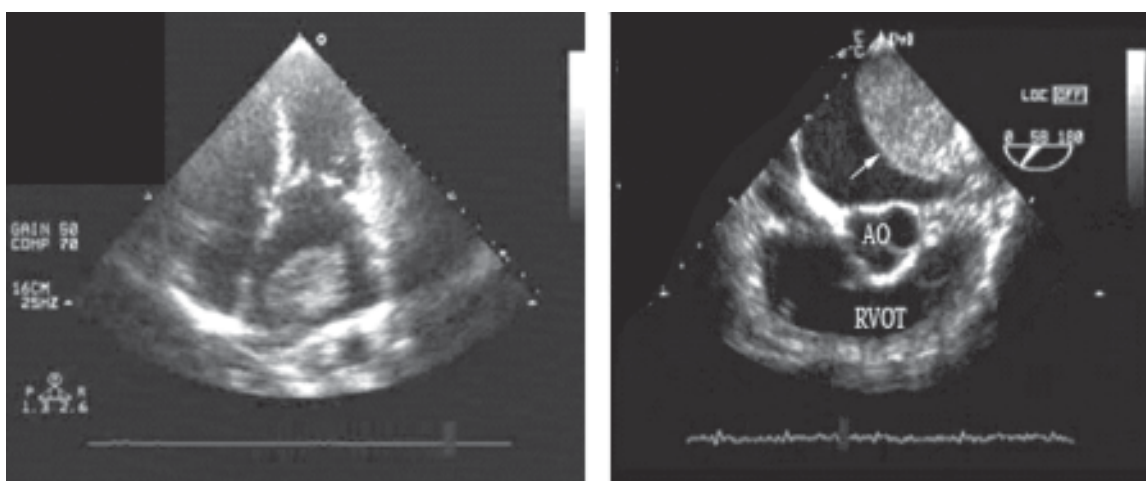


Fig 4: TTE and TEE in detection of clot (TTE documentation of large clot (arrow) in roof of LA (A). TEE in another case shows large clot occupying the LA. (AO = aorta, RVOT = right ventricular outflow tract.)

Fig 5 shows significant concomitant aortic regurgitation (AR) requiring valve replacement and is a contraindication for BMV.

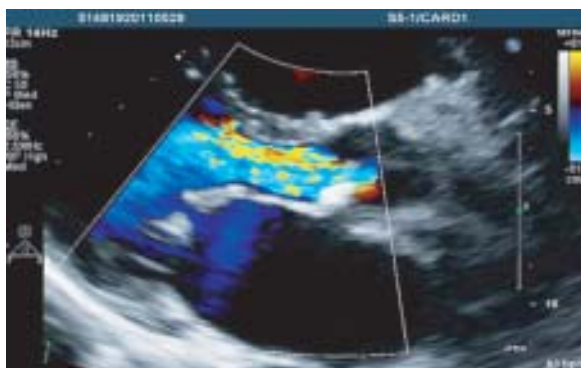

Fig 5: TTE shows associated severe AR (MS with associated severe AR is a contraindication to BMV and an indication for double valve surgery).

2. Role of echo imaging in transseptal catheterization:

All antegrade approaches for BMV begin with the crucial first step of successful transseptal catheterization. The transseptal puncture in majority of the centers is performed under fluoroscopic guidance.¹² Intra-procedural TTE or TEE use in our center is limited to selective patients with difficult TSP, technical problems or any complication.

The transseptal puncture (TSP) can be technically challenging in certain individuals (Table VII) and TTE, TEE, intracardiac echocardiography (ICE) can be used in such cases. Two or 3 dimensional TEE helps in visualizing specific area of the fossa ovalis

to be punctured and aids in safety of the TSP.¹³ Superior/ inferior localization is best seen in bi-caval view while anterior posterior localization is best appreciated in the 4 chamber view.

Conditions where TSP is difficult-

- Large right atrium (RA) due to functional Tricuspid regurgitation (TR).
- Aneurysmal Left atrium (LA) (LA > 6cm).
- Hypertrophied inter atrial septum (IAS).
- Spinal deformity.
- Pregnancy.
- Cardiac malformations.
- Inferior vena cava (IVC) interruption.

TEE guidance can be useful, especially in patients with large atrium or unusual morphology of the interatrial septum (IAS). The IAS morphology may be altered in the setting of cardiac malpositions, pregnancy with abdominal distension, large atrial septum aneurysm, previous cardiac surgery or percutaneous procedures involving the IAS, kyphoscoliosis or previous pneumonectomy. In such cases, TEE can visualize the tenting of fossa ovalis by the transseptal needle (Figure 6) and facilitate a safe TSP.

Thickness of IAS over 2cm on noninvasive imaging is increasingly reported as an indication of lipomatous hypertrophy.¹⁴ If the IAS thickness is between 1.5 to 2 cm (Fig 7 C and D) it is preferable to perform the TSP under TEE or ICE guidance. If there is a resistance to the passage of needle, we resort to a non transseptal technique for performing the BMV.

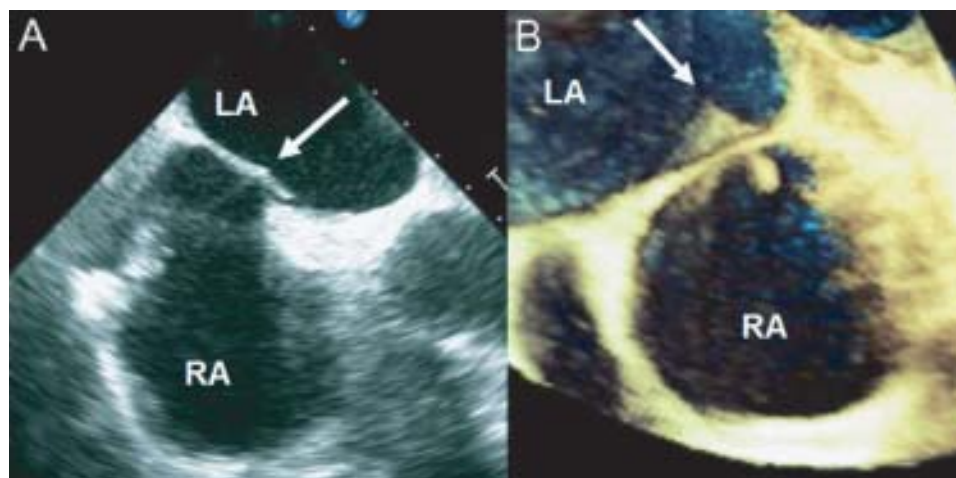


Fig 6 : 2D (A) and 3-D E (B) views during TSP. Arrow shows tenting of fossa ovalis by TSP needle tip. (LA = left atrium , RA = Right atrium).

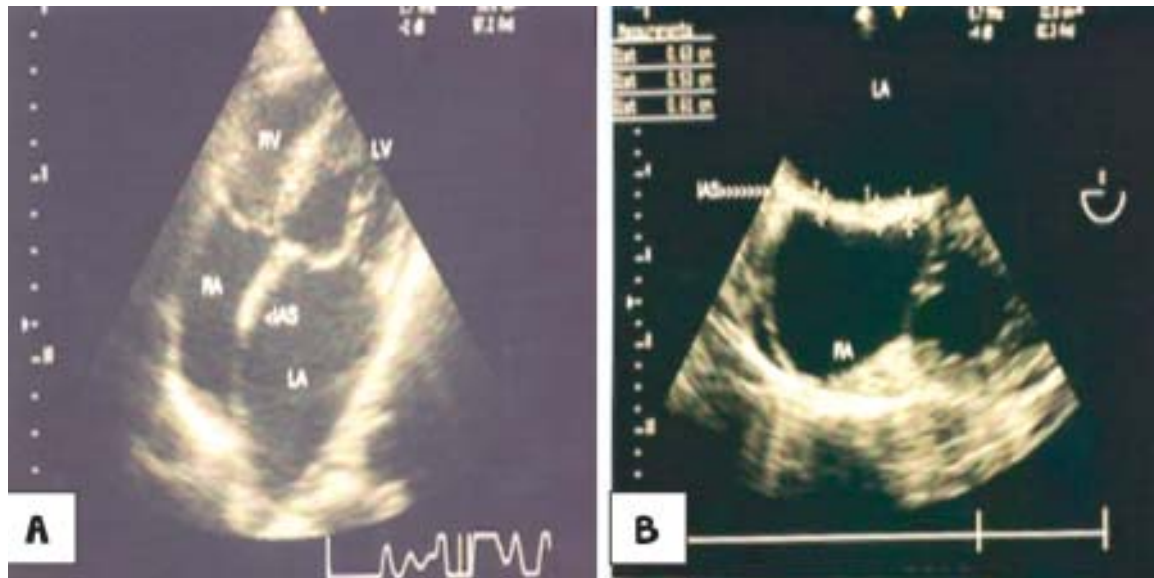


Fig-7: Echocardiographic demonstration of thick inter atrial septum (IAS). A: Thick IAS on TTE and TEE (B) should alert to potential problems and need to resort alternate (non transseptal) technique.

3. Utility of echocardiography during balloon valvotomy procedure .

The balloon valvotomy procedure after transseptal puncture is usually performed under fluoroscopic guidance. In difficult cases, TEE can help to optimize balloon position across the MV leaflets and avoid entrapment in the subvalvar apparatus. Real time three dimensional TEE (RT3D-TEE) improves depth resolution, characterization of

pathology and visualization of interventional catheters and devices and can play a useful role during BMV.¹⁵

Immediately following BMV, the TTE or TEE examination can assess post BMV MVA, the peak and mean gradients, uni-commissural or bilateral commissural opening (Fig 8), and define presence, degree and site of MR (commissural, leaflet or otherwise).

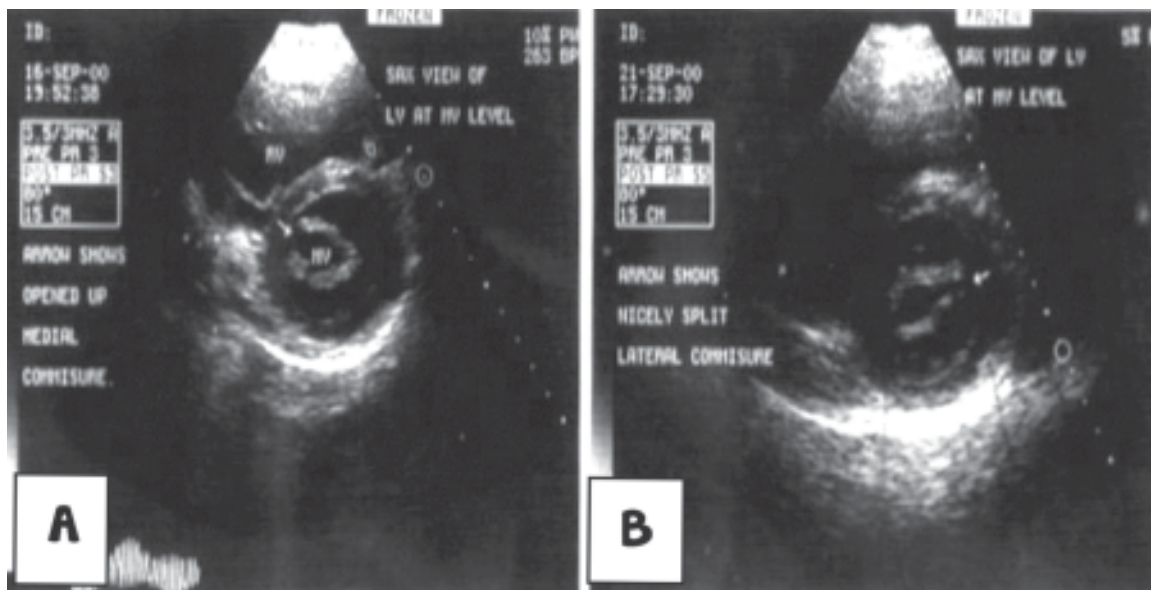


Fig 8: TTE short axis view post BMV. Splitting of medial (A) or lateral (B) commissure indicates adequate valvotomy and further dilatation should be avoided.

Most of the complications related to BMV occur during the procedure (Table III). An increase of MR is a known complication after BMV, however, in most cases, the degree of MR is mild and well tolerated (Fig 9). The mechanism of increase or new appearance of MR is reported to be due to slight (Fig 10) or excessive tearing of the commissure(s) or the posterior/anterior leaflet at non-commissural part, incomplete closure of a calcified leaflet, localized rupture of the subvalvular apparatus and shortened chordae tendineae after splitting of the commissures. Most cases of severe MR occur in patients with unfavorable valve morphology. Anterior mitral leaflet tear is the most common etiology for severe MR and has been the result of 2D TTE underestimating the subvalvular disease.

Puncture by the transseptal needle and by advancing the 14F dilator at the IAS creates an iatrogenic left-to-right shunt at atrial level persisting for more than several months and in some cases, years. These shunts, are usually small and restrictive (Fig 11) and rarely become haemodynamically significant (QP/QS >1.5).

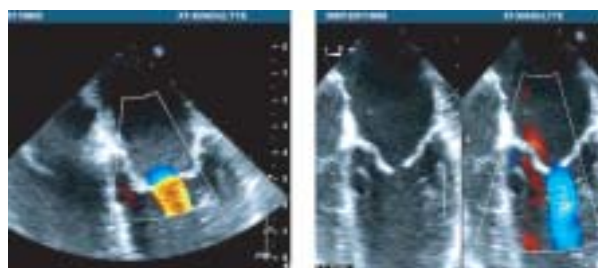


Fig 9: Complications during BMV. A: Baseline TEE shows tight MS and no MR. B: Grade I - II MR post BMV, usually well tolerated.

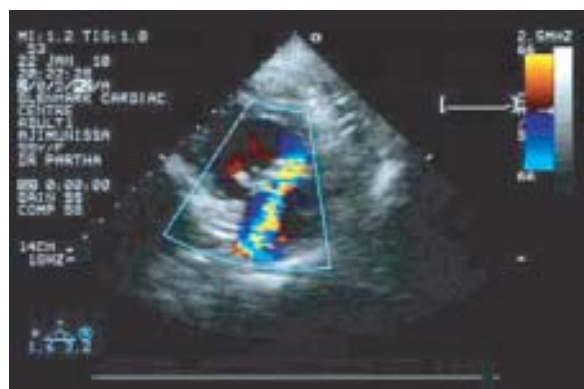

Fig-10 : New MR after BMV due to commissural split.

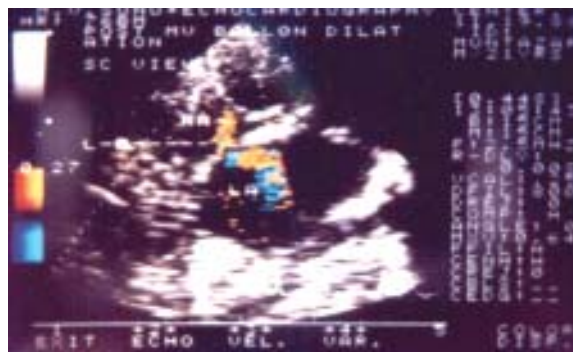

Fig-11: Left to right shunt at the site of Transseptal Puncture.

Hemopericardium (and cardiac tamponade) can occur during TSP or other steps of BMV. Echocardiography can promptly recognize the effusion, its hemodynamic consequences and the need for pericardiocentesis .

Table-III
Complications of BMV.

Steps during BMV	Complications
IAS Puncture	Hemopericardium, Tamponade.
Manipulation of Accessories	Perforation, Systemic Emboli.
Valvotomy by Balloon	Mitral regurgitation (MR).
Microthrombi	Systemic embolization.
IAS dilatation	Iatrogenic atrial septal defect (ASD).

4. Echocardiography in assessment of results and follow up.

After the procedure, 2DE is used to evaluate a post BMV MVA using mean Doppler gradients and planimetry. If available, 3D is used to evaluate commissural opening and determine the severity and location of MR. Echo should also look for any residual atrial level shunt. Following successful BMV, there is significant regression of PH particularly in younger patients and PA pressures should be serially followed. BMV is a palliative procedure and all patients should undergo an echocardiographic follow-up at 1 year or earlier (in cases with sub-optimal results) to see for changes in valve haemodynamics, MR, regression of PH and TR, ventricular function and progression of lesions in other valves.

The real time 3D has been shown to be more accurate and to have the best agreement with invasively determined MVA compared with conventional 2D planimetry. In addition, the opening of the commissures is shown more clearly by real time 3DE (Fig 12). Commissural opening is a significant predictor of long term outcome and is associated with a larger MVA, smaller gradients and better functional outcomes.¹¹ It is important to remember that immediate post-procedure measurements of MVA and gradients might obtain different results than measurements performed later after LA remodeling and changes in LA wall compliance. The changes in heart rate also have an impact on mitral gradients and should always be taken in to account while interpreting comparative readings.

The left atrial (LA) pressure, mean mitral gradient and pulmonary artery systolic pressure (PASP) decrease significantly after BMV with corresponding increase in MVA. In our initial series of 350 cases,¹⁶ the echocardiographic MVA was $0.88 \pm 0.17 \text{ cm}^2$ before the procedure and increased to $1.96 \pm 0.3 \text{ cm}^2$ after the procedure. A significant inverse relationship is found between the echo score and post procedure MVA; thus MV morphology is found to be a strong predictor of post procedure valve opening. However, favorable results can also be obtained in patients with a relatively high echo score at 6 years follow-up.¹⁷

Fawzy has demonstrated regression of significant TR after successful BMV in young patients with severe MS and significant PH.¹⁸ On the other hand; Sagie et al have found no regression of TR in relatively older patients with mild PH.¹⁹

Conclusions:

Rheumatic MS continues to be a challenge in developing countries. Percutaneous BMV is an effective palliative option for this condition. Echocardiography plays an important role in patient selection, facilitation of safe procedure, in assessment of results and long term follow up.

Conflict of Interest - None.

References:

1. Sharma S, Dalvi B. Mitral valve disease. In: Chatterjee K, Anderson M, Heistad D, Kerber R E. Eds. *Cardiology, An Illustrated Textbook*, Volume II, New Delhi: Jaypee brothers, 2012: 1000-1017.

2. Harken D E, Dexter L, Ellis L B, et al. The surgery of mitral stenosis: III: Finger –Fracture Valvuloplasty. *Ann Surg* 1951; 134:722-742.
3. Inoue K, Owaki T, Nakamura T, et al. Clinical application of transvenous mitral commissurotomy by a new balloon catheter. *J Thorac Cardiovasc Surg* 1984; 87: 394-402.
4. Nishimura R A, Otto C M, Bonow R O, et al. 2014 AHA/ACC Guideline for the Management of Patients With Valvular Heart Disease : A Report of the American College of Cardiology/ American Heart Association Task Force on Practice Guidelines. *J Am Coll Cardiol* 2014; 63:e57-e185.
5. Lang RM, Badano LP, Tsang W, et al. EAE/ ASE recommendations for image acquisition and display using three dimensional echocardiography. *J Am Soc Echocardiogr* 2012 ; 25: 3-46
6. Vahanian A, Alfieri O, Andreotti F, et al. Guidelines on the management of valvular heart disease (version 2012) The Joint Task Force on the Management of Valvular Heart Disease of the European Society of Cardiology (ESC) and the European Association for Cardio-Thoracic Surgery (EACTS). *Eur Heart J* 2012; 33: 2451–2496.
7. Nishimura RA, Rihal CS, Tajik AJ, et al. Accurate measurement of the transmitral gradient in patients with mitral stenosis: a simultaneous catheterization and Doppler echocardiographic study. *J Am Coll Cardiol* 1994; 24:152-158.
8. Wilkins GT, Weyman A E, Abscal V M, et al. Percutaneous balloon dilatation of the mitral valve : an analysis of echocardiographic variables related to outcome and the mechanism of dilatation. *Heart* 1998; 60:299-308.
9. Cannan CR, Nishimura RA, Reeder GS, et al .Echocardiographic assessment of commissural calcium: a simple predictor of outcome after percutaneous mitral balloon valvotomy. *J Am Coll Cardiol* 1997; 29:175-80.
10. Padiyal LR, Freitas N, Sagie A, et al . Echocardiography can predict which patients will develop severe mitral regurgitation after percutaneous mitral valvotomy. *J Am Coll Cardiol* 1996; 27:1225-1231.
11. Sutaria N, Shaw TRD, Northridge D, et al. Commissural morphology predicts outcome after balloon mitral valvotomy . *Heart* 2006; 92: 52-57.
12. Hung JS. Atrial septal puncture technique in percutaneous transvenous mitral commissurotomy, mitral valvuloplasty using the Inoue balloon catheter technique. *Catheter Cardio Diag* 1992; 26:275-284.
13. Hahn K, Bajwa T, Sarnoski J, et al. Trans-septal catheterization with trans-esophageal guidance in high risk patients. *Echocardiography* 1997; 14:475-480.
14. Ho SY, Mc Carthy KP, Faletta FF: Anatomy of the left atrium for interventional echocardiography. *Eur Heart J Cardiovasc Imaging* 2011; 12, i 11- i15.

15. Eng M H , Salcedo E E , Kim M , et al. Implementation of real- time three -dimensional transesophageal echocardiography for mitral balloon valvuloplasty. *Catheter Cardiovasc Interv* 2013; 82: 994-998.
16. Sharma S, Loya YS, Desai D M, et al. Percutaneous mitral valvotomy using Inoue and double balloon technique: comparison of clinical and hemodynamic short term results in 350 cases. *Catheter Cardiovasc Diag* 1993; 29:18-23.
17. Hildick-Smith DJ, Taylor GJ, Shapiro LM. Inoue balloon mitral valvuloplasty: long-term clinical and echocardiographic follow-up of a predominantly unfavourable population. *Eur Heart J* 2000; 21: 1690-1697.
18. Fawzy ME. Percutaneous mitral balloon valvotomy. *Catheter Cardiovasc Interv* 2007 ;69: 313-321.
19. Sagie A, Schwammenthal E, Palacios IF ,et al. Significant tricuspid regurgitation does not resolve after percutaneous balloon mitral valvotomy. *J Thorac Cardiovasc Surg* 1994; 108: 727-735.
20. Lung B, Cormier B, Ducimetière P,et al.Immediate results of percutaneous mitral commissurotomy. A predictive model on a series of 1514 patients. *Circulation* 1996; 94:2124-2130.
21. Anwar AM, Attia WM, Nosir YF,et al.Validation of a new score for the assessment of mitral stenosis using real-time three-dimensional echocardiography. *J Am Soc Echocardiogr* 2010 Jan; 23(1):13-22.