

Ventricular Fibrillation with Brugada Syndrome: A Case Report

Shaila Nabi, Asif Zaman Tushar, Umme Habiba Ferdaushi, Mainul Islam, Farhad Uddin, M. Atahar Ali
Department of Cardiology, NICVD

Abstract:

Brugada syndrome is a potentially lethal and eminently treatable entity that may present with palpitations or syncope. This article presents the case of a young patient with Brugada syndrome and reviews key features in the epidemiology, pathophysiology, diagnosis, treatment and prognosis of this condition.

(Cardiovasc. j. 2015; 8(1): 69-72)

Introduction:

Brugada syndrome accounts for 4–12% of all sudden deaths worldwide and at least 20% of sudden deaths in patients with structurally normal heart.^{1,2} In the United States, the prevalence of Brugada syndrome has been indicated as 0.03% which is significantly lower than those of Asia and Europe.³ The male to female ratio of Brugada syndrome is about 10: 1.⁴ Patients with Brugada syndrome who present with syncope have a 2-year risk of sudden cardiac death of approximately 30%.⁵

One of the causes of dysrhythmic sudden cardiac death in young adults with structurally normal hearts is a relatively recently described entity named Brugada syndrome.⁶

Case report:

A 35-years-old male got admitted in National Institute of Cardiovascular Diseases with the complaints of one episode of convulsion which was preceded by palpitation, light-headedness, nausea, diaphoresis and a feeling of impending death. On examination, his pulse and BP were unrecordable but patient was conscious. ECG showed ventricular fibrillation (VF) (Fig: 1), prompt DC shock was given at 200 joules (biphasic) and reverted to sinus rhythm. During sinus rhythm, the electrocardiogram (ECG) showed saddle back type ST-segment elevation in leads V₁ and V₂ suggestive but not diagnostic of Brugada syndrome (Fig. 2). Results of his laboratory

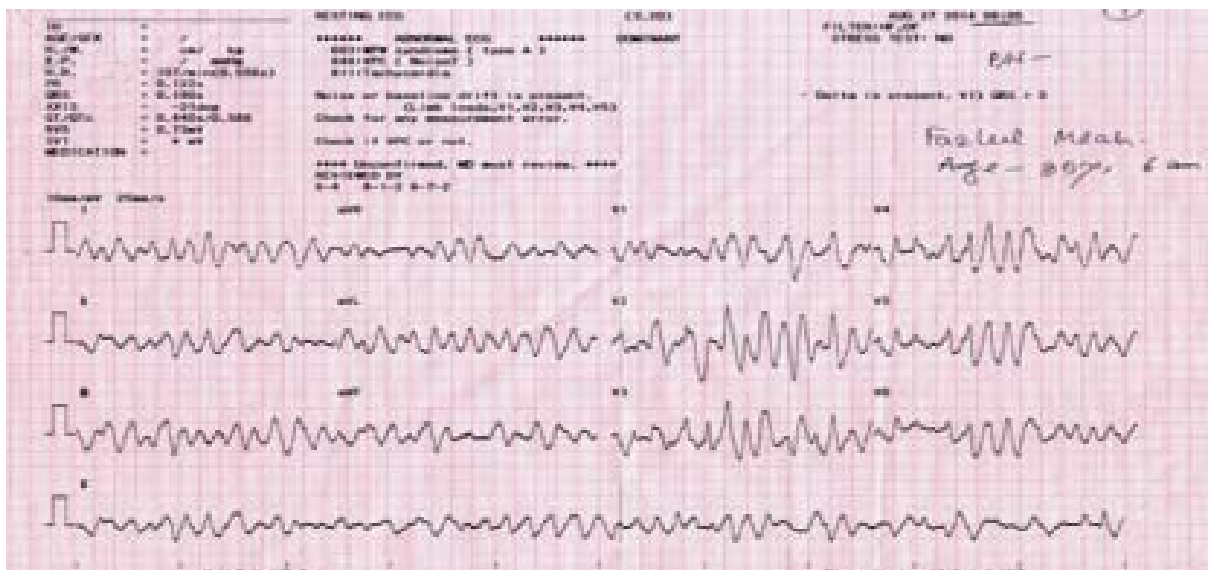


Fig.-1: ECG of patient during admission.

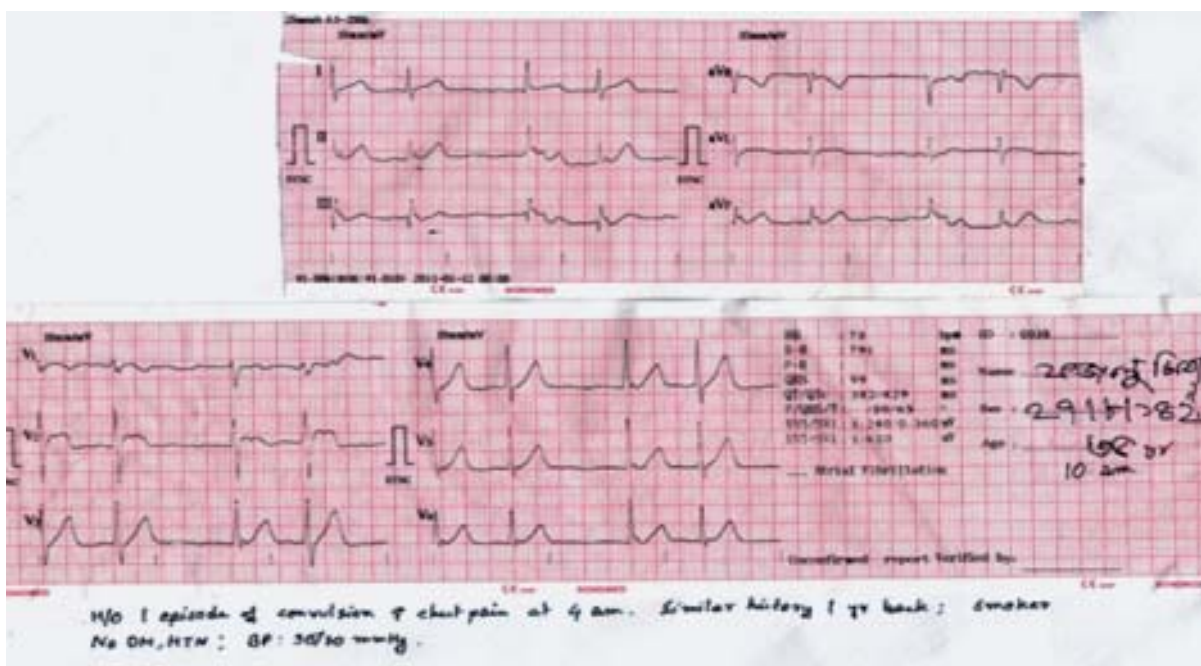


Fig.-2: ECG of patient after restoration to sinus rhythm.

investigations and chest x-ray were normal. His physical examination was normal. He had three episodes of syncopal attack during preceding six months. His father suffered sudden cardiac death at the age of 40 years and his sister also died in childhood of unknown causes. He was diagnosed as a case of Brugada syndrome on the basis of clinical feature and ECG findings and later on Implantable Cardioverter Defibrillator (ICD) was implanted to prevent sudden cardiac death (SCD).

Discussion:

Brugada syndrome was described by Pedro and Josep Brugada in 1992 as a cause of sudden

cardiac death.² It is characterized by a right bundle branch block (RBBB) pattern, often incomplete, in V₁ and V₂, ST-segment elevation in the right precordial leads, which is often transient, a structurally normal heart and the propensity for life-threatening ventricular tachydysrhythmias. The elevated ST segments seen in Brugada syndrome are limited to leads V₁-V₃ and they are slowly down sloping, with T-wave inversion (Fig. 3). The prominent S wave in the lateral precordial leads (typical of RBBB) is often absent in Brugada syndrome, suggesting this may not be true RBBB.

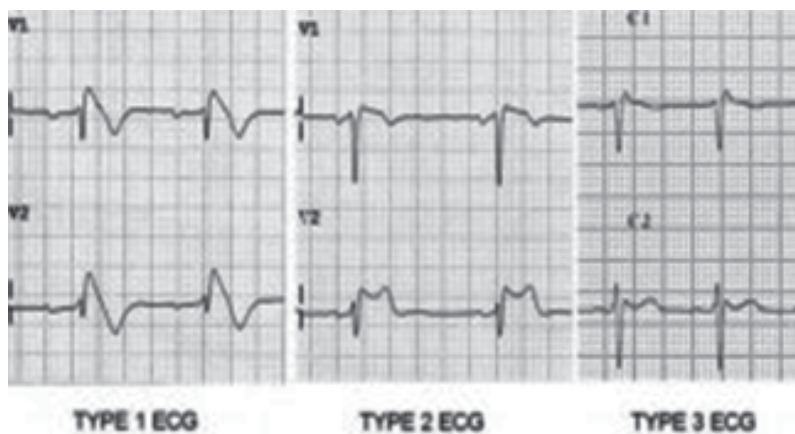


Fig.-3: ECG of Brugada syndrome.

Epidemiology and inheritance

Brugada syndrome is most prevalent in young adult males of Southeast Asian descent, but it has been documented in both genders, all age groups and a variety of ethnic populations, accounting for 0.05%-0.6% of cases of SCD, depending on the population studied.⁷⁻⁹ It follows an autosomal dominant inheritance pattern with variable penetrance and expression. In approximately 25% of families, Brugada syndrome is the result of a defect in the *SCN5A* gene on chromosome three, which encodes for the alpha-subunit of the sodium channel. In another 25% of cases the inheritance pattern is not clear but is felt to be an allelic disorder of the sodium-channel gene. The remaining 50% of cases have no family history and are postulated to be the result of sporadic mutation.^{10,11}

Pathophysiology

It appears that sodium channels of the right ventricular epicardium are affected and those in the endocardium are not. This alteration of action potential in the epicardium but not in the endocardium causes differential repolarization and refractoriness across the myocardium, leading to a vulnerable period during which a premature impulse or extra-systole can trigger a re-entrant dysrhythmia.^{7,11,12} Sodium-channel dysfunction may be intermittent and consequently so can the ECG abnormalities, resulting in concealed forms of Brugada syndrome. Certain physiological and external factors can unmask or exacerbate the channel dysfunction. These include febrile episodes, autonomic imbalance, electrolyte disturbances, and drugs that affect the sodium channels — particularly class IA and IC anti-dysrhythmics, tricyclic antidepressants, lithium, benadryl and cocaine. There also appears to be a circadian pattern with more events occurring during sleep or rest when there is less sympathetic activity.⁹

Clinical presentation

Potentially lethal cardiac dysrhythmias, notably polymorphic ventricular tachycardia, may occur. If such dysrhythmias terminate spontaneously, patients may present with palpitations or syncope; if these dysrhythmias persist, they eventually degenerate into ventricular fibrillation. Classic findings on the resting ECG are right precordial lead ST-segment elevations that cannot be explained by ischemia, pericarditis, electrolyte or metabolic disorders, central or autonomic nervous system disorders, or early repolarization syndrome. Unfortunately, not all patients will have a characteristic ECG and positive family history;

therefore cardiology consultation for procainamide electrophysiological provocative testing is recommended in appropriate patients with suspected cardiac syncope. Patients who present with non-cardiac symptoms but have typical Brugada ECG abnormalities on an incidental ECG should also have urgent cardiology consultation for consideration of provocative testing. This is imperative in light of the fact asymptomatic and symptomatic patients have a similar prognosis.

The mortality rate for untreated Brugada syndrome may be as high as 10% per year, even in asymptomatic patients with typical findings on the resting ECG.¹⁰ Brugada syndrome may be responsible for 4%-12% of all sudden cardiac deaths and up to 20% of SCD in individuals with structurally normal hearts. Long QT syndrome, dysrhythmogenic right ventricular cardiomyopathy, pre-excitation syndromes and idiopathic ventricular fibrillation make up the rest.⁷

Pharmacological provocation test

Intravenous administration of Na⁺ channel blocking drugs like ajmaline, flecainide, pilsacanide and, to a variable extent, procainamide, are useful in bringing out Type 1 Brugada pattern on the ECG when ECG changes are not diagnostic. Ajmaline is an ideal drug for this purpose because of its short duration of action and higher sensitivity than flecainide but as it is not available in Australia, flecainide (2mg/kg maximum 150mg in 10 minutes) is the drug commonly used. The sensitivity and specificity of flecainide test in *SCN5A* mutation-positive probands and their families has been reported as 77% and 80%, respectively. Pharmacological provocation should only be performed when the baseline ECG is not diagnostic of BS. There is no advantage and possibly a risk of inducing Ventricular tachycardia (VT)/VF, in performing it in the presence of Type 1 BS pattern in the baseline ECG. PR prolongation in the baseline ECG is also a contraindication because of the risk of inducing AV block. Drug challenge should be performed under strict monitoring of BP and 12-lead ECG and facilities for cardioversion and resuscitation should be available. Drug administration should be stopped if a Type 1 pattern becomes apparent on the ECG, if the patient develops ventricular arrhythmias, if the QRS widens to $\geq 130\%$ of the baseline, or if a total of 150mg flecainide is administered. The patient needs to be monitored until the ECG is normalized. Plasma half-life of flecainide is 20 hours. Isoprenaline infusion may be employed to counteract if serious ventricular arrhythmias

develop. The incidence of serious arrhythmia is low if the drug is not administered to patients who already have Type 1 ECG at baseline. Provocative drug challenge is helpful in asymptomatic family members of BS and where the baseline ECG shows Type 2 or 3 changes. It is also performed as a part of investigations in survivors of cardiac arrest without any apparent cause.

Role of electrophysiological study in risk stratification

The predictive value of inducibility of sustained ventricular arrhythmias during EPS is still controversial. Although Brugada et al. have supported the value of EPS based on the results for the largest series of patients, two other large studies have not confirmed their findings.¹³⁻¹⁵

Treatment

To date, no pharmacological agents have improved survival, however implantable cardiac defibrillators reduce 10-year mortality to approximately 0%.^{7,9} Although the incidence of ventricular dysrhythmic events is similar in patients receiving an ICD, beta-blocker or amiodarone, only the ICD prevents SCD.¹²

For asymptomatic patients with spontaneous type 1 Brugada ECG without family history of SCD, the indications for treatment remain unclear, since the value of EPS is still controversial, as noted above. Asymptomatic patients with type 1 Brugada ECG after sodium channel blockade and without family history of SCD appear to be at low risk for SCD.² Treatment is currently not recommended for these patients.

Conclusions:

Brugada syndrome is a significant cause for SCD in young patients and is imminently treatable. Given the high risk of SCD and the effectiveness of implantable defibrillators, it is essential that this uncommon diagnosis be considered in the differential diagnosis of apparently healthy patients who present with syncope or palpitations, particularly those with a positive family history of unexplained SCD. The diagnosis should also be considered in asymptomatic patients with typical ECG abnormalities. In our case, we illustrate a patient presenting with a polymorphic VT storm with preserved consciousness in the setting of Brugada syndrome, a rare manifestation of this syndrome.

Conflict of Interest - None.

References:

1. Wilde AAM, Antzelevitch C, Borggrefe, Brugada J, Brugada R, Brugada P et al. Proposed diagnostic criteria for the Brugada syndrome: consensus report. *Circulation* 2002;106, 2514–2519.
2. C Antzelevitch, Brugada P, Borggrefe M, Brugada J, Brugada R, Corrado D et al. Brugada Syndrome: report of the second consensus conference. *Circulation* 2005; 111(5): 659–670.
3. Mizusawa Y, Wilde AAM. Brugada syndrome, Arrhythmia and Electrophysiology. *Circulation* 2012. 5(3):606–616.
4. Nademanee K, Veerakul G, Nimmannit S, Chaowakul V, Bhuripanyo K, Likittanasombatet K al. Arrhythmogenic marker for the sudden unexplained death syndrome in Thai men. *Circulation* 1997; 96(8): 2595–2600.
5. Brugada J, Brugada R, Antzelevitch C, Towbin J, Nademanee K, Brugada P. Long-term follow-up of individuals with the electrocardiographic pattern of right bundle-branch block and ST-segment elevation in precordial leads V₁ to V₃. *Circulation* 2002 ;105 :73–78.
6. Brugada P, Brugada J. Right bundle branch block, persistent ST segment elevation and sudden cardiac death: a distinct clinical and electrodiagnostic syndrome. *J Am Coll Cardiol* 1992;20: 1391-1396.
7. Antzelevitch P, Brugada P, Brugada J, et al. Brugada syndrome: a decade of progress. *Circ Res* 2002;92:1114-1118.
8. Jones R, Gage A. Brugada Syndrome as the cause of syncope in a 49-year-old man. *Ann Emerg Med* 2000;36:156-159.
9. Mattu A, Rogers RL, Kim H, Perron AD, Brady WJ. The Brugada syndrome. *Am J Emerg Med* 2003;21:146-151.
10. Naccarelli G, Antzelevitch C. The Brugada Syndrome: clinical, genetic, cellular, and molecular abnormalities. *Am J Med* 2001;110: 573-581.
11. Corrado D, Buja G, Basso C, Nava A, Thieme G. What is the Brugada syndrome? *Cardiol Rev* 1999;7: 191-195.
12. Brugada J, Brugada P, Brugada R. The syndrome of right bundle branch block, ST segment elevation in V1 to V3 and sudden death. *Cardiovasc Drug Ther* 2002;16:25-27.
13. Brugada J, Brugada R, Brugada P. Determinants of sudden cardiac death in individuals with the electrocardiographic pattern of Brugada syndrome and no previous cardiac arrest. *Circulation* 2003;108:3092-3096.
14. Priori SG, Napolitano C, Gasparini M, Pappone C, Bella PD, Giordano U et al. Natural history of Brugada syndrome: insight for risk stratification and management. *Circulation* 2002;105: 1342-1347.
15. Eckardt L, Probst V, Smits JPP, Bahr ES, Wolpert C, Schimpf R et al. Long-term prognosis of individuals with right precordial ST-segment-elevation Brugada syndrome. *Circulation* 2005;111: 257-263.