

Outcome of the Repair of Double-Chambered Right Ventricle: A single centre experience.

Mohammad Rokonujjaman, Md.Shaheedul Islam, Md. Sirajul Islam, Sheikh Mahamoudh, Md. Jasim Uddin, A.Y.M Sayem khan

Department of Thoracic and Cardiovascular Surgery, Ibrahim Cardiac Hospital and Research Institute, Dhaka, Bangladesh.

Abstract:

Keywords:

Double-chambered right ventricle.

Background: The presence of anomalous muscle bundles may produce a pressure gradient between the inflow and outflow portions of the right ventricle, resulting in double-chambered right ventricle. We reviewed the outcomes of double chambered right ventricle surgical repair.

Methods: Between December 2012 and January 2014, 6 patients underwent surgical repair of a double-chambered right ventricle. The patients ranged in age from 3 years to 20 years (mean 8.2 ± 5.9 yrs). Right ventricular outflow tract pressure gradients were from 60 to 120 mm Hg (mean 63.3 ± 40.3). An associated ventricular septal defect was present in 4 patients (66.66%).

Results: There were no hospital or late deaths. Mean postsurgical follow up was 3.8 ± 0.8 months. No patient required further surgery to relieve obstruction of right ventricular outflow tract.

Conclusions: Surgical repair of a double chambered right ventricle yields excellent hemodynamic and functional results.

(*Cardiovasc. j.* 2016; 8(2): 165-168)

Introduction:

The presence of anomalous muscle bundles may produce a pressure gradient between the inflow and outflow portions of the right ventricle, resulting in double-chambered right ventricle (DCRV). The natural history of this lesion is not well defined, but there is a high association with ventricular septal defect (VSD) and a tendency for the obstruction to progress over time. Typically, DCRV is diagnosed and repaired during childhood or adolescence, and most cases are reported in patients less than 20 years old.¹⁻⁶ This report describes our surgical experience with 6 patients presented with DCRV. The short-term result of DCRV repair is presented.

Methods:

Patients

Between December 2013 and January 2014, 6 patients underwent repair of a DCRV at the Ibrahim Cardiac hospital and Research Institute, Dhaka, Bangladesh. Two patients were female and 4 were male (Table I). The mean age at the time of the operation was 8.2 ± 5.9 years (range, 4 years to 20 years).

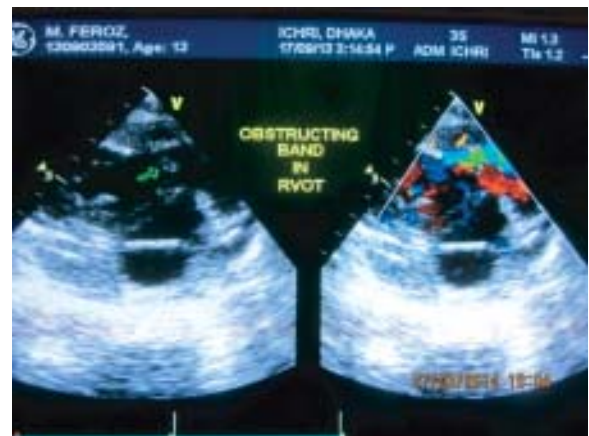

Fig-1: Pre operative Echocardiogram (obstructing muscle bands in RVOT. Arrow is the muscle band and mosaic is seen in RVOT in color Doppler).

All patients underwent preoperative cardiac catheterization. The criteria used for the diagnosis of DCRV were as follows: (1) documentation at cardiac catheterization of a systolic pressure gradient between the inflow of the right ventricle and right ventricular outflow tract (2) a right ventricular angiogram showing a high or low obstruction by an anomalous muscle bundle below

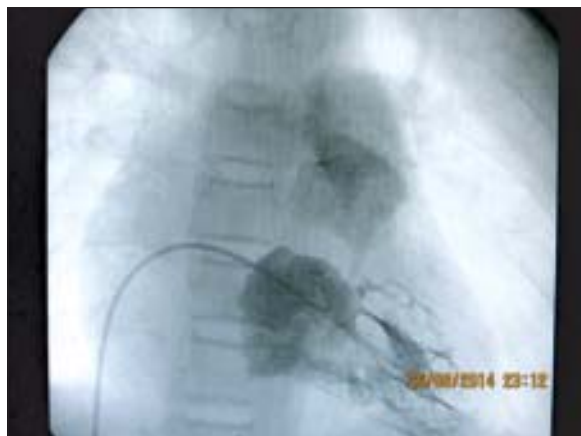

Fig-2: Pre operative Cardiac Catheterization (thick muscular band and jet flow in RVOT).

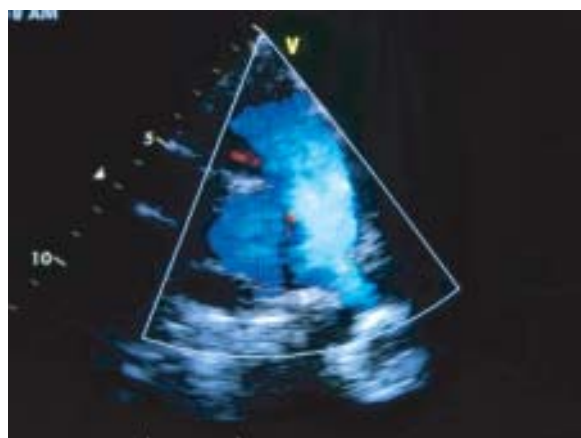


Fig-3: Post operative Colour Doppler study of RVOT (no gradient as evidenced by absence of mosaic flow in RVOT).

the infundibulum (3) absence of infundibular hypoplasia; and (4) direct observation of intracardiac muscle bundles during surgical repair. Four patients were diagnosed with DCRV preoperatively, and the remaining two patients were diagnosed as having VSD with pulmonary stenosis by echocardiography. The diagnosis was revised as VSD with DCRV intraoperatively. In the absence of a moderate or large VSD, the criterion for the diagnosis of DCRV and the need for an operation was a systolic pressure gradient between the inflow and outflow chamber of more than 40 mm Hg at rest.

Based on hemodynamic studies, the systolic pressure in the proximal chamber in the right ventricle was 85 ± 14.1 mm Hg (range, 60 to 100 mm Hg). The systolic pressure gradient across the

two chambers was 63.3 ± 40.3 mm Hg (range, 20 to 120 mm Hg). The most frequent associated cardiac anomalies were VSD in 4 patients (66.66%, 3perimem-branous type and onedoubly commitedtype), atrial septal defect in 1 patient. Subaortic membrane was found in one patient.

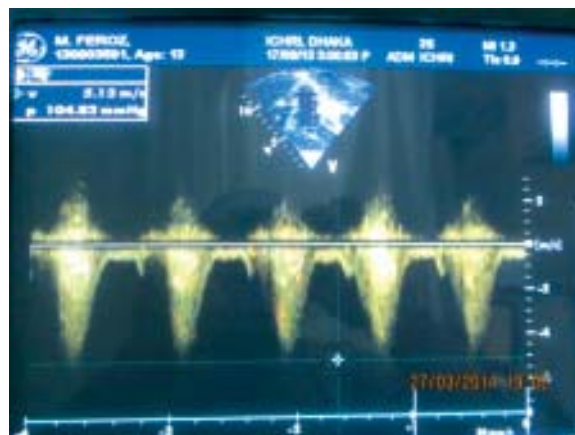


Fig-4: Preoperative RVOT gradient was 105 mmHg.



Fig-5: Post operative RVOT gradient was 4 mmHg only.

Operative Procedure

All patients underwent surgical correction through a median sternotomy with cardiopulmonary bypass under moderate hypothermia (28°C to 32°C). Antegrade cold blood cardioplegia was used for myocardial protection with topical cold saline solution infused into the pericardium. All associated cardiac anomalies were corrected simultaneously. Surgical approaches included a right atriotomy, and a combined pulmonary arteriotomy and right atriotomy.

Operative repair was accomplished through right atriotomy in 4 patients, and through a combined pulmonary arteriotomy and right atriotomy in 2 patients. Infundibular incision was given in one patient. When a VSD was present, it was closed with a PTFE patch. In one patient, sub aortic membrane was resected through VSD.

Results:

The patients' postoperative courses were uneventful and no major complications occurred. There was no hospital or late deaths. Epicardial and post operative echocardiogram was done in all cases. Post operative echo was done in the ICU, during discharge, one month and three months post operatively.

A mild right ventricular outflow tract gradient (peak systolic gradient of 15 mm Hg) was present in one patient. There was no residual VSD or post operative RV dysfunction. There was no post operative pleural or pericardial effusion. All patients were in sinus rhythm; however, one patient had incomplete right bundle branch block and bradycardia in whom infundibular incision was given.

Mean follow-up time was 3.8 ± 0.8 months (range 3 to 5 months). No patient required further operation for obstruction of the right ventricular outflow tract. All patients were asymptomatic.

Table-I

Associated cardiac anomalies in the patients with DCRV (n=6).

Cardiac Anomalies	No of patients
Ventricular septal defect	4
Perimembranous type	3
Doubly committed type	1
Atrial septal defect	1
Subaortic membrane	1

Table-II

Clinical parameters of the patients with DCRV (n=6).

Characteristic	Number
Sex	
Male	4
Female	2
Age at operation (y)	8.2 ± 5.9
Follow-up (m)	$3.8 \pm .8$
Right ventricular outflow tract gradients (mm Hg)	63.3 ± 40.3

Discussion:

Primary DCRV is an uncommon congenital anomaly consisting of one or more anomalous muscle bundles that divide the right ventricle into a proximal high pressure chamber and a distal low pressure chamber. However, it is well documented that right ventricular outflow tract obstruction caused by anomalous muscle bundles may be an acquired phenomenon in some patients with ventricular septal defect and valvular pulmonary stenosis,² and that obstruction may progress with time.⁷

None of the patients in this study required reoperation for residual right ventricular outflow tract obstruction. In one patient, clinical evaluation and post operative echocardiogram documented trivial to mild residual right ventricular outflow tract obstruction. However, this problem was not clinically significant. We believe that an excellent outcome should be the rule, not the exception, after complete surgical repair of DCRV.

Double chambered right ventricle is rare in adults, and adult cardiologists will not often see this anomaly in their practice. However, patients can present with this condition in adulthood.^{6, 8-10} McElhinney and associates¹⁰ reported 3 patients with DCRV, aged 38 to 63 years old who presented with unusual findings or an incorrect diagnosis initially. Due to our small sample size may be we did not get the adult DCRV patients. The right ventricular outflow tract obstruction in DCRV is likely to progress, and eventually the patients will become symptomatic.

The surgical repair of DCRV consists of resecting the obstructing muscle bundles. This has been accomplished through transatrial or through a combination of transatrial and transpulmonary approaches.^{13,14} Incision in the right ventricular infundibulum some times required for adequate resection of bands but right ventriculotomy depresses right ventricular function and increases the risk of ventricular arrhythmias.^{15,16} Regardless of the approach, it is important to avoid damage to the tricuspid valve and its accessory structures.

The long-term prognosis for patients after intracardiac repair of DCRV is excellent. At a mean follow-up of 6 months, there were no death and all patients were asymptomatic.

Conflict of Interest - None.

References:

1. Alva C, Ho SY, Lincoln CR, Rigby ML, Wright A, Anderson RH. The nature of the obstructive muscular bundles in double-chambered right ventricle. *J Thorac Cardiovasc Surg* 1999;117:1180–9.
2. Pongiglione G, Freedom RM, Cook D, Rowe RD. Mechanism of acquired right ventricular outflow tract obstruction in patients with ventricular septal defect: an angiocardio-graphic study. *Am J Cardiol* 1982; 50:776– 80?
3. Maron BJ, Ferrans VJ, White RI. Unusual evolution of acquired infundibular stenosis in patients with ventricular septal defect. Clinical and morphologic observations. *Circulation* 1973;48:1092–103.
4. Cabrera A, Martinez P, Rumoroso JR, et al. Double-chambered right ventricle. *Eur Heart J* 1995;16:682–686.
5. Cil E, Saraclar M, Ozkutlu S, et al. Double-chambered right ventricle: experience with 52 cases. *Int J Cardiol* 1995;50: 19–29.
6. Forster JW, Humphries JO. Right ventricular anomalous muscle bundle. Clinical and laboratory presentation and natural history. *Circulation* 1971;43:115–127.
7. Fellows KE, Martin EC, Rosenthal A. Angiocardiology of obstructing muscular bands of the right ventricle. *Am J Roentgenol* 1977;128:249–256.
8. Warden HE, Lucas RV, Varco RL. Right ventricular obstruction resulting from anomalous muscle bundles. *J Thorac Cardiovasc Surg* 1966;51:53– 65.
9. Kveselis D, Rosenthal A, Ferguson P, Behrendt D, Sloan H. Long-term prognosis after repair of double-chamber right ventricle with ventricular septal defect. *Am J Cardiol* 1984;54: 1292–1295.
10. McElhinney DB, Chatterjee KM, Reddy VM. Double-chambered right ventricle presenting in adulthood. *Ann Thorac Surg* 2000;70:124–127.
11. Hartmann AF, Goldring D, Ferguson TB, et al. The course of children with the two- chambered right ventricle. *J Thorac Cardiovasc Surg* 1970;60:72– 83.
12. Li MD, Coles JC, McDonald AC. Anomalous muscle bundle of the right ventricle. Its recognition and surgical treatment. *Br Heart J* 1978;40:1040–1045.
13. Wallsh E, Weinstein G, Franzone AJ, Kania H, Cucci C. Anomalous right ventricular muscle bundle. Repair through the right atrium. *J Thorac Cardiovasc Surg* 1975;69: 830–834.
14. Penkoske PA, Duncan N, Collins-Nakai RL. Surgical repair of double-chambered right ventricle with or without ventric-ulotomy. *J Thorac Cardiovasc Surg* 1987;93:385–393.
15. Shimazaki Y, Kawashima Y, Mori T, Beppu S, Yokota K. Angiographic volume estimation of right ventricle. Re-evaluation of the previous methods. *Chest* 1980;77:390–395.
16. Kobayashi J, Hirose H, Nakano S, Matsuda H, Shirakura R, Kawashima Y. Ambulatory electrocardiographic study of the frequency and cause of ventricular arrhythmia after correction of Tetralogy of Fallot. *Am J Cardiol* 1984;54:1310–1313.
17. Galal O, Al-Halees Z, Solyman L, et al. Double-chambered right ventricle in 73 patients. Spectrum of the disease and surgical results of transatrial repair. *Can J Cardiol* 2000;16:167–174.