

# Effect of Mitral Valve Leaflets Excursion on Mitral Valve area after Percutaneous Transvenous Mitral Commissurotomy

Md. Abdul Mannan, AAS Majumder, Solaiman Hossain, Mohammad Ullah, SNI Kayes

Department of Cardiology, National Institute of Cardiovascular Diseases, Dhaka

### Abstract:

**Keywords:**  
Rheumatic  
heart disease,  
Mitral stenosis,  
PTMC.

**Background:** Aim of our study was to predict the effect of mitral valve leaflets excursion on mitral valve area following percutaneous transvenous mitral commissurotomy PTMC in patients of mitral stenosis.

**Methods:** Total 70 patients with severe mitral stenosis who underwent PTMC were enrolled in the study. Transthoracic echocardiography was done the day before PTMC and 24-48 hours after PTMC. Mitral valve area, anterior and posterior leaflets excursion were recorded. The relation between leaflet excursion and mitral valve after PTMC was evaluated.

**Results:** Following PTMC there were significant increase in anterior leaflet excursion from  $1.9 \pm 0.2$  to  $2.3 \pm 0.2$  cm ( $p < 0.001$ ), posterior leaflet excursion from  $1.6 \pm 0.2$  to  $1.9 \pm 0.2$  cm ( $p < 0.001$ ). Mitral valve areas increased from  $0.8 \pm 0.1$  to  $1.7 \pm 0.2$  cm<sup>2</sup> ( $p < 0.001$ ). Both leaflet excursion increased significantly with the increase in mitral valve area till the area reached a value of about 1.5 cm<sup>2</sup>, after which any further increase in mitral valve area was not associated with any further increase in leaflet excursion.

**Conclusion:** PTMC is associated with immediate significant changes in mitral valve morphology in terms of splitting of fused mitral commissures, increased leaflets excursion and splitting of the subvalvular structures. Post PTMC leaflet excursion increases significantly with the increase in mitral valve area till the area reaches a value of about 1.5 cm<sup>2</sup> after which any further increase in mitral valve area is not associated with any further increase in leaflet excursion.

(*Cardiovasc. j.* 2017; 10(1): 3-7)

### Introduction:

Rheumatic heart disease is the most common cause of mitral stenosis. Rheumatic heart disease is a chronic manifestation of rheumatic carditis, which occurs in 60% to 90% of cases of rheumatic fever. A community-based study showed the prevalence of rheumatic heart disease is 1.3 per 1000 in rural Bangladesh.<sup>1</sup> Mitral stenosis is a progressive disease that leads to heart failure and is finally fatal unless mechanical intervention enlarges the mitral valve orifice to permit adequate cardiac output at a tolerable left atrial pressure.<sup>2</sup> Management of the patients with mitral stenosis largely depends on medical, interventional and surgical management. After the introduction of percutaneous transvenous mitral commissurotomy it emerged as a safe and effective procedure for the treatment of symptomatic mitral stenosis in a selected group of patients.<sup>3</sup>

Dr. Kanzi Inoue introduced PTMC as an alternative to surgery in the treatment of mitral stenosis. The prototype of Inoue balloon catheter was manufactured in 1980. It was used clinically in 1982 and initial report on PTMC was published in 1984.<sup>4</sup> Since then it has turned out to be the procedure of choice.<sup>5</sup> The procedure is 90% technically successful and the long term durability of commissurotomy is excellent in those with pliable mitral valve leaflets and minimally deformed submitral apparatus.<sup>6</sup> The long term outcome after this procedure can be predicted from baseline clinical and valvular characteristics.<sup>7</sup>

Examination of pre-dilatation and post-dilatation echocardiograms showed that balloon dilatation reliably resulted in cleavage of the commissural plane and thus increase in valve area.<sup>8</sup>

Wilkins scoring system is the technique of determining grading of mitral valve morphology from echocardiographic examination which includes leaflets mobility, thickening, calcification and subvalvular thickening. A score of <8 predicts the best post procedure outcome.<sup>9-11</sup>

Previous studies have confirmed that this procedure is highly successful with a low complication rate and significant short and long term improvement in both haemodynamic and patients symptoms.<sup>12</sup> Short term improvement in mitral valve area (MVA) and symptoms may occur even when commissures are not split and it may be attributed to other mechanism, such as improvement of leaflets mobility secondary to disruption of the diseased submitral tissue.<sup>13</sup>

Evaluation of factors those determine the extent of valve leaflets mobility or excursion is necessary to predict haemodynamic changes with improved mitral leaflets excursion and outcome of PTMC.

#### Methods:

This Prospective observational comparative study is done in National Institute of Cardiovascular Diseases (NICVD), Dhaka, from September, 2014 to March, 2015. 70 patients were selected with severe mitral stenosis (mitral valve area <1.0 cm<sup>2</sup>), Wilkin's score d"8 and isolated mitral stenosis or with mild mitral regurgitation. Transthoracic echocardiography was done the day before PTMC, immediately after PTMC for procedural success and complications and 24-48 hours after PTMC by one expert. PTMC was done with all aseptic precaution through femoral approach under local anesthesia by the antegrade trans-septal approach using an Inoue balloon technique and a stepwise dilatation strategy. Successful PTMC was defined as post valvuloplasty valve area > 1.5 cm<sup>2</sup> or e"100% increase in the mitral valve area without significant complications.

Standard echocardiographic measurements were taken and averaged in 4 cardiac cycles. Mitral valve leaflets excursion is measured in parasternal long axis view, at maximum doming inearly diastole. A line was drawn at the level of mitral valve annulus(at the base of the leaflets), and then 2 perpendicular lines were dragged from the tip of the leaflets on that line. The distance from tip to the perpendicular line is the excursion and was

measured in cm. Mitral valve area was measured by planimetry in parasternal short axis view and expressed in square cm.

#### Statistical Analysis

Data were expressed as mean  $\pm$ SD. Analysis is employed the student's t-test to determine the significance of difference before and after PTMC in patients with MS. To show the relationship between the variables Pearson correlation analysis is performed. Linear regression analysis was used to study the predictors of post-PTMC leaflet excursion. P-value < 0.05 is considered statistically significant. All the data entry and analysis was done by using SPSS and NCSS software program.

#### Results:

##### Demographic characteristics:

One-third (34.3%) of the patients was below 30 years of age and two-third (65.7%) was 30 or more than 30 years of age. The mean age of the patients was  $30.1 \pm 7.6$  years and the lowest and highest ages were 14 and 46 years respectively. Sixty percent of the patients were female. (Table-I).

**Table-I**  
*Distribution of patients by demographic characteristics (n= 70).*

Demographic characteristics	Frequency	Percentage
Age (years)		
<30	25	34.3
$\geq$ 30	45	65.7
Sex		
Male	28	40.0
Female	42	60.0

#### Echocardiographic findings before and after PTMC:

Pulmonary arterial systolic pressure, left atrial diameter and transmitral peak pressure gradient were significantly reduced after PTMC ( $55.5 \pm 19.4$  vs.  $31.5 \pm 9.4$  mmHg,  $p < 0.001$ ;  $4.4 \pm 0.6$  cm vs.  $3.9 \pm 0.6$  cm,  $p < 0.001$ ;  $2.9 \pm 0.5$  vs.  $2.7 \pm 0.5$  cm,  $p < 0.001$  and  $24.3 \pm 7.2$  vs.  $10.4 \pm 3.4$  mmHg,  $p < 0.001$ ). On the other hand, mitral valve area, anterior mitral leaflet excursion, posterior mitral leaflet excursion significantly increased after PTMC compared to their baseline figures ( $p < 0.001$ ).

**Table-II**  
*Comparison of echocardiographic findings before and after PTMC*

Echocardiographic findings	Groups		p-value
	Before PTMC	After PTMC	
Anterior mitral leaflet excursion (cm)	1.9 ± 0.2	2.3 ± 0.2	<0.001
Posterior mitral leaflet excursion (cm)	1.6 ± 0.2	1.9 ± 0.2	<0.001
Mitral valve area (cm <sup>2</sup> )	0.8 ± 0.1	1.7 ± 0.2	<0.001
Subvalvular splitting area (cm <sup>2</sup> )	0.8 ± 0.2	1.2 ± 0.2	<0.001
Transmitral peak Pressure gradient (mmHG)	24.3 ± 7.2	10.4 ± 3.4	<0.001
Left atrial diameter (cm)	4.4 ± 0.6	3.9 ± 0.6	<0.001
Pulmonary artery systolic pressure (mm Hg)	55.5 ± 19.4	31.5 ± 9.4	<0.001

# Paired t-Test was done to analyses the data and Presented as Mean ± SD.

**Table-III**  
*Correlation of mitral valve area and other echocardiographic parameters with anterior mitral leaflet excursion following PTMC.*

Correlated variables		Correlation	p-value
Independent(X)	Dependent (Y)	co-efficient (r)	
Mitral valve area (cm <sup>2</sup> )	Anterior mitral leaflet excursion	0.369	0.004
Trans-mitral peak pressure gradient	Anterior mitral leaflet excursion	-0.392	0.002
Subvalvular splitting area (cm <sup>2</sup> )	Anterior mitral leaflet excursion	0.469	<0.001

**Table IV**  
*Correlations of mitral valve area and other echocardiographic parameters with posterior mitral leaflet excursion following PTMC.*

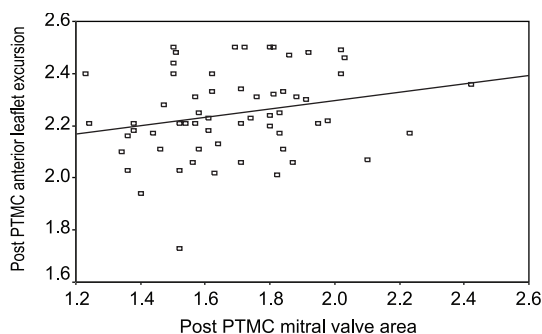
Correlated variables		Correlation	p-value
Independent(X)	Dependent (Y)	co-efficient (r)	
Mitral valve area (cm <sup>2</sup> )	Posterior r mitral leaflet excursion	0.293	0.023
Trans-mitral peak pressure gradient	Posterior mitral leaflet excursion	0.314	0.014
Subvalvular splitting area (cm <sup>2</sup> )	Posterior mitral leaflet excursion	0.393	0.002

**Table-V**  
*Linear predictors of improved anterior leaflet Excursion*

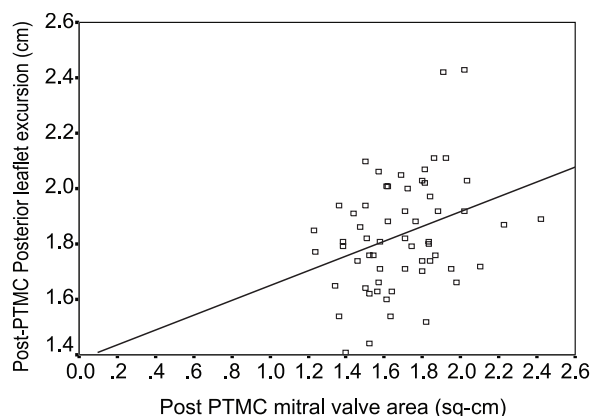
Independentvariables	Standardized coefficients(Beta)	95% CI	p-value
Mitralvalve area (cm <sup>2</sup> )	0.093	0.052– 0.140	0.550
Subvalvular splitting area (cm <sup>2</sup> )	0.231	0.061– 0.433	0.037
Transmitral pressure gradient (mm Hg)	-0.215	-0.120 – -0.311	0.027

**Table-VI**  
*Linear predictors of improved posterior leaflet Excursion*

Independentvariables	Standardized coefficients (Beta)	95% CI	p-value
Mitralvalve area (cm <sup>2</sup> )	0.190	0.095– 0.416	0.214
Subvalvular splitting area (cm <sup>2</sup> )	0.224	0.183– 0.373	0.010
Transmitral pressure gradient (mm Hg)	-0.197	-0.098 – -0.264	0.036



**Fig.-1:** Correlation between mitral valve area and anterior mitral leaflet excursion.



**Fig.-2:** Correlation between mitral valve area and posterior mitral leaflet excursion.

Considering the procedural complication, 1 patient (1.4%) developed severe MR grade III, 6 patients (8.5%) MR grade II, 8 patients (11.4%) MR grade I. Local vascular complications e.g. hemorrhage, hematoma developed in 6 patients (8.5%) and 1(1.4%) patient developed pericardial effusion.

### Discussion:

Rheumatic heart disease is the most common cause of mitral stenosis. Mitral stenosis is a progressive disease that leads to heart failure and is finally fatal unless mechanical intervention enlarges the mitral valve orifice to permit adequate cardiac output at a tolerable left atrial pressure.<sup>2</sup>

Over the past two decades PTMC has become an accepted alternative to surgery in the treatment of patients with mitral stenosis. Previous studies have confirmed that this procedure is highly successful with a low complication rate and significant short- and long- term improvement in both hemodynamics and patient symptoms.<sup>14-16</sup> The present study demonstrates that PTMC produces

significant morphologic and hemodynamic changes in the mitral valve. We found that PTMC produced a significant increase in MVA and a significant splitting of both mitral commissures. Subvalvular fibrosis with fusion and shortening of the chordae tendinae causes obliteration of the interchordal spaces which are considered as secondary orifices for blood flow, below the main orifice formed by the leaflets. Commissural fusion causes valvular stenosis and is affected in 76% of cases.<sup>17</sup>

In mitral stenosis the chordae are occasionally retracted so that the leaflets appear to be inserted directly into the papillary muscles, and the interchordal spaces are entirely obliterated. They recommended that mitral commissurotomy on such a valve must include splitting of the papillary muscles as well as the commissures. In our study PTMC caused a significant improvement in valve mobility, reflected as increase in both anterior and posterior leaflets excursion. PTMC more closely resembles closed mitral commissurotomy, which has a limited effect on subvalvular apparatus.<sup>13</sup> It was supposed that the valve mobility is the result of all the pathologic processes in the mitral valve apparatus that results in stenosis rather than an independent variable. So, it is affected by the degree of commissural fusion, leaflet thickness, calcification and subvalvular fusion. Mitral valve area and subvalvular splitting area were observed to be positively correlated with both mitral leaflet excursions, while transmitral pressure gradient was found to be negatively correlated to both mitral leaflet excursions.

Leaflet excursion was found to increase with increased post-PTMC mitral valve area till it reaches a value around 1.5 cm<sup>2</sup> after which the relationship became insignificant. Post PTMC mitral valve area failed to predict both anterior and posterior leaflets excursion.

### Conclusion:

The increase in leaflets excursion after PTMC is determined by several morphologic and hemodynamics changes produced in the valve. According to our study, leaflets excursion increased significantly with increased MVA till the area reaches a value of about 1.5 cm<sup>2</sup>, after which any further increase in MVA was not associated with any further increase in leaflets excursion in both leaflets.

---

**Conflict of Interest - None.**


---

**References:**

1. Ahmed J, Zaman MM, Hasan MMM. Prevalence of rheumatic fever and rheumatic heart disease in rural Bangladesh. *Tropical Doctor* 2005; 35(3): 160-161.
2. Fawzy ME. Percutaneous mitral balloon valvotomy. *Catheter Cardiovasc Interv* 2007; 69: 313-321.
3. Arora R, Karla GS, Murty GS, Trehan V, Jolly N, Mohan JC, et al. Percutaneous transatrial mitral commissurotomy: Immediate and intermediate results. *J Am Coll Cardiol* 1994; 23:1327-1332.
4. Inoue K, Owaki T, Nakamura T, Kitamura F, Myamoto N. Clinical application of transvenous mitral commissurotomy by a new balloon catheter. *J Thorac Cardiovasc Surg* 1984; 87(3): 394-402.
5. Heldick-Smith DJR, Taylor GJ, Shapiro LM. Inoue balloon mitral valvuloplasty: Long term clinical and echocardiographic follow-up of a predominantly unfavourable population. *Eur Heart J* 2000; 21; 1690-1697.
6. Inoue K, Feldman T. Percutaneous transvenous mitral commissurotomy using the Inoue balloon catheter. *Catheter Cardiovasc Diagn* 1993; 28(2): 119-125.
7. Fawzy ME, Hegazy H, Shoukri M, Shaer F, EIDali A, Al-Amri M. Long-term clinical and echocardiographic results after successful mitral balloon valvotomy and predictors of long-term outcome. *Eur Heart J* 2005; 26(16):1647-1652.
8. Wilkins GT, Weyman AE, Abascal VM, Block P, Palacios I. Percutaneous balloon dilatation of mitral valve: an analysis of echocardiographic variables related to outcome and the mechanism of dilatation. *Br Heart J* 1988; 60: 299-308.
9. Rahman M, Sohrabuzzaman APM, Nazneen S, Taimur SDM, Pathan S. Value of padial echocardiographic score in prediction of mitral regurgitation during balloon mitral valvuloplasty. *Bangladesh J Cardiol* 2009; 1(2):110-115.
10. Wilkins GT, Weyman AE, Abascal VM, Palacios I. Percutaneous balloon dilatation of mitral valve: an analysis of echocardiographic variables related to outcome and the mechanism of dilatation. *Br Heart J* 1988; 60: 299-308.
11. Palacios IF, Block PC, Wilkins GT, Weyman AE. Follow-up of patients undergoing percutaneous mitral balloon valvotomy: Analysis of factors determining restenosis. *Circulation* 1989; 79: 573-579.
12. Fawzy ME. Percutaneous mitral balloon valvotomy. *Catheter Cardiovasc Interv* 2007; 69:313-321.
13. Levin T, Feldman T, Bednarz J, Carroll J, Lang R. Transesophageal echocardiographic evaluation of mitral valve morphology to predict outcome after balloon mitral valvotomy. *Am J Cardiol* 1994; 73: 707-710.
14. Arora R, Karla GS, Murty GS, Trehan V, Jolly N, Mohan JC, et al. Transatrial mitral commissurotomy: Immediate and intermediate results. *J Am Coll Cardiol* 1994; 23:1327-1332.
15. Hernandez R, Banuelos C, Alfonso F, Goicolea J, Fernandez-Ortiz A, Escaned J, et al. Long term clinical and echocardiographic follow-up after Percutaneous mitral valvuloplasty with the Inoue balloon. *Circulation* 1999; 99:1580-1596.
16. Reid CL, Otto CM, Davis KB, Labovitz A, Kisslo KB, McKay CR. Influence of mitral valve morphology on mitral balloon commissurotomy: immediate and six-month results from the NHLBI Balloon Valvuloplasty Registry. *Am Heart J* 1992; 124: 657-665.
17. Reid CL, Chandraratna PA, Kawanishi DT, Kotlewski A, Rahimtoola SH. Influence of mitral valve morphology on double-balloon catheter balloon valvuloplasty in patients with mitral stenosis. Analysis of factors predicting immediate and 3-month results. *Circulation* 1989; 80: 515-524.