

Coronary Endarterectomy with off Pump Coronary Artery Bypass Surgery- A Review

Redoy Ranjan¹, Dipannita Adhikary², Heemel Saha², Sanjoy Kumar Saha³, Sabita Mandal⁴, Asit Baran Adhikary¹

¹Department of Cardiac Surgery, BSMMU, Dhaka, ²Al Helal Specialized Hospital, Dhaka, ³Department of Cardiac Anesthesia, BSMMU, Dhaka, ⁴Department of Community Medicine, Shaheed Suhrawardy Medical College, Dhaka

Abstract:

Key words:

Coronary endarterectomy, Coronary artery disease, Coronary artery bypass.

Coronary endarterectomy is first described as an alternative surgical procedure for myocardial revascularization against diffuse coronary artery disease by Baily et al. in 1956. Coronary endarterectomy provides complete surgical revascularization of the myocardium in diffuse and calcified coronary arteries with adequate blood flow to distal part of occluded arteries, thus improving ventricular function. However, the initial outcomes of coronary endarterectomy were not satisfactory but now-a-days different studies have shown that coronary endarterectomy with coronary artery bypass grafting can be done safely with acceptable morbidity and mortality. Moreover, the graft patency rate on angiographic evaluation is also good following coronary endarterectomy. So, it's time to reevaluate this old techniques, and reanalysis the current outcomes of coronary endarterectomy and readdress its indication in diffuse coronary artery disease.

(*Cardiovasc. j.* 2017; 10(1): 84-90)

Introduction:

Patients, who are referred for coronary artery bypass graft surgery, are progressively getting more complex with different comorbidities, like DM, renal impairment, hypertension, and also peripheral vascular disease. However, a large portion of this group of patients have experienced previous coronary angioplasty.^{1,2} Total myocardial revascularization is the basic principle for postoperative outcomes following coronary artery bypass graft surgery (CABG). But now-a-days, referred patients for CABG frequently have diffuse and calcified coronary artery disease, which has made complete surgical revascularization of myocardium more difficult and more complicated postoperative recovery.^{3,4} However, up to 25% of patients with diffuse coronary artery disease can't be treated viably and safely by conventional CABG and bringing it as incomplete myocardial revascularization.^{1,5} Inadequate revascularization does not influence the immediate death rate, but rather increase the rate of coronary restenosis which adversely affect the long term cardiac function. These patients have repeated attack of angina, more awful performance in stress tests and a more noteworthy work absence rate and

require a higher number of re-interventions.⁶ That's why a couple of strategies including coronary endarterectomy (CE), which incorporates extraction of the atherosclerotic plaque through an incision (arteriotomy) from coronary arteries have been proposed to increase postoperative outcome following CABG.^{1,7}

Coronary endarterectomy was first described by Baily et al. in late 1956 as a treatment strategy for diffuse CAD without doing CABG.^{1,6,7} Coronary endarterectomy procedure is as yet a matter of controversy.⁸⁻¹⁰ In particular, LAD endarterectomy was considered as highly troublesome and initial perioperative mortality and myocardial ischemia rate was very high.¹¹⁻¹³ Complete revascularization of the LAD is considered as a crucial determinant of the post-operative patient's recovery.¹⁴ There are very few articles revealing concurrent CE with OPCABG surgery. Off-pump CABG surgery for multi vessel myocardial revascularization in high risk patients has been appeared to decrease the frequency of perioperative morbidity and mortality and the duration of hospital stay.^{15,16} Nevertheless, its adverse outcome with mortality and morbidity overshadowed its results in relief of angina. Hence,

indications of coronary endarterectomy were limited to patients with diffuse coronary artery disease.^{1,17} Since then, several study have shown that the complete myocardial revascularization of coronary artery disease by CABG with CE can be done safely and it enhanced the post-operative outcomes by improving myocardial function.¹⁸⁻²⁰

Definition and types of Coronary Endarterectomy

Coronary Endarterectomy is a surgical procedure involving the removal of atheromatous plaque, and isolating the outer media and adventitia layers of artery and reestablishing the blood flow to the distal part of to the coronary artery (Figure-1). A conclusive decision to do endarterectomy of a vessel is made per-operatively and depends on technical contemplations. Coronary endarterectomy was considered when no sufficient segment of a vessel, providing blood supply to viable muscle with reversible ischemia, was appropriate for grafting. Endarterectomy of the unhealthy vessel was just performed when the artery was totally or almost impeded with severely calcified plaques and long segment stenosis that extends distally. There are two various approaches to perform coronary endarterectomy: Open method and Close method. But till now, it is unclear which the perfect procedure is.²¹ But there is a common practice between these two strategies to remove atherosclerotic plaque that is an arteriotomy is the basic principle in both methods.¹⁷

How to perform CE?

In open methods, a longitudinal incision for coronary arteriotomy is performed distal to the atheromatous

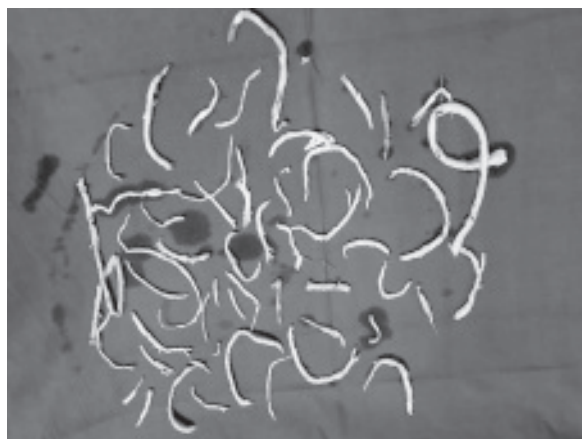

Fig-1: Collected Coronary atheromatous plaque during CABG surgery.

plaque and extracted the atheroma from vessel,²¹ followed by reconstruction of endarterectomized site with on lay patch either with Internal thoracic artery or a saphenous venous patch.^{22,23} However, a longitudinally opened saphenous vein can be used to repair the arteriotomy and thereafter the left internal mammary artery can be anastomosed with the vein patch.⁵ Note that, this open method is time consuming but the atheromatous plaque is extracted under direct vision, so the openings of the distal end of the LAD and side branches can be checked directly. Furthermore, it can be settled to secure the distal portion of artery following an intimal dissection of the coronary artery happens.²

In the close method, coronary endarterectomies were performed manually by slow sustain and continuous traction of atheroma trailed by reproduction with anastomosis with pre-planned graft.^{2,23} Two synchronous arteriotomy can be used for coronary endarterectomy to make the framework rapid and reduce ischemic time.²⁴ The close method is shorter in duration and the graft anastomosis is easier than open method.²⁵ But the rate of snowplow effect is more in LAD following closed method as inadequate endarterectomy is more possible.²⁶ Despite delicate balance of traction force, closed endarterectomy may have associated with intimal flap on distal part of endarterectomized vessel. Accordingly, obstacle of the lumen may happen distally as a result of a dissection or thrombus.^{2,24}

However, regardless of the way that the open endarterectomy takes extra time; the chance of intimal flap formation is less and subsequently preventing residual obstruction. So that, some author used the open technique for coronary endarterectomy, the quality is guaranteed.¹⁷ Nishi et al. observe the outcome of both closed and open methods endarterectomy and finds that open method endarterectomy is superior to closed one.²² Patients who experienced open method endarterectomy had a lower perioperative morbidity and mortality. Perhaps, this group of patients have significant long term outcome.

The five-year survival rate was 74% in closed endarterectomy group but 90.7% in open method group. Also 85.2% patients of open method group are free from angina in compare to closed method where only 76.6% patients were from angina on subsequent follow up. So that, though open method

is time consuming but the outcome is the better than closed one.²² To ensure complete expulsion of the distal atheroma, the atheromatous plaque carefully inspected for a smooth distal taper end (Figure-2). In addition, back flow of blood from the distal vessel following extraction of the atheroma is a consoling indication of adequate removal atheromatous plaque and that is special feature in OPCABG endarterectomy.^{15,27,28}

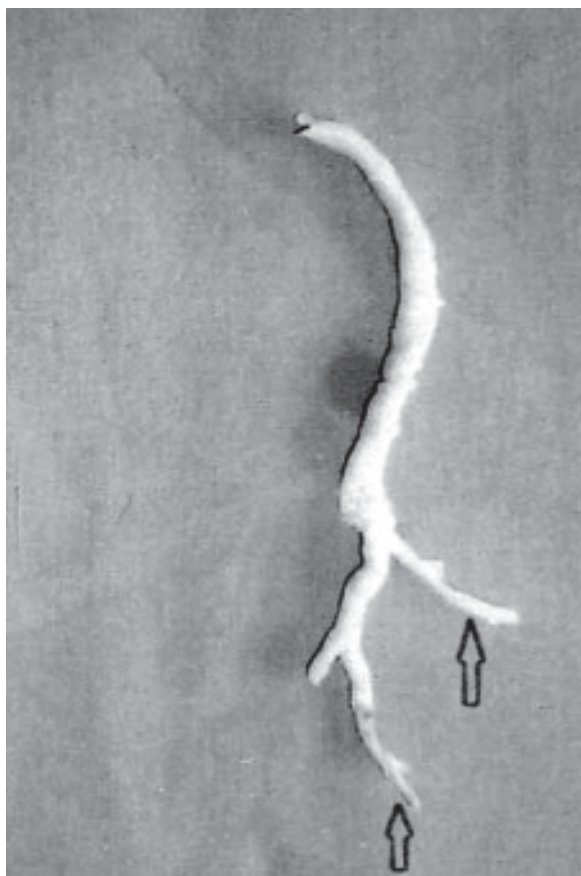


Fig-2: Distal taper end (arrow marked) indicate complete removal of atheromatous plaque.

What are the Operative Criteria for CE?

Coronary endarterectomy (CE) is performed when the coronary vessel is extremely affected by atherosclerotic process, so that conventional CABG is insufficient to provide adequate myocardial revascularization. Also, neither immature atherosclerotic plaques nor extensive calcification are contraindications to procure a delightful anastomosis after coronary endarterectomy.² However, CE provides more collateral circulation via side branches in case of diffuse CAD. Perhaps,

if an anastomosis is performed in calcified vessel, embolization of atheromatous plaque may happen. So in presence of diffuse atherosclerosis with calcification of coronary artery, CE is required to provide good distal run off in diseased coronary artery.^{5,7} Shapira et al. stated that preoperative coronary angiographic findings like irregular thickening with diffuse string like appearance and lumen less than 1mm in diameter can constitute signs for endarterectomy.²⁵ However, a conclusive decision to perform endarterectomy is made per-operatively when the above criteria are noted.^{17,24} Trehan and Mishra are accounted the essential indications for coronary endarterectomy:⁴

- I. Multiple lesions in a coronary artery.
- II. Diffusely disease coronary artery with calcified plaque.
- III. Long segment of lesion.
- IV. Disruption of the plaque during coronary anastomosis.
- V. Occlusion of the main artery and its branches.

Postoperative Anticoagulation therapy

Following coronary endarterectomy, in absence of endothelium, coagulation cascade become activated because sub-endothelium exposed to circulation.⁵ So that, after coronary endarterectomy, routine Heparin infusion is prescribed to prevent thrombosis in graft or native tissue in the early post-operative period followed by oral warfarin for next 6 months.^{10,23} Perhaps, combination of antiplatelet and anticoagulation is also required². Till date, there is no standard anticoagulation regimen after coronary endarterectomy exists.²¹ Postoperatively, intravenous heparin, 75 mg combination of Aspirin with Clopidogrel, and warfarin are used. Heparin is continued until desired warfarin effect achieved that is INR (International normalized ratio) is 1.5 to 2.5. After 3-6 months, use of warfarin is suspended for Clopidogrel and Ecosprin.^{5,17,22}

Prognosis of CE in diffuse CAD

In CAD, inadequate myocardial revascularization has been appeared to be a standout amongst the most critical components that influences perioperative outcome, ventricular function, early and late mortality.¹⁴ However, LAD endarterectomy is thought to be higher hazardous than other territory, and in this way, it might be stayed away

from by a few surgeons. Perhaps, complete revascularization of the LAD is considered as a crucial determinant of the post-operative patient's recovery and it can achieve adequate myocardial revascularization and provide better post-operative outcome.^{14,24} Myocardial contraction in the LAD territory is more vigorous than the RCA region. Those aides in the extraction of the distal atheromatous plaque by traction technique easily from LAD artery as compared to expulsion in the RCA.¹⁸ Previously, the internal mammary artery (IMA) has been utilized cautiously as a conduit to an endarterectomized vessel as a result of concerns in regards to the mismatch of luminal diameter. Perhaps, many authors have now detailed satisfactory early and late clinical results and luminal patency of IMA to an endarterectomized vessel compared to great saphenous vein conduit.^{8,10} It has been contended that the utilization of the IMA for reproduction of the LAD graft prompts early patency, decreased perioperative myocardial dead tissue, and enhanced 5-year survival rate.²⁹

In another study at the Shin-Tokyo Specialist's center and the Sakakibara Heart Association included 148 patients, who experienced CE of the LAD between 2001 and 2008.² They performed 81.8% Off-pump CABG with CE and mortality rate was 2.7%. Among them 6.1% patients were suffered from LOS (low cardiac output syndrome), 25.7% developed new onset AF, 12.2% were postoperative MI. Other co-morbidity was insignificant like 6.8% respiratory complications, 3.4% reoperation due to bleeding, 2.7% stroke, 3.4% required renal replacement therapy and 3.4% patents developed mediastinitis. Early postoperative angiography revealed 94% graft patency rate for both left internal mammary artery and LAD. Only one patient suffered from graft failure due to thrombosis and had post-operative MI; however the early mortality was zero. Shapira et al. observed 37 patients who experienced LAD endarterectomy shows, only 2.7% intra-operative mortality rate and one case of perioperative MI were viewed.²⁴ In another study including 61 patients, Shapira et al. observed 3.3% intraoperative mortality who experienced RCA endarterectomy, and a 4.9% perioperative MI. During follow up (14–55 months) revealed one patient's death whose preoperative LVEF was 27%. The cause of death after five months of operation was due to of congestive cardiomyopathy.²⁵

In a study, Djalilian et al. shows only 9% of their patients got angina at 46±19 months follow up, though Gill et al. observed intermittent angina in 15% of their patients at a mean follow-up of 36±16 months.^{8,10} Post-operative acute myocardial infarction (MI) due to acute graft occlusion is a noteworthy complication following CE with an incidence rate of 1.5% to 19%.¹⁰ The occurrence of post-operative MI in our patients is 3.5%. Naseri et al. revealed a higher postoperative MI rate of 6.8% after OPCABG with CE in completely blocked or more than >50% stenosis.²⁰ But in another study, Vohra et al. observed that postoperative MI rate following OPCABG with coronary endarterectomy is 4.3% and 10% recurrence rate of angina following OPCABG with coronary endarterectomy.¹⁸ However, Christakis et al. observed 35% recurrence rate of angina at 5 years follow up in their study, which is significantly higher than our study.³⁰ This distinction in recurrence of side effects might be because of the especially extreme nature of the coronary disease or to inadequate revascularization accomplished.

In another study, Takahashi et al. observed the mortality rate is zero percent in a small study of CE with OPCABG and conversion of procedure to on-pump CABG rate is 8.33%. Post-operative morbidity was very minimum with no perioperative stroke or MI. Reoperation rate was 16.66% due to excessive bleeding and post-operative new onset atrial fibrillation rate also 16.66%. One patient developed respiratory complications who require tracheostomy. Postoperative mean follow-up period was 24 ± 19 months; revealed neither early nor mid-term myocardial ischemia.²³ Naseri et al. likewise demonstrated that the intubation time, ICU stay, and the length of hospitalization was not exactly same between on pump CABG with coronary endarterectomy (CE) and after OPCABG with CE.²⁰ Besides, in spite of the fact that the duration of ventilation was comparative in our review and that of Eryilmaz et al. the length of hospitalization was higher in the last arrangement.¹⁹

Nishi et al. studied 127 patients with diffuse CAD who experienced CE with CABG in the year of 1994 to 2003.²² This audit endorsed that coronary endarterectomy is related to an acceptable operator risk as mortality rate was 4.7%, however only 3% patients experienced perioperative MI. Infection was

found in six cases, six patients required re-operation for excess bleeding, and only two patients have had TIA. Furthermore, intra-aortic balloon pump was required 17% patients and late mortality rate was 15.75%.²² Finally, Livesay et al. observed long term benefits following CE in their study over a period of 14 years includes a large study group about 27095 patients. Of whom 12.4% patients experienced CE and they observed that 10 year's survival rate was 68% which is very close to only CABG group 74%.¹²

Although multi-vessel endarterectomy has been described but single vessel especially LAD endarterectomy is preferred as adequate stabilization of LAD is easier, can be easily visible throughout its full length and less mobilization of heart is required to achieve CE during OPCABG.³¹ However, Erdil et al. shows that clinical and

angiographic findings is excellent following right coronary endarterectomy and no additional mortality or morbidity is associated with CABG following RCA endarterectomy in relation to non-endarterectomized RCA during CABG.³² However, early mortality rate is accounted to be higher after LAD endarterectomy and in patients experiencing endarterectomy of more than one coronary artery.⁹ The frequency of early mortality after CE with OPCABG of 2%-15%.³¹ However, long term graft patency rate following CE is 40%- 81.5% and single CE carries better result than multiple endarterectomy.^{10,22,33} By the way, postoperative MI rate also high following multiple CE, no matter which artery is incorporated.³³

Here, we present in detail with the outcomes of a couple of surveys of coronary endarterectomy due to diffuse CAD (Table- I).

Table-I
Experience of Coronary endarterectomy (CE) by different surgeons.

Author, Year	CE%	LCA%	RCA%	Perioperative MI	Early Mortality
Cooley et al. 1971	38%	?	?	?	7.7%
Qureshi et al. 1985	42%	?	72%	12%	4%
Livesay et al. 1986	12.4%	?	83%	5.4%	4.4%
Fundaro et al. 1987	100%	72.2% (LAD)	27.2%	5.6%	0%
Brenowitz et al. 1988	50%	?	51.7%	10%	8.3%
Shapira et al. 1988	100%	100% (LAD)	27.0%	2.7%	2.7%
Trehan et al. 1993	12.4%		62.9%	?	?
Salerno et al. 1994	3.9%	?	61.8%	9%	4.5%
Gill et al. 1998	21.9%	?	?	21.6%	4%
Asimakopoulous et al. 1999	4.1%	?	51.5%	5.4%	3.6%
Tyszka et al. 2003	11.5%	?	21.0%	3.12%	3.12%
Nishi et al. 2005	100%	55.9% (LAD), 13.7% (LCX), 5.5% (D)	41.7%	?	4.7%
Vohra et al. 2006	10.2%	17% (LAD), 1.43% (OM)	81%	4.3%	2.85%
Takanashi et al. 2008	100%	100% (LAD)	?	12.2%	2.7%
Schmitto et al. 2009	100%	50% (LAD),	52.8%	2.9%	4.8%
Takahashi et al. 2013	100%	100% (LAD)	?	0%	0%
Alreshidan et al. 2014	20.0%	52.6% (LAD), 18.4% (OM), 3% (D)	31.5% (RCA, PDA)	2.6%	7.9%

Note: CE-Coronary endarterectomy, LCA-Left coronary artery, LAD- Left anterior descending artery, OM-Obtuse marginal artery, D- Diagonal artery, RCA-Right coronary artery, PDA-Posterior descending artery.

Conclusion:

Despite the higher risk group, coronary endarterectomy is attainable and accomplishes surgical revascularization in a patient with diffuse coronary artery disease when there is no other alternative for sufficient myocardial revascularization. However, coronary endarterectomy is not an alternative to CABG, but an adjunctive to CABG in treating diffuse calcified CAD.

Conflict of Interest - None.**References:**

- Bailey CP, May A, Lemmon WM. Survival after coronary endarterectomy in man. *J Am Med Assoc.* 1957; 164:641–646.
- Takanashi S, Fukui T, Miyamoto Y. Coronary endarterectomy in the left anterior descending artery. *J Cardiol* 2008; 52:261–268.
- Elbardissi AW, Balaguer JM, Byrne JG, Aranki SA. Surgical therapy for complex coronary artery disease. *Semin Thorac Cardiovasc Surg* 2009; 21: 199–206.
- Trehan N, Mishra A. Endarterectomy complex coronary reconstructions. In: Buxton B, Frazier OH, Westaby S. Ischemic heart disease surgical management. New York: Mosby. 1999; 221–228.
- Santini F, Casali G, Lusini M, D'Onofrio A, Barbieri E, Rigatelli G, et al. Mid-term results after extensive vein patch reconstruction and internal mammary grafting of the diffusely diseased left anterior descending coronary artery. *Eur J Cardiothorac Surg* 2002; 21:1020–1025.
- Lawrie GM, Morris Jr GC, Silvers A, Wagner WF, Baron AE, Beltangady SS, et al. The influence of residual disease after coronary bypass on the 5-year survival rate of 1274 men with coronary artery disease. *Circulation.* 1982; 66:717–723.
- Fundarò P, Di Biasi P, Santoli C. Coronary endarterectomy combined with vein patch reconstruction and internal mammary artery grafting: experience with 18 patients. *Tex Heart Inst J* 1987; 14: 389–394.
- Gill IS, Beanlands DS, Boyd WD, Finlay S, Keon WJ. Left anterior descending endarterectomy and internal thoracic artery bypass for diffuse coronary disease. *Ann Thorac Surg* 1998; 65:659–662.
- Mills NE. Coronary endarterectomy: surgical techniques for patients with extensive distal atherosclerotic coronary disease. *Adv Cardiac Surg* 1998; 10:197–227.
- Djalilian AR, Shumway SJ. Adjunctive coronary endarterectomy: improved safety in modern cardiac surgery. *Ann Thorac Surg* 1995; 60:1749–1754.
- Cheanvechai C, Groves LK, Reyes EA, Shirey EK, Sones Jr FM. Manual coronary endarterectomy: clinical experience in 315 patients. *J Thorac Cardiovasc Surg* 1975; 70: 524–528.
- Livesay JJ, Cooley DA, Hallman GL, Reul GJ, Ott DA, Duncan JM, et al. Early and late results of coronary endarterectomy: analysis of 3,369 patients. *J Thorac Cardiovasc Surg* 1986; 92: 649–660.
- Parsonnet V, Gilbert L, Gielchinsky I, Ehaktan EK. Endarterectomy of the left anterior descending and mainstem coronary arteries: a technique for reconstruction of in operable arteries. *Surgery* 1976; 80: 662–673.
- Schaff HV, Gersh BJ, Pluth JR, Danielson GK, Orszulak TA, Pugaet FJ, al. Survival and functional status after coronary artery bypass grafting: results 10 to 12 years after surgery in 500 patients. *Circulation* 1983; 68:200–204.
- Berson AJ, Smith JM, Woods SE, Hasselfeld KA, Hiratzka LF. Off-pump versus on-pump coronary artery bypass surgery: does the pump influence outcome? *J Am Coll Surg.*2004; 199: 102–108.
- Al-Ruzzeh S, Nakamura K, Athanasiou T, Wray J, Ilsley C, Athanasiou T, et al. Does off-pump coronary artery bypass (OPCAB) surgery improve the outcome in high-risk patients? A comparative study of 1398 high-risk patients. *Eur J Cardiothorac Surg.* 2003; 23:50–55.
- Schmitto JD, Kolat P, Ortmann P, Popov AF, Coskun KO, Friedrich M, et al. Early results of coronary artery bypass grafting with coronary endarterectomy for severe coronary artery disease. *J Cardiothorac Surg.*2009; 4: 52.
- Vohra HA, Kanwar R, Khan T, Dimitri WR. Early and Late Outcome after Off-Pump Coronary Artery Bypass Graft Surgery with Coronary Endarterectomy: A Single-Center 10-Year Experience. *Ann Thorac Surg.* 2006; 81:1691–1696.
- Eryilmaz S, Inan MB, Eren NT, Yazicioglu L, Corapcioglu T, Akalin H. Coronary endarterectomy with off-pump coronary artery bypass surgery. *Ann Thorac Surg* 2003; 75: 865–869.
- Naseri E, Sevinc M, Erk MK. Comparison of off-pump and conventional coronary endarterectomy. *Heart Surg Forum* 2003; 6:216–219.
- Tiruvoipati R, Loubani M, Peek G. Coronary endarterectomy in the current era. *Curr Opin Cardiol* 2005; 20:517–520.
- Nishi H, Miyamoto S, Takanashi S, Minamimura H, Ishikawa T, Shimizu Y. Optimal method of coronary endarterectomy for diffusely diseased coronary arteries. *Ann Thorac Surg* 2005; 79:846–853.
- Takahashi M, Gohil S, Tong B, Lento P, Filsoufi F, Reddy RC. Early and midterm results of off-pump endarterectomy of the left anterior descending artery. *Interact Cardiovasc Thorac Surg.*2013;16:301–305.

24. Shapira N, Lumia FJ, Gottdiener JS, Germon P, Lemole GM. Adjunct endarterectomy of the left anterior descending coronary artery. *Ann Thorac Surg* 1988; 46: 289–296.
25. Shapira OM, Akopian G, Hussain A, Adelstein M, Lazar HL, Aldea GS, et al. Improved clinical outcomes in patients undergoing coronary artery bypass grafting with coronary endarterectomy. *Ann Thorac Surg* 1999; 68: 2273–2278.
26. Effler DB. Myocardial revascularization: a 14 year overview of the Cleveland Clinic experience. *JAMA* 1976; 235:828–832.
27. Salerno PR, Dinkhuysen JJ, Chaccor P, Neto CA, Santos MA, de Souza LCB, et al. Técnica e resultados da endarterectomia de artéria coronária. *Rev Bras Cir Cardiovasc*. 1994; 9:152-158.
28. Cooley DA, Hallman GL, Wukasch DC. Myocardial revascularization using combined endarterectomy and vein bypass autograft: technique and results. *Int Surg*. 1971; 56:373-380.
29. Brenowitz JB, Kayser KL, Johnson WD. Results of coronary artery endarterectomy and reconstruction. *J Thorac Cardiovasc Surg*. 1988; 95:1-10.
30. Christakis GT, Rao V, Fremes SE, Chen E, Naylor D, Goldman BS. Does coronary endarterectomy adversely affect the result of bypass surgery? *J Card Surg*. 1993; 8:72–78.
31. Walley VM, Byard RW, Keon WJ. A study of the sequential morphologic changes after manual coronary endarterectomy. *J Thorac Cardiovasc Surg* 1991; 102: 890–894.
32. Erdil N, Cetin L, Kucuker S, Demirkilic U, Sener E, Tatar H. Closed endarterectomy for diffuse right coronary artery disease: early results with angiographic controls. *J Card Surg* 2002; 17:261–266.
33. Marzban M, Karimi A, Ahmadi H, Davoodi S, Abbasi K, Movahedi N, et al. Early outcomes of double vessel coronary endarterectomy in comparison with single-vessel coronary endarterectomy. *Tex Heart Inst J* 2008; 35: 119–124.