

**Original Article**

# Adult Congenital Heart Disease and Percutaneous Interventions : Analysis of Cases over five years in a Bangladeshi Center

Nurun Nahar Fatema

Combined Military hospital, Dhaka; Lab Aid Cardiac Hospital, Dhaka

**Abstract :**

**Key Words :**  
Adult Congenital Heart Disease, Device closure.

**Background:** In recent year 's considerable progress has been made in the early diagnosis and treatment of congenital heart disease (CHD) and a significant number of children are expected to survive into adulthood after completion of treatment. This has created a scope of a substantial population of patients with adult congenital heart disease. In Bangladesh, milder or simple form of congenital heart diseases are prevalent among populations but palliated and treated cases of CHD are gradually increasing the load of work for adult congenital heart disease (ACHD) professionals. Many of these cases can be treated by transcatheter intervention with excellent outcome.

**Methods:** This is a retrospective study conducted in a tertiary level cardiac hospitals of Bangladesh from January 2015 to December 2020. All cases aging 18 years and above were included who had undergone cardiac catheterization or percutaneous interventions. Data were collected from Echocardiography department, Catheterization Laboratory and indoor department. Follow up data were collected from echocardiography and outpatient department.

**Results:** Total Two hundred Ninety-four cases were enrolled for cardiac catheterization. Two hundred eighteen cases had various types of intervention. Most of the cases were in 18-25 years age group. Among shunt lesions, 165 cases (56.12%) had atrial septal defect (ASD), 48(22.02%) had ventricular septal defect (VSD), 32 (14.67%) had patent ductus arteriosus (PDA), and 4(1.83%) had patent foramen ovale (PFO). Device closure was performed in 120(55.04%) cases of ASD, 13(5.96%) cases of VSD, 30 (13.76%) cases of PDA and in 4(1.83%) cases of PFO. Nineteen (8.72%) had valvuloplasty for pulmonary stenosis (PS), 2 (0.68%) had valvuloplasty for aortic stenosis (AS), 2(0.068%) had coarctoplasty for coarctation of the aorta (CoA), 4 (1.83%) had percutaneous pulmonary valve implantation (PPVI). Seventeen (7.79%) cases had double intervention of ASD device closure and pulmonary stenosis, 5 (2,29%) cases had ASD and PDA device closure and 2 (0.92%) cases had PDA device closure and balloon coarctoplasty. ASD device was embolized in 4 cases. There were no other complications.

**Conclusion:** Outcome of intervention in ACHD was found safe and effective and no significant short or long-term complications were noticed.

(*Cardiovasc j 2022; 14(2): 121-127*)

**Introduction:**

Improved medical and surgical treatment of children suffering from simple and complex congenital heart disease have resulted in an increasing number of patients reaching adulthood.<sup>1-3</sup> In recent years, interventional cardiology of adult congenital heart disease (ACHD)

has become a well-established specialization with separate programs and identities in many centers.<sup>3,4</sup> Wide variation in presentation, association with other diseases, the difference of pathogenesis or some similarity with congenital and acquired heart diseases in children, association with multi-organ pathology, complications from

**Address of Correspondence:** Prof. Nurun Nahar Fatema, Lab Aid Cardiac Hospital, Dhaka, Bangladesh. E mail: colfatema@hotmail.com

© 2022 authors; licensed and published by International Society of Cardiovascular Ultrasound, Bangladesh Chapter and Bangladesh Society of Geriatric Cardiology. This is an Open Access article distributed under the terms of the CC BY NC 4.0 (<https://creativecommons.org/licenses/by-nc/4.0>)

untreated and treated diseases, issues of lifestyle, job, social activities contributes to situations atypical for standard adult or pediatric programs. Transcatheter interventions for congenital heart disease (CHD) have dramatically evolved in the last few decades to provide complete cure for diseases like ASD, VSD, PDA and some valvular diseases under ACHD program.<sup>5</sup>

Follow up of these cases and the shift of follow-up of children from the pediatric cardiologist to adult cardiologist once they enter to adult age pose problem both to patient and physicians as adult cardiologist are not trained in CHD and its consequence. So, follow-up of the treated and untreated case under a separate specialty is mandatory.

Many patients with these diseases remain untreated and incidentally diagnosed in adulthood when been treated other diseases. In this retrospective analysis, all such adult congenital heart disease cases who had undergone cardiac catheterization were analyzed in two cardiac hospitals of Bangladesh where ACHD program is available under supervision of pediatric cardiologist.

## Methods

This is a retrospective study carried out in pediatric cardiology department of a tertiary level cardiac hospital (who take care of ACHD cases) from Jan 2015 to December 2020. Out of 294 cases of ACHD cases undergone cardiac catheterization, 218 cases had various types of percutaneous interventions. Selection criteria for various interventions were followed specifically. Thorough analysis of cases was done by echocardiography on the day before the procedure. Steps of the intervention and size of implants were determined and hard ware supply ensured. All patients had precatheterization evaluation thoroughly. Those having other comorbidities like diabetes or hypertension, renal failure, arrhythmia, were referred to respective specialists for any special precaution or advice. Adult cardiologists were involved if a coronary angiogram was required specially in cases over 50 years. Nonionic (Visipaque / iodixanol) contrast agent was used for patient with renal impairment. For diabetic cases, hypoglycemic agents were avoided while they were fasting and blood sugar was monitored frequently. All patients were

discharged after 24 hours from post catheterization ward or coronary care unit (CCU). Echocardiography of all intervention cases were performed before discharge. Follow-up plan and antiplatelet drugs or anticoagulants were advised according to institutional protocol. Only two cases of ventricular septal rupture (VSR) following myocardial infarction were returned back to ICU in ventilator and one of them died from renal shutdown after seven days.

Only the secundum type of ASD with adequate rims were accepted for ASD device closure. Balloon sizing was performed in Cath Lab and inflation of balloon continued until stop flow was achieved.

For VSD device closure, perimembranous, subaortic and muscular types were accepted. Two post myocardial infarction ventricular septal rupture (VSR) in muscular septum were accepted for device closure. All PDA cases were accepted for device closure but two of them were postponed for Eisenmenger change. Valvular stenosis and coarctation cases were accepted as per standard guidelines of peak pressure gradient across stenosed area and ventricular dysfunction if any. Percutaneous pulmonary valve implantation (PPVI) cases were also accepted as per international protocol.

## Devices and implants used:

ASD: Cera ASD occluder (Lifetech Scientific, Schenzen), Amplatzer septal occlude (St Jude Medical, MN, USA), Cookon septal occluder (Vascular innovation company Ltd. Nonthaburi, Thailand), Figulla flex (Occlutech, Switzerland).

VSD: Amplatzer duct occluder II (ADO II Abbott vascular solution, USA), MF Konar (Lifetech Scientific, Schenzen), Cook detachable coil (Cook Medical, USA), Amplatzer Pm and muscular Devices (St Jude, M N, USA), Amplatzer duct occluder I (St Jude, MN, USA)

PDA: Amplatzer duct occlude (ADO, St Jude, MN, USA) MF Konar (Lifetech Scientific, Schenzen), Cook detachable coil (Cook Medical, USA) Amplatzer muscular Devices (St Jude, M N, USA), arterio venous plug (AVP) for coronary fistula.

Valvuloplasty: Tyshak balloons of various types, Z- Med Balloons, Atlas high pressure balloons, Blue maxhigh pressure balloons, Optiplast balloon, BIB balloons for stent dilatation.

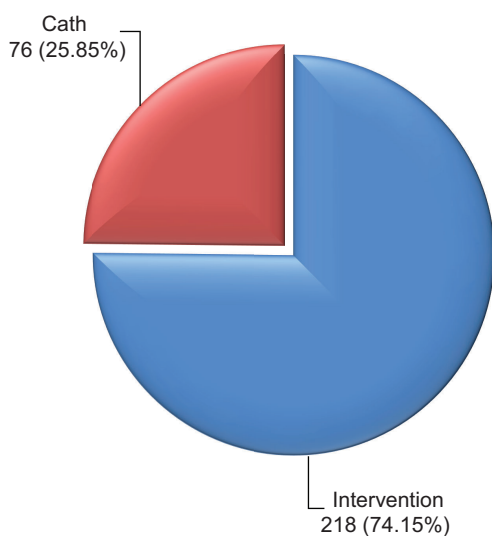
Stents: Cheatham Platinum (CP)- NuMed (New York, USA), Andra<sup>R</sup> stent XL/XXL (Andramed, Germany), Advanta V12(Sweden)

Pulmonary Valve: Melody<sup>TM</sup> with ensemble delivery system (18-22), Medtronic, USA.

Informed consent was taken from every patient as per Helsinki's declaration and permission of the ethical committee was taken from concerned hospital. Details were collected from the computerized database of the pediatric catheterization and echocardiography laboratory and were analyzed in MS Excel. Statistical analysis: Numerical & categorical data were expressed in numbers and frequencies, Because of single variant data, comparative tests were not done.

**Results:**

Total two hundred and eighteen cases were accepted for percutaneous intervention and seventy-six cases were accepted for diagnostic cardiac catheterization (Fig-1)



**Fig 1:** Distribution of cases.

Most of the patients were in the 18- 25 years age group least in more than 55 years age group male and female ratio was 1:2.18 (Table I)

Total 165 (100%) cases had Atrial Septal Defects (ASD), out of which 124 (75.15%) had device closure and 13 (7.87%) had trial of device closure but postponed for deficient rims. Four (2.42%) device was embolized after implantation and was referred to cardiac surgery department. Total 48 (100%) cases had Ventricular Septal Defects (VSD) out of which 17 (35.41%) had device trial and 13 (27.08%) were successful. Total 32 (100%) cases were accepted for PDA device closure but two (6.25%) postponed for Eisenmenger change (Fig II).

ASD device closure was the commonest intervention (55.04%) followed by PDA device closure (13.76%), balloon valvuloplasty for PS (8.72%), VSD device closure (5.96%), coarctation stenting (2.75%), percutaneous pulmonary valve implantation (1.83%) etc. (Table II)

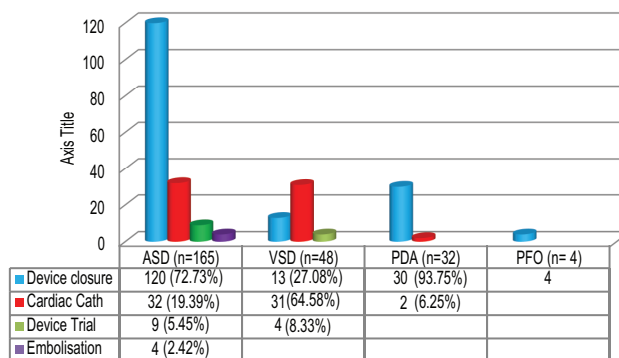
Table III showed the distribution of cases of cardiac catheterization. Thirty-two (42.10%) cases of ASD had diagnostic catheterization to check operability. Thirty-one (40.78%) cases of VSD and 2 (2.63%) cases of PDA had similar testing to check operability. TOF cases (6.57%) had catheterization to check right ventricular contractility, additional VSD's, coronary anomalies, major aortopulmonary collaterals (MAPCA), etc.

Table IV showed double intervention cases. Seventeen cases (7.8%) had ASD device closure and pulmonary valvuloplasty, 5 (2.29%) cases had ASD and PDA device closure and 2 (0.92%) cases had PDA device closure and balloon coarctoplasty.

Table V showed outcome of the cases. Out of 124 cases of ASD, 96.77% had successful closure. Air embolism was encountered in 6(4.84%) cases and

**Table- I**  
Age & sex distribution of patients (n=294).

Age in years	Total (%)	Sex		Male to Female ratio
		Male (%)	Female (%)	
18-25	175 (59.52)	55 (18.70)	120 (40.81)	1:2.18
25-35	64 (21.76)	14 (4.76)	50 (17.00)	1:3.57
35-45	30 (10.20)	12 (4.08)	18 (6.12)	1:1.5
45-55	16 (5.44)	7 (2.38)	9 (3.06)	1:1.28
>55	9 (3.06)	3 (1.02)	6 (2.04)	1:2
<b>Total</b>	<b>294 (100)</b>	<b>91(30.96)</b>	<b>203 (69.04)</b>	<b>1:2.23</b>



**Fig.-2: Distribution of shunt lesions**

**Table-II**

*Types of lesions accepted for various types of intervention (N=218).*

Types of Lesion & Procedure		Number / Percentage (%)	Postponed after trial/ embolization	Performed successfully(%)
Atrial Septal Defect (ASD)	Device closure	133 (61.00)	9 /4	120 (55.04)
Patent Foramen Ovale (PFO)	Device closure	4 (1.83)	Nil	4 (1.83)
Ventricular Septal Defect (VSD)	Device closure	17 (7.79)	4 / 0	13 (5.96)
Patent Ductus Arteriosus (PDA)	Device closure & coil occlusion	30 (13.76)	0/0	30 (13.76)
Pulmonary Stenosis (PS)	Balloon pulmonary valvuloplasty	19 (8.72)	Nil	19 (8.72)
PA, VSD S/P Repair with Conduit s/p BT shunt	Percutaneous Pulmonary Valve Implantation (PPVI)	4 (1.83)	Nil	4 (1.83)
Aortic Stenosis (AS)	Balloon aortic valvuloplasty	2 (0.09)	Nil	2 (0.09)
Coarctation of Aorta	Balloon coarctoplasty	2 (0.09)	Nil	2 (0.09)
Coronary Cameral Fistula	Device closure (AVP)	1 (0.45)	Nil	1 (0.45)
Coarctation of Aorta	Endovascular stenting	6 (2.75)	Nil	6 (2.75)

**Table-III**

*Types of CHD who had diagnostic cardiac Catheterization (n=76).*

Types of Lesions	Number	Percentage
Atrial Septal Defect (ASD)	32	42.10%
Ventricular Septal Defect (VSD)	31	40.78%
Patent Ductus Arteriosus (PDA)	2	2.63%
Tetralogy of Fallot (TOF)	5	6.57%
CTGA	2	2.63%
Ebstein Anomaly	2	2.63%
PA VSD MAPCA	2	2.63%

**Table-IV**

*Double Intervention in single setting (n=218).*

Disease	Intervention	No (%)
Atrial septal defect and Pulmonary stenosis	Device closure + Balloon valvuloplasty	17 (7.80)
Atrial septal defect and Patent ductus arteriosus	Device closure of both	5 (2.29)
Patent ductus arteriosus + Coarctation of aorta	Device closure + coarctoplasty	2 (0.92)

**Table-V**  
*Outcome of Intervention (N=218).*

Disease end result	Successful of implant	Embolisation defect	Residual embolism	Air	Arrhythmia	Death	Haemolysis	Late complication
ASD device closure	120 (55.04%)	4	Nil	6	4	Nil	Nil	Nil
PFO device closure	4 (1.83%)	0	Nil	Nil	Nil	Nil	Nil	Nil
VSD device closure	13 (5.96%)	0	Nil	Nil	1	Nil	Nil	Nil
PDA device closure	30 (13.76%)	0	Nil	Nil	Nil	Nil	Nil	Nil
Balloon pulmonary valvuloplasty	14 (6.42%)	0	3	Nil	Nil	Nil	Nil	Nil
PPVI	4 (1.83%)	0	Nil	Nil	Nil	Nil	Nil	Nil
Balloon aortic valvuloplasty	2 (0.91%)	0	1	Nil	Nil	Nil	Nil	Nil
Balloon coarctoplasty	2 (0.91%)	0	Nil	Nil	Nil	Nil	Nil	Nil
Coronary cameral fistula	1 (0.45%)	0	Nil	Nil	Nil	Nil	Nil	Nil
Endovascular stenting	6	1 (managed successfully)	Nil	Nil	Nil	Nil	Nil	Nil

Abbreviation: ASD: Atrial Septal Defect, VSD: Ventricular septal defect, PDA: Patent ductus arteriosus, TOF: Tetralogy of Fallot, PS: Pulmonary Stenosis, CoA: Coarctation of aorta, AS: Aortic Stenosis, PFO: Patent foramen ovale, PPVI: Percutaneous Pulmonary Valve Implantation, BAV: Balloon aortic valvuloplasty

the device was embolized in 4(3.22%) cases. In other interventions, no embolization or side effects were noticed. In one case of coarctation stenting, the stent was displaced but later repositioned immediately. One post myocardial infarction VSR case died from renal failure after seven days of procedure.

### Discussion:

The population of adults with congenital heart disease is expanding rapidly with improved medical and surgical therapies for children.<sup>6-8</sup> At the same time, the field of interventional cardiology has experienced tremendous growth from innovations of new technologies, devices, inclusion of indications for much more diseases as well as an excellent short and intermediate term outcome seen in many studies.<sup>9</sup> In the United States (USA), currently more patients with congenital heart diseases are over the age 20 years than under that age. The population of adult CHD is growing at a rate of 5% per year with 1 to 1.3 million people with CHD entering in adult age.<sup>10</sup>

In Bangladesh, ACHD load is increasing and the detection rate of ACHD has also been increased because of the easy availability of echocardiography facilities in peripheral hospitals and remote areas. Many patients are detected during health checks up for entrance examination in military forces, medical colleges, and many detected during pre-anesthesia check-up for other surgeries. Significant number of female patients are detected during antenatal check-up for unusual dyspnea.

In this study, simple form of heart diseases was predominant then complex diseases, so number of complex cases undergone cardiac catheterization were much less than intervention for shunt lesions and valvular or vessel stenosis. Scenario is different in studies of developed countries where complex cases are more.<sup>6</sup> The age of most of the cases is in the range of 18-25 years which correlates with other study.<sup>11,12</sup> The commonest defect seen in adults are ASD, AS, Coarctation, PS, Ebstein anomaly, TOF, Corrected transposition of great arteries (C-TGA), Pulmonary atresia (PA VSD, MAPCA) Double outlet right ventricle (DORV) ASD primum, single ventricle (SV), and post-operative cases like Fontan, Bidirectional Glenn shunt, Senning, Rastelli, arterial switch etc.<sup>13</sup>

Common lesions amenable to percutaneous interventions are ASD, VSD, PDA, AS, PS, CoA, etc. Valvular & structural interventions are also possible like percutaneous pulmonary valve implantation (PPVI), Patent foramen ovale closure (PFO) closure, Transcatheter aortic valve implantation (TAVI), Left atrial appendage (LAA) closure etc. In TOF cases some interventions are possible for LV, RV dysfunction. One study published in 2020 showed ASD device closure as the most frequently performed procedure Bangladesh.<sup>11</sup>

The procedure of interventions e.g., device closure and balloon valvuloplasty was the same as like pediatric age group.<sup>14-17</sup> ASD, VSD, PDA device closure, and balloon valvuloplasty for aortic and



pulmonary valve and balloon angioplasty for coarctation of aorta were performed after proper preoperative evaluation. In some cases, coronary angiography was performed if age is 50 years or more or coronary involvement is suspected. In PDA cases adults had difficulty in entering the aorta because of twisting of PDA. Some of the cases were performed by snare assisted technique where Terumo wire was snared and pulled to aorta from pulmonary artery and then exchanged later with delivery system. Transthoracic echo guide was taken along with fluoroscopy guide for all cases. In two cases Transoesophageal echo guide was taken for the poor window.<sup>14</sup>

PPVI is performed routinely in Bangladesh but because of expensive hardware number is limited.<sup>18</sup> In this cohort, PPVI was performed in four post-operative cases of pulmonary atresia VSD who had BT shunt in infancy followed by total repair with RV to PA conduit. All patient developed conduit dysfunction and Melody valve and ensemble of 20mm was implanted successfully. PFO device closure was performed in 4 cases who reported with migraine and aura or with history of stroke. Coarctation stenting was performed in 6 cases. Two of them had Turner's syndrome. As weight was more than 15 kg in all cases, Advanta V<sub>12</sub>, CP stents were used for them with various lengths. Some of the cases had double lesion amenable to intervention (Table IV) and both lesions were treated successfully. Outcome of the interventions are similar to studies conducted in children and in ACHD cases.<sup>11-20</sup>

There was no mortality related to intervention. One patient of device closure of VSR died from renal failure after 7 days. Air embolism, arrhythmia was managed immediately. In one case of coarctation stenting, stent was displaced above the lesion during dilatation, later it was repositioned. No complications were observed in follow up period.

### Conclusion:

Adult congenital heart disease services should be delivered properly through separate care system. It is important to understand the congenital heart disease in adulthood along with consideration to all other comorbidities like coronary artery diseases, heart failure etc. In developing country like us ACHD falls through the crack of medical

system and are under diagnosed. But it is important to believe that almost all forms of ACHD can be treated by intervention or surgery. Results of interventions are excellent and ACHD population can live a normal life under care of follow up service through ACHD clinic.

---

### Conflict of Interest - None.

---

### References:

1. Warnes C, Liberthson R, Danielson G et al. Task Force 1: the changing profile of congenital heart disease in adult life. *J Am Coll Cardiol.* 2001; 37(5): 1170-1175. doi:10.1016/s0735-1097(01)01272-4
2. Mackie AS, Pilote L, Ionescu-Ittu R, Rahme E, Marelli AJ. Health care resource utilization in adults with congenital heart disease. *Am J Cardiol.* 2007;99(6):839-843. doi:10.1016/j.amjcard.2006.10.054
3. Inglessis I, Landzberg M. Interventional Catheterization in Adult Congenital Heart Disease. *Circulation.* 2007;115(12):1622-1633. doi:10.1161/circulationaha.105.592428
4. Garekar S, Paules M, Reddy S et al. Is it safe to perform cardiac catheterizations on adults with congenital heart disease in a pediatric catheterization laboratory?. *Catheterization and Cardiovascular Interventions.* 2005; 66(3):414-419. doi:10.1002/ccd.20537
5. Fraisse A, Chessa M. Catheter interventions for Adult Congenital Heart Disease. *Eur Heart J.* 2019;40(3):231-233. doi:10.1093/eurheartj/ehy829
6. Verheugt C, Uiterwaal C, van der Velde E et al. Mortality in adult congenital heart disease. *Eur Heart J.* 2010;31(10):1220-1229. doi:10.1093/eurheartj/ehq032
7. Warnes C, Liberthson R, Danielson G et al. Task Force 1: the changing profile of congenital heart disease in adult life. *J Am Coll Cardiol.* 2001;37(5):1170-1175. doi:10.1016/s0735-1097(01)01272-4
8. Mackie AS, Pilote L, Ionescu-Ittu R, Rahme E, Marelli AJ. Health care resource utilization in adults with congenital heart disease. *Am J Cardiol.* 2007;99(6):839-843. doi:10.1016/j.amjcard.2006.10.054
9. Landzberg M, Murphy D, Davidson W et al. Task Force 4: organization of delivery systems for adults with congenital heart disease. *J Am Coll Cardiol.* 2001;37(5):1187-1193. doi:10.1016/s0735-1097(01)01275-x
10. Moodie D. Adult congenital heart disease: past, present, and future. *Tex Heart Inst J.* 2011;38(6):705-706.
11. Fatema N. Pattern of Congenital Heart Diseases and Treatment Options in a Bangladeshi Centre: Analysis of 6914 cases from Non-invasive Cardiac

- Laboratory. *Cardiovascular Journal*. 2017;9(2):97-105. doi:10.3329/cardio.v9i2.32420
12. Fatema N. Short, Intermediate and Long Term Follow up of Device Closure of Atrial Septal Defect (Secundum) Cases: Thirteen Years Experience with Special Reference to Complications. *Cardiovascular Journal*. 2015;7(2):85-92. doi:10.3329/cardio.v7i2.22248
  13. Moodie DS. Adult congenital heart disease. *Ochsner J*. 2002;4(4):221-226.
  14. Fatema N. A Minimalistic Approach of Device Closure of Atrial Septal Defect: Analysis of Cases Over Five Years. *American Journal of Multidisciplinary Research & Development (AJMRD)* August 2020;2(8):1-10.
  15. Fatema N. Transcatheter closure of ventricular septal defect from retrograde transarterial approach: immediate and long-term outcome. *Int J Contemp Pediatrics*. 2020;7(9):1830. doi:10.18203/2349-3291.ijcp20203639
  16. Fatema N, Razzaque A. Device closure of patent ductus arteriosus: analysis of cases in a Bangladeshi centre. *Int J Contemp Pediatrics*. 2020;7(7):1481. doi:10.18203/2349-3291.ijcp20202573
  17. Inglessis I, Landzberg M. Interventional Catheterization in Adult Congenital Heart Disease. *Circulation*. 2007;115(12):1622-1633. doi:10.1161/circulationaha.105.592428
  18. Nurun Nahar F, Mansur Al J, Stephan S, Mir Mahmud H. Percutaneous Pulmonary Valve Implantation in a Bangladeshi Center: A Case Series. *ASEAN Heart Journal*. 2020;28(1):1-6. doi:10.31762/ahj2028.0101
  19. NN Fatema (2021). Fatema's Basic Pediatric Cardiology (2<sup>nd</sup> Edition). Mashiyat Mayisha Ahemed published by Asian Colour Printing. ISBN:978-98434-2938-4.
  20. NN Fatema (2021) Congenital And Structural Heart Diseases and interventions: Research work in Bangladesh. (3<sup>rd</sup> Edition). Marzia Tabassum Published by Beximco Pharmaceuticals Ltd. ISBN:978-984-3334312-3