

## Case Report

# Bilateral Pulmonary Thromboendarterectomy for a Patient with Chronic Pulmonary Thromboembolism Developing Severe Pulmonary Hypertension – A Case Report

Prodip K Biswas<sup>1</sup>, Gafur M A<sup>1</sup>, Rahman H<sup>1</sup>, Saikat Dasgupta<sup>2</sup>, Prasanta K Chanda<sup>2</sup>

<sup>1</sup>Department of Cardiac Surgery, National Heart Foundation Hospital & Research Institute, Dhaka,

<sup>2</sup>Department of Cardiac Surgery, Square Hospitals Limited, Dhaka.

### Abstract:

*Chronic thromboembolic pulmonary hypertension (CTEPH) is a disease with high mortality and few treatment options. Pulmonary thromboendarterectomy (PTE) is the treatment of choice to relieve pulmonary artery obstruction in patients with chronic thromboembolic pulmonary hypertension (CTEPH). This is a challenging procedure in our perspective because of number of regions such as, late diagnosis, scarcity of appropriate instruments, lack of skilled surgeon as it is not familiar to them. Here we are presenting such a case that was also diagnosed incidentally. We successfully operated the patient with chronic pulmonary thromboembolism with severe pulmonary hypertension.*

### Key Words :

*Pulmonary embolism, Pulmonary hypertension, Endarterectomy.*

*(Cardiovasc j 2022; 14(2): 176-179)*

### Introduction:

Chronic thromboembolic pulmonary hypertension (CTEPH) is defined as a persistent mean pulmonary arterial pressure greater than 25 mmHg for 6 months after the acute pulmonary embolic event.<sup>1,2</sup> At 2-yr follow-up, 3.8% of survivors of an acute pulmonary embolic event develop CTEPH.<sup>3</sup> CTEPH is a precapillary condition associated with an occlusive thrombus or emboli after 3 months of therapeutic anticoagulation and a mean pulmonary artery pressure >25 mmHg.<sup>4</sup> The ideal treatment for CTEPH is surgery, with the first-line operation being the potentially curative pulmonary thrombectomy and bilateral endarterectomy (PTE). Approximately two-thirds of patients with CTEPH have disease amenable to an operation, and 2-year survival rates are approximately 10% higher in patients who undergo an operation compared to those who do not.<sup>5</sup> After successful PTE, the resolution of right heart dysfunction and pulmonary hypertension (PH) is often rapid.

Remodeling is usually complete by 3 months, and these results are most often permanent.<sup>6</sup> Pulmonary thromboendarterectomy has the advantage of a lower mortality rate than lung transplant and does not preclude transplant if the patient experiences persistent pulmonary hypertension that does not improve with medication.<sup>7</sup> Pre-operative risk stratification is important in patients with CTEPH. A patient must have sufficient surgically accessible thromboembolic material, with a proportional pulmonary vascular resistance (PVR) indicating the absence of extensive distal disease.<sup>8</sup> Thromboembolic disease located proximally in the main, lobar or segmental arteries can be removed relatively easily by pulmonary endarterectomy, while distal disease confined to sub segmental vessels is more difficult to clear and may therefore render the patient inoperable.<sup>9</sup> The final decision regarding operability is based on the risk/benefit ratio for the patient and is ultimately determined

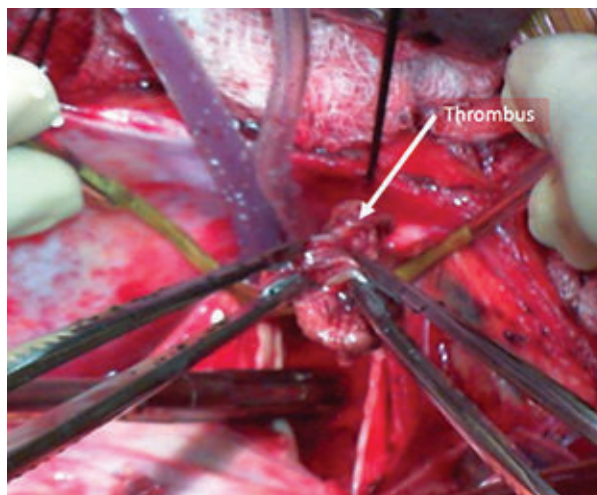
**Address of Correspondence:** Dr. Prodip K Biswas, Department of Cardiac Surgery, National Heart Foundation Hospital & Research Institute, Dhaka, Bangladesh. Email-pkbiswas81@gmail.com

© 2022 authors; licensed and published by International Society of Cardiovascular Ultrasound, Bangladesh Chapter and Bangladesh Society of Geriatric Cardiology. This is an Open Access article distributed under the terms of the CC BY NC 4.0 (<https://creativecommons.org/licenses/by-nc/4.0>)

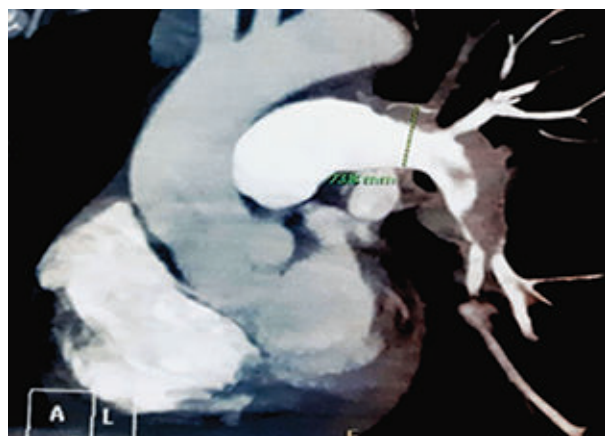
by the surgeon's experience. Pulmonary angiography is currently regarded as the gold-standard imaging technique in evaluating the location and extent of disease, and thus suitability of the patient for pulmonary endarterectomy.

**Case Report:**

A 55-year-old gentleman came to our hospital with shortness of breath (NYHA III), occasional chest pain with a history of bone fracture 6 months back following an road traffic accident. He was smoker, normotensive, non-diabetic, no history of COPD, major surgery, malignancy, PTB and blood transfusion. On examination he was anxious, cooperative with average body built and nutrition. He was tachypneic, non-cyanosed non icteric, non-edematous. His pulse, blood pressure was within normal limit. His CXR showed cardiomegaly, linear opacities on peripheral lung fields, ECG showed sinus tachycardia with nonspecific ST changes, trans thoracic echocardiography revealed dilated RV with moderate to severe RV systolic

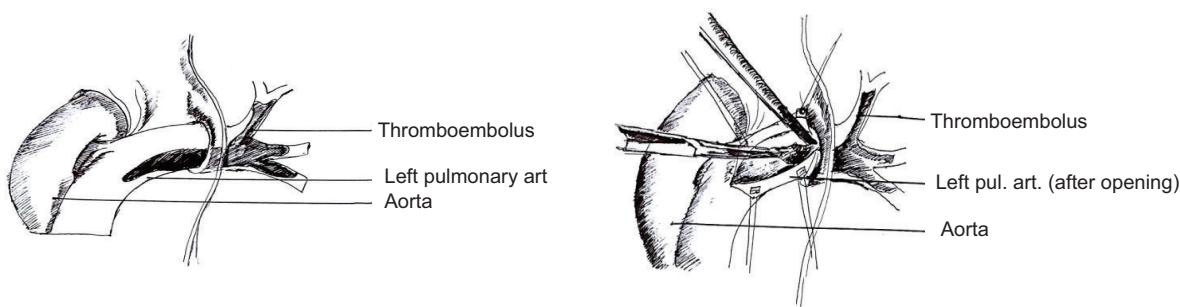


**Fig.-2:** Removing thrombus from pulmonary artery.



**Fig.-1:** Thrombus in left pulmonary artery.

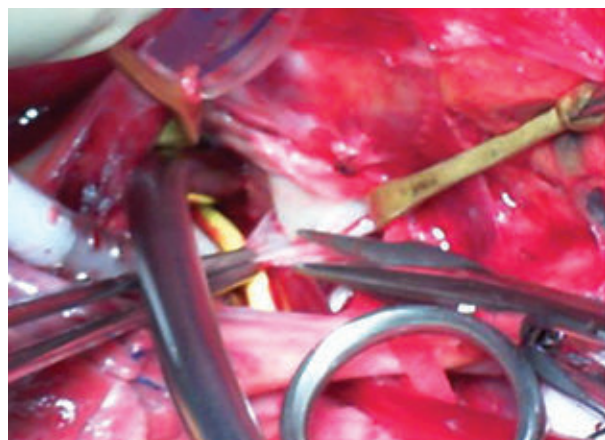
dysfunction, mildly dilated RA, trace TR (PASP=45 mm of Hg). Pulmonary CT angiogram revealed both the branched pulmonary arteries were well visualized & showing almost complete occlusion of the lumen by thrombus with irregular outlines. Both the right & left ascending pulmonary arteries showed complete occlusion by thrombus. Cardiac catheterization with selective coronary angiography showed –severe pulmonary artery hypertension, non-critical coronary artery disease. When diagnosis was confirmed, we prepared the patient for surgery. Meanwhile we decorated our plan of surgery, inform the anesthetic, perfusion team what we were going to do and how they might help to achieve a successful operation. After proper counseling, informed consent was taken. On the day of operation general anesthesia was given, patient was positioned supine, two temperature probes one in the nasopharynx and another one in



**Fig.-4:** Approaching thromboendarterectomy.

the rectum placed, cooling blanket, ice pack, TEE, NIRS made available. Median sternotomy was done. After thymus dissection pericardiotomy done and a piece of pericardium taken. Anticoagulation is achieved with the use of heparin sodium (400U/kg, IV). High up aortic and standard bicaval cannulation done. Cardio pulmonary bypass started. Cooling was started (target temperature was 20<sup>0</sup>c) with the help of cooling blanket on the operating table, room temperature was also lowered. During cooling, a 10°C temperature difference between arterial blood and rectal temperature was maintained. Full mobilization of right pulmonary artery (RPA) from ascending aorta was done. Right pulmonary artery up to right lobar bronchus dissected free, left pulmonary artery was also dissected free. All dissections of pulmonary arteries were done intra pericardially.

When the heart started fibrillating, we applied aortic cross clamp and nonselective antegrade cold cardioplegia (delNido) was given. Superior vena cava & inferior vena cava were snugged, right atrium was opened and heart was vented via right superior pulmonary vein. Right atrium, right ventricle inspected for any thrombus. No thrombus or any abnormality was found. Right atrium was closed in layers. When target temperature achieved, we went to total circulatory arrest (TCA). Right pulmonary artery was opened with an incision extending beneath the ascending aorta to



**Fig.-5:** *Endarterectomy from left pulmonary artery.*

lower lobe branch just after the takeoff of the middle lobe artery. Loose thrombus was removed followed by endarterectomy; the procedure took 3 cycles each cycle comprises 10 minutes of total circulatory arrest (TCA) followed by 15 minutes of perfusion. Following endarterectomy right pulmonary artery was augmented with pericardium. Subsequently, left pulmonary artery was opened and left sided thrombo endarterectomy was done taking 2 cycles. Left pulmonary artery augmentation done with pericardium. Rewarming started. After deairing Aortic cross clamp released. NSR appeared, weaned from cardio pulmonary bypass with milrinone. Protamine taken and hemostasis secured. Chest closed in layers leaving 2 mediastinal and right pleural drains in situ. Patient shifted to ICU with stable hemodynamics. He was extubated on 1st POD and discharged from hospital on 7<sup>th</sup> POD.

He is doing well in his last follow up after two years. Discussion: Although successful operations for CTEPH have been performed for more than 50 years, the mainstay of treatment for this disease remains medical, with surgical therapy concentrated in a few high-volume centers. An unknown number of undiagnosed patients and patients who are not referred to a surgeon might have curable disease. Before PTE was developed, the 2-year mortality with CTEPH is >80% when the patient's mean pulmonary artery pressure was >50 mm Hg.<sup>7</sup> The PTE procedure is well described and replicable, although most studies demonstrate a learning curve for the procedure.<sup>7</sup> Overall, 4-year mortality rates after surgery appear to be approximately 15%.<sup>10</sup> Screening is important for patients with pulmonary hypertension because symptoms are often vague and may not manifest for many years. In high-risk populations, such as patients with acute pulmonary embolism who have evidence of right ventricle dysfunction or continue to have significant dyspnea, a repeat echocardiogram at 3-6 months is recommended.<sup>4,11</sup> Risk factors for developing CTEPH include multiple episodes of pulmonary embolism, thyroid replacement therapy, a history of a splenectomy or malignancy, a ventriculoatrial shunt, a prothrombotic state, and a previous venous thromboembolism.<sup>11</sup> After surgery, the changes seen on echocardiogram are the resolution of tricuspid regurgitation, a decrease in size of the right ventricle and right atrium, and normalization



of the E/A ratio. Some studies report additional decreases in mean pulmonary artery pressure by the 12-month mark but no additional improvements beyond 2 years from surgery.<sup>12</sup> CTEPH is the only form of pulmonary hypertension for which there is a surgical operation other than lung transplantation. With best medical treatment the five year survival for patients with a mean pulmonary artery pressure of >50 mm Hg complicating pulmonary embolism is only 10%.<sup>12</sup> Across different studies at large-volume centers, approximately 35% of patients have residual pulmonary hypertension after pulmonary thromboendarterectomy, although the residual pulmonary hypertension does not appear to significantly impact their 5-year survival, especially with adjuvant disease-modifying medications.<sup>11</sup> At the University of California, San Diego Medical Centre (UCSD) the unit with the largest experience of this procedure—the operative mortality for pulmonary thromboendarterectomy is around 7% which compares favourably with lung transplantation. Operative mortality is usually related to an incorrect diagnosis of CTEPH, an incomplete endarterectomy having been performed, or the occurrence of fulminant reperfusion pulmonary oedema.

### Conclusion:

It is clear that chronic thromboembolic disease has a significant incidence and yet the diagnosis is made infrequently. Pulmonary thromboendarterectomy offers a potential surgical cure for CTEPH and is the surgical procedure of choice for patients with this condition. The full benefit of surgery will only be realized as early diagnosis and intervention become more commonplace. Early recognition of this group of patients is pivotal in improving the outcome from CTEPH.

---

### Conflict of Interest - None.

---

### References:

1. Piazza G, Goldhaber S. Chronic Thromboembolic Pulmonary Hypertension. *New England Journal of*

*Medicine*. 2011;364(4):351-360. doi:10.1056/nejmra0910203

2. Pengo V, Lensing A, Prins M et al. Incidence of Chronic Thromboembolic Pulmonary Hypertension after Pulmonary Embolism. *New England Journal of Medicine*. 2004;350(22):2257-2264. doi:10.1056/nejmoa032274
3. Wilkens H, Lang I, Behr J et al. Chronic thromboembolic pulmonary hypertension (CTEPH): Updated Recommendations of the Cologne Consensus Conference 2011. *Int J Cardiol*. 2011;154:S54-S60. doi:10.1016/s0167-5273(11)70493-4
4. Fares W, Heresi G. Chronic Thromboembolic Pulmonary Hypertension: A Worldwide View of How Far We Have Come. *Lung*. 2016;194(3):483-485. doi:10.1007/s00408-016-9863-6
5. Jamieson S, Kapelanski D, Sakakibara N et al. Pulmonary endarterectomy: experience and lessons learned in 1,500 cases. *Ann Thorac Surg*. 2003;76(5):1457-1464. doi:10.1016/s0003-4975(03)00828-2
6. Pepke-Zaba J, Delcroix M, Lang I et al. Chronic Thromboembolic Pulmonary Hypertension (CTEPH). *Circulation*. 2011;124(18):1973-1981. doi:10.1161/circulationaha.110.015008
7. Kim N, Delcroix M, Jenkins D et al. Chronic Thromboembolic Pulmonary Hypertension. *J Am Coll Cardiol*. 2013;62(25):D92-D99. doi:10.1016/j.jacc.2013.10.024
8. Corsico A, D'Armini A, Cerveri I et al. Long-term Outcome after Pulmonary Endarterectomy. *Am J Respir Crit Care Med*. 2008; 178(4): 419-424. doi:10.1164/rccm.200801-101oc
9. Marshall P, Kerr K, Auger W. Chronic Thromboembolic Pulmonary Hypertension. *Clin Chest Med*. 2013;34(4):779-797. doi:10.1016/j.ccm.2013.08.012
10. D'Armini A, Cattadori B, Monterosso C et al. Pulmonary thromboendarterectomy in patients with chronic thromboembolic pulmonary hypertension: hemodynamic characteristics and changes). *European Journal of Cardio-Thoracic Surgery*. 2000; 18(6): 696-702. doi:10.1016/s1010-7940(00)00584-4
11. Riedel M, Stanek V, Widimsky J, Prerovsky I. Longterm Follow-up of Patients with Pulmonary Thromboembolism. *Chest*. 1982; 81(2): 151-158. doi:10.1378/chest.81.2.151