

## Case Report

# Alcohol Septal Ablation for Hypertrophic Obstructive Cardiomyopathy: A case Report

A.Q.M. Reza, Nighat Islam, S.U. Talukdar, Aparajita Karim, Mahmood Hasan Khan, Poppy Bala, Shams Munwar, Tamzeed Ahmed, Ataher Ali, Kazi Atiqur Rahman,

AHM Waliul islam, Abeeda Tasneem Reza

Department of Cardiology, Evercare Hospital Dhaka

### Abstract:

*Alcohol septal ablation (ASA) has shown to be a safe and effective procedure for treatment of symptomatic hypertrophic obstructive cardiomyopathy (HOCM) for more than 20 years with results similar to those of surgical myectomy. The first septal branch of the left anterior descending artery (LAD) is located and 96% alcohol is instilled to induce an artificial myocardial infarction and necrosis at the base of the hypertrophied septum. Now we present our first experience of a patient with HOCM with a very high left ventricular outflow tract gradient who had successful alcohol septal ablation.*

*(Cardiovasc j 2022; 15(1): 95-99)*

### Key Words :

*Genetic disorder, Hypertrophic obstructive cardiomyopathy, Alcohol septal ablation, left ventricle*

### Introduction:

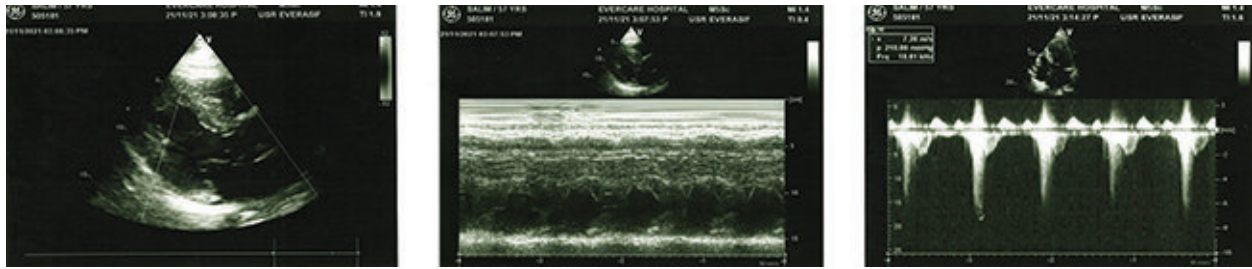
Hypertrophic cardiomyopathy (HCM) is a genetic disorder of cardiac muscle characterized by left ventricular hypertrophy, myofibrillar disarray and myocardial stiffness.<sup>1</sup> It is inherited as an autosomal dominant trait. Some patients with HOCM have no symptoms, while others have dyspnea (90% cases), chest pain (70-80% cases), or syncope (20% cases); a subset of patients is at risk of sudden cardiac death.<sup>2</sup> Hypertrophic cardiomyopathy patients with LV outflow tract (LVOT) gradients in resting conditions or with provocation (as with Valsalva manoeuvre or exercise) are classified as having HOCM. Septal reduction therapy for patients with HCM can be done either by surgical myectomy or by alcohol septal ablation. Transcoronary ablation of septal hypertrophy has become an important option for treating symptomatic HOCM.<sup>3</sup> We present the first clinical case at Evercare Hospitals Dhaka of a very high LVOT gradient (>200 mm Hg) HOCM treated with ASA with significant reduction >50% of gradient after procedure.

### Case Report:

A 57-year-old man with a history of HTN was diagnosed with HOCM 7 years ago. He had progressive worsening of dyspnea on exertion and generalized fatigue for previous 3 years. He was also diagnosed as a case of sick sinus disease and Dual chamber Pace maker implantation done on 2014. He also had NSTEMI and Mild CAD found on subsequent coronary angiogram on 2019. He had an episode of presyncope 6 months back. Despite medical treatment with metoprolol, he complained of fatigue and shortness of breath during walking (NYHA class III). The echocardiography showed asymmetric septal hypertrophy (septal thickness 20 mm) (Fig 1A), SAM with septal contact (Fig 1B) and an elevated LVOT pressure gradient (210 mm Hg) (Fig 1C) with mild mitral regurgitation. Cardiac catheterization was performed observing coronary arteries without significant lesions and adequate diameter of single 1<sup>st</sup> septal branch. We decided to perform Alcohol Septal Ablation.

**Address of Correspondence:** Dr. Nighat Islam, Department of Cardiology, Evercare Hospital Dhaka, Bangladesh. Email: [nighat52bd@gmail.com](mailto:nighat52bd@gmail.com)

© 2022 authors; licensed and published by International Society of Cardiovascular Ultrasound, Bangladesh Chapter and Bangladesh Society of Geriatric Cardiology. This is an Open Access article distributed under the terms of the CC BY NC 4.0 (<https://creativecommons.org/licenses/by-nc/4.0>)

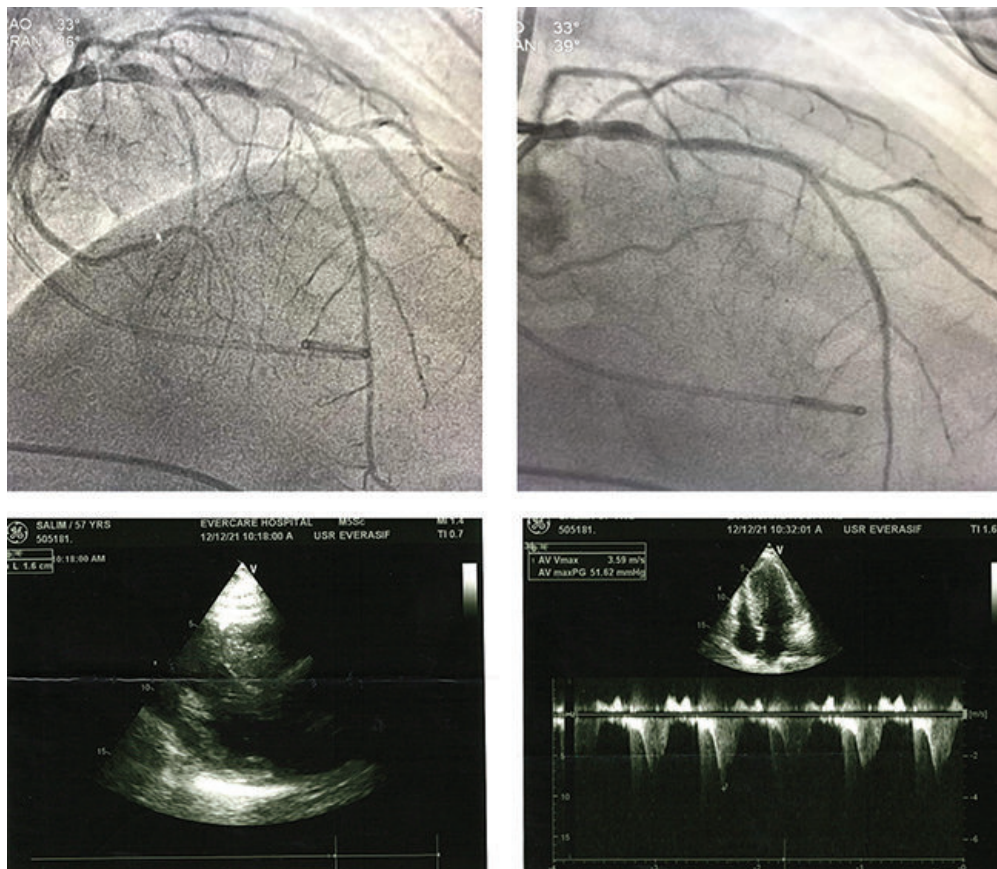


**Fig-1:** (A) Asymmetrical septal hypertrophy (septal thickness 20 mm). (B) Systolic anterior motion of anterior mitral leaflet. (C) LVOT pressure gradient 210 mm of Hg.

**Technique:**

Intravenous anaesthesia was used without intubation. Right radial and right femoral accesses were made. A pigtail catheter was placed in LV for pressure assessment during the procedure through right radial access. Temporary pace maker also introduced through right femoral venous access. The baseline outflow tract gradient was recorded. Through the right femoral access, the left main

coronary artery was cannulated and with a 6 Fr guide catheter first septal branch of LAD was delineated (Fig 2A). A 0.014 guidewire was introduced into the first septal branch and an over the wire balloon catheter of 2.0 x 12 mm was crossed through the guidewire placing it in the septal branch and it was inflated to 6 ATM to demonstrate septal perforator occlusion and confirmed uncompromised LAD flow by contrast injection.



**Fig-2:** (A) The first septal branch of the left anterior descending artery clearly delineated by coronary angiography. (B) The vessel stump after alcohol injection and removal of the balloon. (C) Increased echogenicity of basal anteroseptum after alcohol injection. (D) Decreased pressure gradient Across LVOT (51 mm of Hg) after alcohol injection.

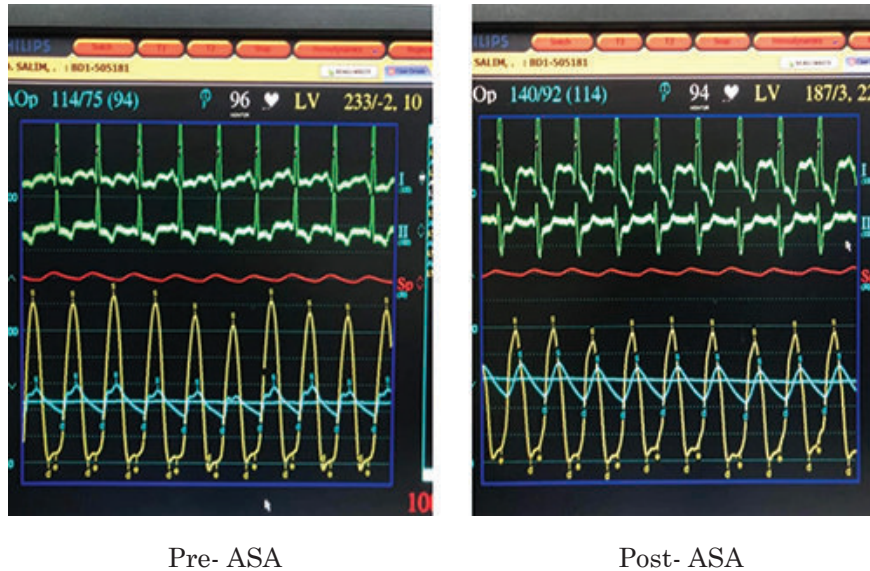
Once confirmed by echocardiography that the area irrigated by the septal branch corresponded directly to the territory of hypertrophy by small amount of contrast injection. Also meticulously followed presence of any big collateral branch. 96% alcohol infusion was slowly initiated 2 ml followed by 1 ml at a total of 3 ml. The balloon catheter 2.0 x 12 mm was inflated during the alcohol infusion to protect the anterior descending artery for 10 minutes. Contrast was injected to LAD showing an adequate TIMI III flow and occluded vessel stump of first septal branch (Figure 2B).

Echocardiography showed increased echogenicity of basal anteroseptum (Fig 2C) after alcohol injection. The subvalvular pressure gradient across the left ventricular outflow tract decreased from 210 to 51 mm Hg (Fig 2D). Immediately after the procedure, the LVOT pressure gradient

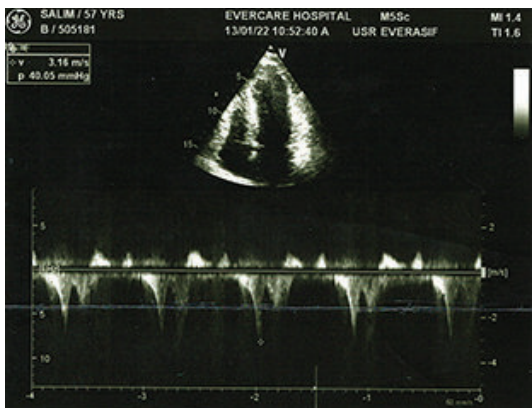
decreased from 119 to 45 mm Hg (Fig 3), also the contractility in the basal septum decreased after 10 minutes of balloon occlusion. The patient was transferred to the coronary care unit and was discharged home four days after the intervention. No new heart block was present and maximum rise of Hs Troponin I was >50000.

Follow up echocardiogram of patient after 1 month showed that decreased thickness of basal septum with subvalvular pressure gradient across the left ventricular outflow tract decreased to 40 mm Hg. (Fig 4)

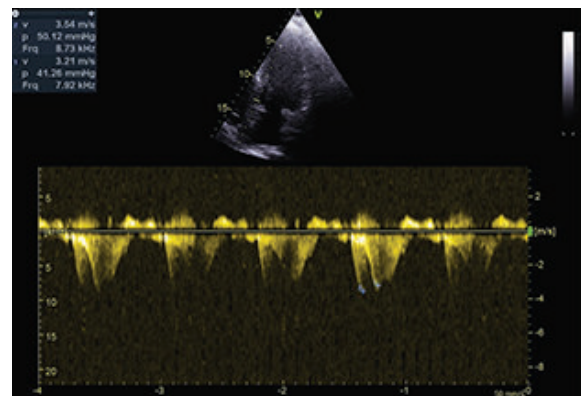
Follow up echocardiogram of patient after 4 months showed that decreased thickness of basal septum (15 mm) with subvalvular pressure gradient across the left ventricular outflow tract 50 mm Hg. (Fig 5). No SAM of AML seen in Fig 6.



**Fig.-3:** LVOT pressure gradient before (119 mm Hg) & after (45 mm Hg) septal ablation.

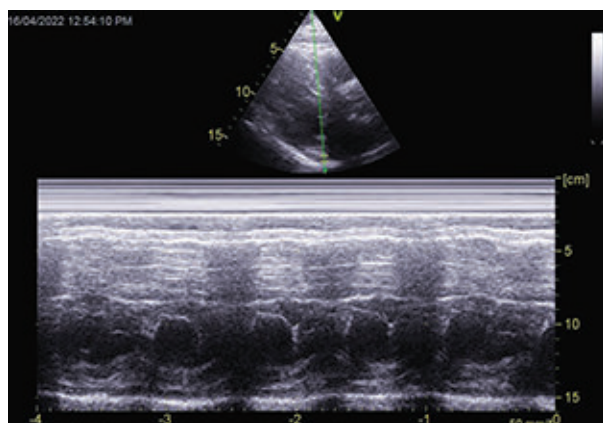


**Fig.-4:** Decreased pressure gradient Across LVOT (40 mm of Hg) after one month.



**Fig.-5:** Pressure gradient Across LVOT (50 mm of Hg) after 4 months.





**Fig.-6:** No SAM of AML.

### Discussion:

The hypertrophic cardiomyopathy is a genetic pathology defined by the presence of left ventricular hypertrophy, myofibrillar disarray, and myocardial stiffness. HCM is the first identifiable cause of sudden death in young athletes.<sup>1</sup> Patients with HCM can present LVOT obstruction, diastolic dysfunction, myocardial ischemia and mitral insufficiency.

The clinical course of HOCM can be quite variable. Many patients remain asymptomatic. While others may present with a typical chest pain, dyspnoea, syncope, vertigo, heart failure, uncomfortable awareness of the heart beat, fatigue and sudden cardiac death.<sup>4</sup> Our patient complained of shortness of breath during exercise (NYHA class III), fatigue and presyncope despite of medical therapy.

These patients have asymmetric septal hypertrophy and systolic anterior motion of the mitral valve into the LVOT, leading to resting or provokable pressure gradients that can be demonstrated by Doppler echocardiography.<sup>2</sup> Our patient had asymmetric septal hypertrophy (septal thickness 20 mm, left ventricular posterior wall thickness 13 mm), systolic anterior motion of the mitral valve into the LVOT, leading to resting pressure gradient (210 mm Hg) with mild mitral regurgitation.

To improve functional limitations, reduce the extent of the outflow obstruction and improve the diastolic filling is the goal of treatment of symptomatic patients with HOCM.<sup>5</sup> The treatment of obstructive HCM has largely relied on pharmacologic management of the disease with

beta-blockers and calcium channel blockers. A small but important subgroup of patients are refractory to medical therapy.<sup>5</sup> Our patient was non responsive to medical therapy.

In 1994 to 2000, roughly 1000 patients in 20 countries underwent Transcatheter ablation of septal hypertrophy (TASH) for HOCM. Despite limited published research, TASH was an established technique by 2000.<sup>6</sup>

By 2009, TASH has become a well established treatment for HOCM, while surgical myectomy, despite excellent results, became available in only a few centers. Patients desire for less invasive procedures led to the increased use of TASH over surgical myectomy and by 2009 the gold standard began to drift toward TASH.<sup>7</sup>

Patients who benefit most from TASH have drug refractory, daily life limiting symptoms from HOCM. More specifically they have NYHA class III or IV and CCS angina class III or IV status (dyspnea, angina or syncopal equivalents).<sup>8</sup> In addition, the ACC/ESC recommends that two additional selection criteria be employed in selecting patients for this procedure 1) Septal hypertrophy of 18 mm or more and 2) Resting or provokable gradient of 50 mm Hg or more.<sup>9</sup>

In HOCM patients TASH has resulted in a level of clinical improvement similar to that of surgical septal myectomy. This method has been shown to cause LV remodelling with significant reduction in LV hypertrophy at 1 to 2 years post TASH.<sup>10</sup> Exclusion criteria include younger age, severe hypertrophy of septum, unsuitable anatomy for delivery of alcohol and multiple comorbidities.<sup>3</sup>

Well demarcated coagulative necrosis of the myocardium and vascular endothelium occurs immediately after alcohol is injected into the target vessel. There is initial stunning with immediate reduction in the gradient followed by a modest rise in the gradient due possibly to recovery from stunning or to increasing myocardial edema that lasts 5-10 days. Finally with scarring and thinning of the basal septum there is widening of the LVOT, reverse remodelling of LV and progressive alleviation of the gradient over the following several months.<sup>11</sup>

Surgical myectomy also has been shown to consistently, completely and rapidly relieve symptoms particularly in patients younger than 65 yrs of age.<sup>12</sup> Overall, TASH has been deemed safer than surgical correction of HOCM. Mortality from TASH has been linked to complete heart block, arrhythmia (ST-segment elevation, ventricular fibrillation or tachycardia, sinus bradycardia), LAD dissection, cardiogenic shock and cardiac tamponade. Complications unique to TASH include spillover from target territory, conduction abnormalities, and arrhythmogenicity.

This procedure alleviates symptoms by producing a targeted, limited infarction of the upper interventricular septum, resulting in an increase in LVOT diameter, a decrease in LVOT gradient, and regression of the component of LV hypertrophy that is due to pressure overload.<sup>3</sup> Improvement in symptoms and reduction in gradient, is achieved in the great majority of patients with either resting or provokable LVOT obstruction.

Now there is a new hope for patients with HOCM, a new drug named Mavacamten, a cardiac myosin inhibitor. It reduces cardiac muscle contractility by inhibiting excessive myosin-actin cross-bridge formation that results in hypercontractility, left ventricular hypertrophy and reduced compliance.

### Conclusion:

Septal myectomy remains the gold standard for the management of refractory HOCM, but may be not for long. Alcohol septal ablation has developed as a safe and attractive modality to treat these patients. Short and longterm outcomes for the two treatment modalities appear to be similar, suggesting a promising future for TASH. Alcohol septal ablation at our hospital showed immediate and four months follow up of LVOT pressure gradient reduction without any complication. We consider ASA as a safe and effective procedure in the reduction of very high LVOT gradient in selective patients with HOCM.

### Limitations:

Ideally contrast echo should be done to determine perfect septal branch, which we could not do due to contrast unavailability.

---

**Conflict of Interest - None.**

---

### References:

1. Masry H, Breall J. Alcohol Septal Ablation for Hypertrophic Obstructive Cardiomyopathy. *Curr Cardiol Rev.* 2008; 4(3):193-197. doi:10.2174/157340308785160561
2. Mayes CE Jr, Wang A, Warner JJ, et al. Alcohol ablation of the intraventricular septum in symptomatic patients with hypertrophic obstructive cardiomyopathy [published correction appears in *N C Med J.* 2002 Jul-Aug;63(4):234]. *N C Med J.* 2002; 63(3):136-140.
3. Fifer M, Sigwart U. Hypertrophic obstructive cardiomyopathy: alcohol septal ablation. *Eur Heart J.* 2011;32(9):1059-1064. doi:10.1093/eurheartj/ehr013
4. Kuliæ M, Spu·iæ M, Tahiroviæ E et al. Successful Percutaneous Septal Alcohol Ablation After Surgical Myectomy. *Bosn J Basic Med Sci.* 2010; 10(3):218-222. doi:10.17305/bjbm.s.2010.2690
5. Maron MS, Olivotto I, Betocchi S, et al. Effect of left ventricular outflow tract obstruction on clinical outcome in hypertrophic cardiomyopathy. *N Engl J Med.* 2003; 348(4):295-303. doi:10.1056/NEJMoa021332
6. Gietzen FH, Leuner CJ, Obergassel L, Strunk-Mueller C, Kuhn H. Transcoronary ablation of septal hypertrophy for hypertrophic obstructive cardiomyopathy: feasibility, clinical benefit, and short term results in elderly patients. *Heart.* 2004;90(6):638-644. doi:10.1136/hrt.2003.017509
7. Parakh N, Bhargava B. Golden jubilee of hypertrophic cardiomyopathy: is alcohol septal ablation the gold standard? *Cardiovasc Revasc Med.* 2009; 10(3):172-178. doi:10.1016/j.carrev.2009.02.006
8. Firoozi S, Elliott PM, Sharma S, et al. Septal myotomy-myectomy and transcoronary septal alcohol ablation in hypertrophic obstructive cardiomyopathy. A comparison of clinical, haemodynamic and exercise outcomes. *Eur Heart J.* 2002; 23(20):1617-1624. doi:10.1053/ehj.2002.3285
9. Maron BJ, McKenna WJ, Danielson GK, et al. American College of Cardiology/European Society of Cardiology clinical expert consensus document on hypertrophic cardiomyopathy. A report of the American College of Cardiology Foundation Task Force on Clinical Expert Consensus Documents and the European Society of Cardiology Committee for Practice Guidelines. *J Am Coll Cardiol.* 2003; 42(9):1687-1713. doi:10.1016/s0735-1097(03)00941-0
10. Mazur W, Nagueh SF, Lakkis NM, et al. Regression of left ventricular hypertrophy after nonsurgical septal reduction therapy for hypertrophic obstructive cardiomyopathy. *Circulation.* 2001;103(11):1492-1496. doi:10.1161/01.cir.103.11.1492
11. Meliga E, Steendijk P, Valgimigli M, Ten Cate FJ, Serruys PW. Effects of percutaneous transluminal septal myocardial ablation for obstructive hypertrophic cardiomyopathy on systolic and diastolic left ventricular function assessed by pressure-volume loops. *Am J Cardiol.* 2008;101(8):1179-1184. doi:10.1016/j.amjcard.2007.12.016
12. Maron BJ, Yacoub M, Dearani JA. Controversies in cardiovascular medicine. Benefits of surgery in obstructive hypertrophic cardiomyopathy: bring septal myectomy back for European patients. *Eur Heart J.* 2011; 32(9): 1055-1058. doi:10.1093/eurheartj/ehr006