

# Surgical Management of Vascular Complications in Intravenous Drug Abusers: Experience at the National Institute of Cardiovascular Diseases (NICVD), Bangladesh.

AHM Bashar<sup>1</sup>, MN Sabah<sup>1</sup>, MF Hossain<sup>1</sup>, QA Azad<sup>1</sup>, QM Alam<sup>1</sup>, GMM Hossain<sup>1</sup>, E Hakim<sup>1</sup>, MW Bhuiyan<sup>2</sup>, MM Rahman<sup>2</sup>, SAN Alam<sup>1</sup>, N Ahmed<sup>1</sup>

<sup>1</sup>Department of Vascular Surgery, NICVD, Dhaka. <sup>2</sup>Department of Radiology and Imaging, NICVD, Dhaka.

## Abstract:

**Key words:**  
Intravenous drug abuse, Vascular complication, Aneurysm.

**Background:** Intravenous drug abuse (IVDA) is a global health care problem that has tremendous socio-economic implications. Vascular complications following IVDA are not uncommon and may have serious consequences. At the National Institute of Cardiovascular Diseases (NICVD), Dhaka, Bangladesh, there has been a steady increase in the number of cases with vascular complications of IVDA in the recent years.

**Objectives:** The present study was undertaken to evaluate our surgical strategy for the management of various vascular complications following IVDA.

**Materials and Methods:** Over the last 5 years, a total of 45 patients presented at the NICVD with various complications of IVDA. Thirty seven patients presented at the emergency department with bleeding from ruptured aneurysm or with impending aneurysm rupture. The remaining 8 patients presented at the vascular outpatient with deep venous thrombosis, superficial thrombophlebitis and chronic venous insufficiency. After resuscitation when necessary, excision of aneurysm was done either with simple ligation of the artery (Group A) or with restoration of arterial continuity (Group B). Outcome in the two groups were compared against the following parameters; acute limb ischemia, chronic limb ischemia, wound infection and lymphorrhoea.

**Results:** There was no in-hospital mortality in this series. Both ligation and restoration of arterial continuity following aneurysmectomy were effective in treating the bleeding aneurysm. However, statistically significant differences were seen between the two groups in terms of acute and chronic limb ischemia. Restoration of arterial continuity was more effective in preventing acute and chronic limb ischemia.

**Conclusions:** In Bangladesh, the incidence of IVDA with vascular complications is increasing at an alarming rate. In patients presenting with arterial pseudoaneurysms, surgical management should be aimed at restoration of arterial continuity whenever feasible.

(*Cardiovasc. j.* 2010; 3(1) : 45-49)

## Background :

Intravenous drug abuse (IVDA) is a global health care problem that has tremendous socio-economic implications.<sup>1</sup> Although the true magnitude of the problem is not readily apparent, it exists in every society and is sometimes found to assume alarming proportions. IVDA can complicate virtually every organ and system of the body. Deadly viruses such as hepatic viruses, HIV and other pathogens like bacteria and fungi can be introduced.<sup>2</sup> Such infections can spread to the vital organs of the body

causing serious complications ranging up to systemic inflammatory response syndrome or sepsis. Vascular complications following intravascular injections of addictive drugs are not infrequent. Most of the time, they present as vascular emergencies and unless quickly and efficiently managed, there may be catastrophic consequences. Such management often requires an integrated approach with participation of not only vascular surgeons but also dedicated nursing staff and anesthetists. Unfortunately, there is little

awareness among the common people about the deadly consequences of IVDA- one of the reasons why such complications are increasing day by day. At the National Institute of Cardiovascular Diseases (NICVD), Dhaka, Bangladesh, there has been a steady rise in the number of cases with vascular complications of IVDA in the recent years. NICVD is the only center in Bangladesh equipped with facilities to deal with vascular emergencies. However, to the best of our knowledge, a systematic analysis of vascular complications following IVDA and the management strategy followed for them has not yet been undertaken.

### Objectives:

The present study was undertaken to evaluate our surgical strategy for the management of various vascular complications following intravenous drug abuse.

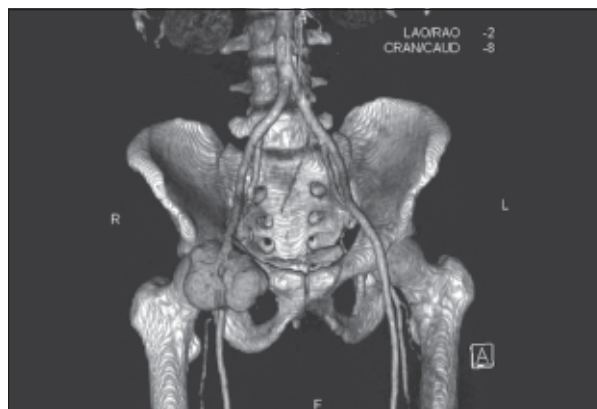
### Materials and Methods:

**Study Population:** Over the last 5 years between July 2005 and June 2010, a total of 45 patients presented at the NICVD with various complications of IVDA. Thirty seven patients presented at the emergency department with bleeding from ruptured aneurysm or impending aneurysm rupture. The remaining 8 patients presented at the vascular outpatient department with deep venous thrombosis (DVT), superficial thrombophlebitis, and chronic venous insufficiency (CVI). The mean age of the patients was 29.2 years (range 17-50 years). The various modalities of presentations are given in the Table below;

**Table-I**

*Table showing frequency of presentations of vascular complications in IVDA.*

Presentations	No. of Cases
Pseudoaneurysm	37
Ruptured	20
Impending rupture	12
Stable	05
Deep venous thrombosis	04
Superficial thrombophlebitis	03
Chronic venous insufficiency	01



**Fig-1:** *Computed tomographic angiogram showing a fusiform aneurysm in the right common femoral artery resulting from repeated injection at the right groin.*

The commonest site of pseudoaneurysm formation (Figure 1) was the common femoral artery (CFA) (17 cases). Twelve patients had aneurysm in the superficial femoral artery (SFA), two in the deep femoral artery (DFA), five in the brachial artery (BA) and one in the radial artery (RA).

### Protocol at NICVD for vascular complications of IVDA:

**Diagnosis:** Diagnosis of vascular complications in IVDA is usually fairly straightforward, especially when the presentation is as dramatic as a ruptured aneurysm. In less dramatic situations, a careful history taking becomes crucial. Often, the attendants are more helpful than the patient himself in this regard.

**Preoperative Work-up:** Screening for hepatic and Human Immunodeficiency Viruses (HIV) is done whenever the situation permits. A complete blood count, blood sugar level and hepatic and renal functions as well as serum electrolytes are evaluated. A computed tomographic angiogram (CTA) of the vascular tree proximal and distal to the lesion is obtained to plan surgical strategy. However, these are only possible when the patient has been hemodynamically stabilized and thus surgery can be deferred for a day or two. In many patients, this is not possible and immediate surgery must be performed to obtain hemostasis. Thus the vascular surgeons, anesthetists and other operation theatre staff are exposed to the threat of being infected by deadly viruses.

*Restoration of hemodynamic stability:* Since the majority of patients with vascular complications in IVDA present with aneurysm rupture, many of them are in a state of shock at presentation. Therefore, all initial efforts are directed at restoration of hemodynamic stability. Pressure bandage is applied to the bleeding aneurysm to obtain temporary hemostasis. Multiple peripheral venous accesses are obtained. This, however, is often not possible as many of these patients already have all their peripheral veins sclerosed as a result of repeated puncture. In such patients, a central venous line is the only option that remains. This is when the participation of an expert anesthetist becomes crucial. Once a central venous access has been established, blood transfusion along with infusions of crystalloids and volume expanders and injections of inotropic agents are used with careful monitoring of the hemodynamics. Patients in profound hemodynamic derangement are transferred to intensive care unit where among others, central venous pressure and oxygen saturation are monitored.

*Surgical Management:* As already mentioned, surgical strategy in patients presenting with aneurysm follows two basic principles:

1. Aneurysmectomy with ligation of the diseased artery
2. Aneurysmectomy with restoration of arterial continuity.

*Aneurysmectomy with ligation of the diseased artery:* This is done when there is florid infection at the aneurysm site and when the operation time must be shortened as in patients with profound hemodynamic derangement. Control is taken of the artery proximal and distal to the aneurysm. The aneurysm, which is usually filled with mural thrombus, is longitudinally opened. The aneurysm sac along with thrombus is removed and generous debridement of the infected tissue in the vicinity of the aneurysm is performed along with surgical toileting. Transfixation of the artery both proximal and distal to the aneurysm is done using 2-0 or 3-0 prolene. After obtaining meticulous hemostasis, the wound is either left open or closed with a negative suction drain whenever possible.

*Aneurysmectomy with restoration of arterial continuity:* Attempt at restoration of arterial continuity is made in hemodynamically stable

patients with CFA pseudoaneurysm in the absence of florid infection. Following aneurysmectomy, the patient is systemically heparinized and healthy segments of the artery proximal and distal to the aneurysm are isolated. Retrograde flow in the distal artery is checked and Fogarty embolectomy done whenever necessary. For the restoration of arterial continuity, end to end anastomosis is rarely possible. Interposition of either reversed vein graft or prosthetic graft is usually required. Autologous vein graft is preferred over prosthetic graft whenever a vein of satisfactory length and caliber can be harvested. Since the great saphenous vein in this group of patients often has phlebotic change, the availability of a good venous conduit is never guaranteed. In such patients, prosthetic graft—either silver coated woven Dacron or ringed Polytetrafluoroethylene (PTFE) is used as interposition graft.

*Post-operative care:* Antibiotic is used to cover both Gram-positive and Gram-negative bacteria as well as anaerobes. Antifungal agents are not routinely used. Heparin is used for a short period to be switched to oral clopidogrel and aspirin for the next 3 months. The patient is usually discharged on the 2<sup>nd</sup> or 3<sup>rd</sup> postoperative day with advice for meticulous wound care at a general surgical facility. Patients are followed up clinically as well as with vascular Duplex study 1 week, 1 month and 3 months after the surgical intervention.

*Medical Management:* Patients presenting with DVT, CVI or superficial thrombophlebitis are managed conservatively on an outpatient basis. For DVT, oral anticoagulant (Warfarin) titrated for an International Normalized Ratio (INR) of 2.5-3 is continued for at least 6 months. Periodic Duplex scanning is done to check for recanalization and the development of insufficiency in the superficial and deep veins. CVI is managed with graduated compression stocking, Diohes and care of venous ulcer, if any. As for superficial thrombophlebitis, local analgesia is all that is usually required.

**Study Design:** We divided the 37 patients presenting with arterial pseudoaneurysm following IVDA into 2 groups; Group A consisted of 22 patients in whom aneurysmectomy with simple

ligation of the artery was done. In Group B (15 patient), arterial reconstruction was done either by end to end anastomosis (n=2) or by interposition grafting together with aneurysmectomy (n-13). Outcome in the two groups were compared against the following parameters; acute limb ischemia, chronic limb ischemia, wound infection and lymphorrhoea.

*Acute limb ischemia* was defined as acute ischemic symptoms with a drop in Ankle-Brachial Pressure Index below 0.5 within 2 weeks after the operation.

*Chronic limb ischemia* was defined as intermittent claudication, ischemic rest pain or tissue loss with a fall in ABPI below 0.6, 2 weeks after the operation.

**Statistical Analysis:** Student's *t* test was used to determine significant differences between the two groups and a P value of <0.05 was considered statistically significant.

### Results:

There was no in-hospital mortality in the present series. Out of the 20 patients presenting with ruptured aneurysm, 12 were brought at the emergency in a state of shock which was managed according to the protocol described above. As for surgical outcome, both ligation and arterial reconstruction either by end to end anastomosis or with interposition grafting were successful in obtaining hemostasis. In Group A, 3 patients (13.6 %) developed acute limb ischemia and 1 had to be sent for amputation (4.54 %). In group B, 1 patient developed chronic limb ischemia as a result of graft thrombosis (6.6 %). Graft infection was found in this patient, for which excision of the graft along with ligation of the artery was done 2 months after the procedure. The patient was advised angiogram with revascularization. Unfortunately, he never returned. Wound infection was more common in Group A (6 / 27.2%) than in Group B (2 / 13.3 %). Lymphorrhoea was more common in Group A (4 / 18.1 %) than in Group B (2 / 13.3%). Differences between the two groups were statistically significant for all four outcome parameters (p=0.05, 0.01, 0.04 and 0.03, respectively).

Major post-operative outcomes in the two groups are summarized in the Table- 2 below;

**Table-II**

*Summarizing the major post-operative outcomes in patients undergoing surgery for arterial pseudoaneurysm following IVDA.*

Group	ALI	CLI	Wound Infection	Lymphorrhoea
A (n= 22)	3 (13.6%)	0	6 (27.2%)	4 (18.1%)
B (n= 15)	0	1 (6.6%)	2 (13.3%)	2 (13.3%)

ALI: Acute Limb Ischemia, CLI: Chronic Limb Ischemia

### Discussion:

Drug use and abuse are nearly as old as mankind. The history of farming dates back to 6000 BC and after that, it did not take too long for fermentation of agricultural product to begin. The ability of fermented material to make one feel euphoric or oblivious of reality quickly appealed to human mind. Ever since substances having similar properties have been looked for in the nature, isolated and used to satisfy a basic human desire-to feel happy. The hypodermic needle and syringe in its current form was invented by the French scientist Pravaz in 1851 and became especially known during wars. Many addictive drugs suitable for parenteral administration were discovered in the following years. Newer agents with stronger addictive potential continue to emerge. While opioids have traditionally been the drugs that have the strongest appeal to the users, many combination drugs- infamously known as 'cocktails' have become popular in the Indian subcontinent in recent times. Due to their lower cost, such cocktails are used more often by abusers belonging to lower economic class.

The health hazards of IVDA are manifold. Most relevant among them from a public health point of view is the spread of life threatening infections especially HCV and HIV. Poor hygienic condition, malnutrition and the use of contaminated needle for injecting addictive substances are the main reasons behind it. Unless dealt in a concerted manner, spread of such infections can reach a dangerous level creating a public health crisis. Health professionals dealing with these patients run a particularly high risk of getting infected by these deadly viruses. While individual protective measures according to the 'universal protection'<sup>3</sup> protocol is always helpful, the importance of a quick screening for the above-mentioned viruses before the operation cannot be overemphasized. In the present series, 12 out of the 20 patients presenting with ruptured aneurysm had to be operated without viral screening. In the

remaining patients, 8 were operated with known hepatitis B virus surface antigen (HBSAg) positivity. This underscores the fact that vascular surgeons and others taking care of these patients should have themselves vaccinated against HBSAg and have their antibody titres measured at regular intervals. Institutional regulations as well as government health policy should also incorporate appropriate strategy in this regard.

As for the surgical outcome, both ligation and arterial reconstruction were effective in treating the bleeding aneurysm although restoration of arterial continuity was more effective in preventing acute and chronic limb ischemia. Our results are in agreement with Manekeller et al. reporting on a small series of 10 patients. The authors showed that ligation was an acceptable surgical strategy.<sup>4</sup> This suggestion, however, must be interpreted with caution. Successful treatment based on ligation alone is safe only for isolated lesions of the SFA or DFA. Because the CFA and femoral bifurcation are very commonly involved, revascularization will be safer in most cases. Behera et al. reporting on an Indian series with vascular complications following IVDA argued that ligation alone was safe in cases where there was postoperative Doppler signal in the distal arteries.<sup>5</sup> This simple measure may be useful in isolating the subgroup of patients at risk of developing limb ischemia after the initial surgery, although we do not routinely employ the Doppler evaluation of the distal arteries following ligation. Klonaris et al. have described the use of internal iliac artery as conduit for revascularization.<sup>6</sup> This may be an attractive option, although we never used this conduit in our series. If complete covering of the defect is not possible, a Sartorius muscle flap is a good choice. Primary wound closure can be problematic because of recurrence; therefore vacuum-assisted wound closure is a valuable addition to the overall therapeutic approach in these cases. We routinely use a negative suction drain whenever we close the wound. In most instances, such wounds would require long-term general surgical care with repeated bacteriological assessment of the wound.

In the event of postoperative limb ischaemia- either acute or chronic, angiographic evaluation with revascularization should be done whenever feasible. Unfortunately the only patient who developed chronic limb ischaemia in this series did not return to hospital for angiographic evaluation. It is not possible to preoperatively predict which patient would develop critical limb ischaemia in the postoperative period. However preoperative CTA can give useful

information about the distal vasculature and the development of collaterals. In cases where arterial reconstruction is done, surgeons must be judicious in choosing the graft material. Pseudoaneurysms in IVDA almost always have some degree of infection and the use of prosthetic graft in infected sites is hardly recommendable. Therefore autologous vein graft should be used whenever possible.<sup>7,8</sup>

### Conclusion:

In Bangladesh, the incidence of IV drug abuse with vascular complications is increasing at an alarming rate. People of all socioeconomic classes have fallen prey to this menacing social problem. Unfortunately there is little awareness among the common people regarding the deadly consequences of IV drug abuse. Systematic awareness campaign by both government and non-government organizations should be initiated to minimize the incidence of IV drug abuse. Management of vascular complications of IVDA requires dedicated centers with vascular surgical expertise and appropriate logistic support. The present study as well as relevant literatures suggests that surgical management of arterial pseudoaneurysm resulting from IVDA should include restoration of arterial continuity, whenever feasible to avoid acute and chronic limb ischemia.

### References:

1. Hassan A, Csemy L, Rappo MA, Knight JR. Adolescent substance abuse around the world: an international perspective. *Adolesc Med State Art Rev.* 2009;20(3):915-29.
2. Miró JM, del Río A, Mestres CA. Infective endocarditis in intravenous drug abusers and HIV-1 infected patients. *Infect Dis Clin North Am* 2002;16(2):273-95.
3. Williams N S, Bulstrode CJK, O'Connell PR. *Bailey and Love's Short Practice of Surgery* (2008), Hodder Arnold, London, UK.
4. Manekeller S, Tolba RH, Schroeder S, Lauschke H, Remig J, Hirner A. Analysis of vascular complications in intra-venous drug addicts after puncture of femoral vessels. *Zentralbl Chir* 2004;129(1):21-8.
5. Behera A, Menakuru SR, Jindal R. Vascular complications of drug abuse: an Indian experience. *ANZ J Surg* 2003;73(12):1004-7.
6. Klonaris C, Katsargyris A, Papapetrou A. *et al.* Infected femoral artery pseudoaneurysm in drug addicts: the beneficial use of the internal iliac artery for arterial reconstruction. *J Vasc Surg* 2007;45(3):498-504.
7. Scheuerlein H, Ruff S, Haage P, Zirngibl H, Fraunhofer S, Settmacher U. Groin abscesses and vascular catastrophes in intravenous drug users—strategy and results. *Zentralbl Chir* 2008;133(1):55-60.
8. Yegane RA, Salehi NA, Ghaseminegad A *et al.* Surgical approach to vascular complications of intravenous drug abuse. *Eur J Vasc Endovasc Surg* 2006;32(4):397-401.