

Ventricular Septal Defect in Children with Down Syndrome-Two Case Reports

MK Hassan¹, KA Hasan¹, SA Quader¹, R Sarker¹, F Ahmed¹, A Salam², SK Razzaque²,
Azhari Yakub³, KN Mahmood¹

¹Department of Cardiovascular Surgery, NICVD, ²Department of Paediatric Cardiology, NICVD,

³Department of Cardiothoracic Surgery, IJN, Malaysia .

Abstract:

Key words:
Down syndrome,
Ventricular septal
defect.

The association of Down syndrome (DS) with congenital cardiovascular malformation is well established. Complete atrioventricular septal defects have been associated most commonly with DS. There are also reports of VSD, ASD, TOF and PDA with DS. We here reported two patients of Down syndrome with ventricular septal defect (VSD), underwent repair of VSD, diagnosis was suggested by echocardiography and confirmed by surgery and chromosomal study. Both the patient discharged from hospital with good result. Survival and quality of life have been improving in patient with Down syndrome after repairing VSD.

(Cardiovasc. j. 2010; 3(1) : 107-109)

Introduction:

The spectrum of congenital cardiovascular malformation (CCVM) in patient with Down syndrome is variable.¹ Approximately 40% of newborns who have Trisomy 21 (Down syndrome) have cardiac malformation and of those who have a heart defect, about 30% have ventricular septal defect (VSD). A complete AV septal defect (AVSD) is seen in 40%, atrial septal defect (ASD) in 9%, Tetralogy of Fallot (TOF) in 6% and Patent Ductus Arteriosus (PDA) in 9%.²

Actually congenital heart disease or congenital heart defect includes a variety of structural problems of the heart or its major blood vessels which are present at birth. Ventricular Septal Defect (VSD) accounts for about 14-16% of all cases of congenital cardiovascular defects.³ About eight of every 100 infants or 1% of live births are born every year with congenital cardiovascular defects, the most common birth defect. It is the number one cause of death from birth defect during the first year of life.³

The clinical manifestations of Down syndrome are numerous and can present in any body system. The most significant include intellectual impairment, short stature, heart disease, digestive disease, orthopedic abnormalities³ and congenital vascular malformation.⁵ Heart disease is, without

a doubt, the main factor contributing to a favorable or unfavorable cause in these patients.

In patient with DS, pulmonary arterial hypertension (PAH) has been suggested to develop earlier and to have more violent course. Eisenmenger's syndrome carries a high risk of morbidity in a relatively young patient population and has limited therapeutic option.⁴ The main causes of death in Down syndrome with heart disease are heart failure, sepsis and pulmonary hypertension. This last process appears earlier in patients with atrioventricular septal defect (AVSD) and results in a reduction in survival of up to 58%.³ The incidence of upper airway obstruction in Down syndrome is to be 30-50%.⁴ Down syndrome individuals have a higher rate of infections, especially respiratory tract infections (RTI) which is 50 times more common compared to the general population. Bronchopneumonia is a common cause of death with mortality rate 124 times that of the general population.⁴

We, here in, discuss two patients with this syndrome having ventricular septal defect with severe respiratory tract infections.

Case 1

Clinical presentation: A 4 years old male child was admitted had facial dysmorphism (hyper letorism, upward slanting of palpebral fissure, flat nasal

bridge, epicanthial folds and protruding tongue), short broad hands, simian crease in both hands, suggestive of Down syndrome. On auscultation of the chest, breath sounds are vesicular. In a cardiovascular examination a pansystolic murmur was present, grade 4/6, best heard in the left 4th intercostal space in the para sternal area and radiating to the whole of the precordium, compatible with clinical diagnosis of ventricular septal defect. Other systemic examination was unremarkable at admission.

Investigations: Echocardiography revealed a moderate size (7 mm), membranous ventricular septal defect with a shunt from left ventricle to right ventricle (fig:1). Karyo typing of the child was done and showed trisomy of chromosome 21, haemoglobin was 11 g/dl, renal function test and electrolyte was normal.

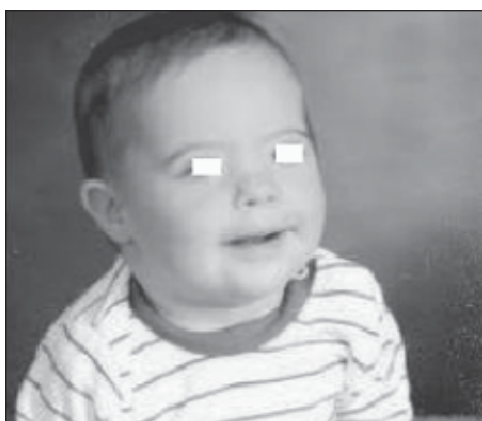

Fig.-1: 4 year old baby with Down syndrome and VSD.

Treatment: The diagnosis of the patient was Down syndrome with a VSD. The VSD was closed with PTFE patch. The patient was discharged after 7 days without any complication. and postoperative echocardiography showed normal biventricular function without residual VSD.

Case 2

Clinical presentation: R is a baby with Down Syndrome who is almost 5 months old, had been referred from Darussalam, Brunei to Institute Jantung Negara (IJN), Malaysia(MY) as a diagnosis of Down syndrome with large peri membranous VSD with inlet extension, pulmonary hypertension and transient Myeloproliferative disorder. She was born term, the 4th child on non-consanguineous parents. Her platelet counts from birth had been

persistently low (30-60 thousand) and blast cells consistently found on peripheral blood smear. Her hematological abnormalities (low platelet counts, rising white cell counts with peripheral blast cells and falling haemoglobin levels) remained during the first 4 months of life. Fortunately, this has resolved over the past few weeks.

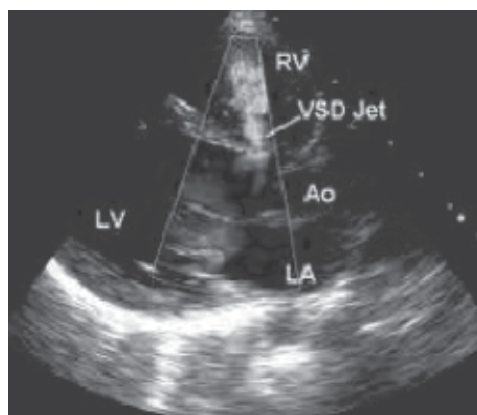


Fig.-2: Echocardiography showing perimembranous VSD

She had been admitted in hospital 3 times with lower respiratory tract infection. Since the last admission for bronchiolitis she had remained oxygen dependent. Now her lungs were found clear. She had severe failure to thrive despite dietary measures, her weight remained around 2.7 kg in the first 4 months of life and had improved recently and her current weight is 3.9 kg. In a cardiovascular examination, a pansystolic murmur, grade 4/6, best heard in the left 4th intercostal space.

Investigation: CXR showed cardiomegaly with plethoric lung fields. Echo cardiography showed (11 mm) large perimembranous VSD with inlet extension having left to right shunt, low velocity flow across the defect, biventricular dilatation, altered interventricular septal motion(fig;).

Treatment: Under all aseptic precaution, VSD closure performed by Dato' Azhari and his team. Patient remained in ventilator for 5 days and was discharged after ambulating with proper antibiotics, postural drainage and physiotherapy. Her echo showed no residual VSD, good left ventricular function, ejection fraction 60%, and chest X-ray showed clear lung fields.

Discussion:

First described in 1866, Down syndrome is a condition characterized by Trisomy of chromosome 21. Among all cases 95% are primary trisomy and 5% are translocation and mosaic forms (3% and 2% respectively)³. The frequency of presentation is one in 650 live births. Frequency in the general population is about 1%. Cardiac malformation is the main cause of mortality in the first 2 years of life.³

The prevalence of Down syndrome increased from 1.3 to 2.5 per 1000 live births showed in 20 years study⁶. Congenital heart defects reduce survival in Down syndrome patients by 72%. ASD and VSD in the early phases are associated with better survival rates than AVSD.³ However in last 20 years study showed survival in infants with Down syndrome with normal heart increased from 93 to 97% and in those with cardiovascular malformation from 78 to 90%.⁶

In Guatemala, a series showed 189 patients (54%) had congenital cardiac defect among 349 patients of Down syndrome, in 189 patient, 52 were VSD (27.5%).⁷

Other series in Mexico showed among 275 children, 160 had congenital heart disease (58%), the most frequent cardiopathies were ASD (58%), VSD and PDA (90%). Twenty five patients (15.7%) died from sepsis and cardiogenic shock.³ Two of our patients had respiratory tract infection and was controlled vigorously with antibiotics, physiotherapy and nebulization according to treatment protocol.

The children with congenital heart disease and Down syndrome have an unusually high pulmonary vascular resistance and a propensity for early development of damage⁴ to the pulmonary vascular bed. The first six months of life considered the best time for definite repair because of the progression of pulmonary vascular disease and atrioventricular valve regurgitation. Some patients with Down syndrome undergo successful repair even in their

second and others die of pulmonary hypertensive crisis even in their first six months of life.⁴

Vascular malformation of brain with Down syndrome has not been reported in the literature. Rajniti Prasad reported a child with Down syndrome with associated arterio venous malformation in the brain, who developed stroke and treated successfully.⁵

It always is important to obtain routine chromosomal study (Karyotype) for a child who has Down syndrome because it is critical for accurate recurrence risk counseling to separate the 95% of children who have Trisomy 21 due to non disjunction from the 2% to 3% who have a Robertsonian translocation involving chromosome 21, which can be inherited from a parent.¹

Conclusion:

The survival and quality of life have been improving in patients with Down syndrome due to early repair of congenital heart defects to halt sepsis, the prognosis of PAH and improvement in critical care facilities and vasodilator use.

References:

1. Emmanuel C, Cherian KM, Gopinath, An uncommon congenital cardiovascular malformation with Turners syndrome- A case report. *Int. J. Hum Igenet* 2004; 4(1): 71-73.
2. Anita EB, Lounne H. Congenital cardiac malformation in neonate: Isolated or Syndromic. *Neo Reviews* 2003; 4: 105-110.
3. Jesis R, Blanca , Magana J, Hach P. Heart malformation in children with Down syndrome. *Rev Esp cardiol* 2003; 56 (9): 894-899
4. Hanna Hasan Banja. Causes of Pulmonary arterial Hypertension in Down syndrome. *Bahrain Med Bull* 2009; 31(3): 1-6.
5. Prasad R, Singh UK, Mishra OP. Arterio venous malformation of brain with stroke in Down syndrome, a case report *BMJ* 2009; 7: 414-416.
6. Claire irving, Anna Basu, Seur Richmond, John Burnand Christopher warden. Twenty years Trends in prevalence and survival of Down Syndrome' *Eur J Hum Genet* 2008; 16: 1336-1340.
7. Vida V, Barnoya J, Larazabal L, Gaitan G. Congenital cardiac disease in children with down syndrome in Guatemala. *Cardiol Young* 2006;15(3): 286-290.