

# Real Time Three-Dimensional Echocardiography: Specific Indications and Incremental Value over Traditional Echocardiography

NC Nanda, AP Miller

**Abstract:**

*With the advent of live/real time three-dimensional (3D) echocardiography, 3D imaging as a research tool has evolved to a clinical mainstay. In this review, we discuss procedures for and application of 3D echocardiography to specific clinical questions. Although contemporary application remains primarily for assessment of left ventricular function, we review many more uses for this truly revolutionary technique.*

(CVJ 2008; 1(1) : 3-13)

## Introduction

Since its introduction in 1974<sup>1</sup>, three-dimensional echocardiography has offered great promise for its future application in determining chamber volumes and function, assessing valvular disorders, diagnosing congenital lesions, and evaluating cardiac masses. With the advent of newer echocardiographic systems using a full matrix array transducer, these applications are being realized. In this review, we will discuss three dimensional transthoracic echocardiography (3D TTE) techniques, indications, and proven value over conventional two-dimensional (2D) echocardiography.

## 3D TTE Techniques

A stumbling block for the advancement of 3D TTE was the development of a system capable of live/real time imaging. Efforts utilizing a rotational approach offered proof of principal, but suffered from cumbersome off-line data processing for volume rendering of sequentially acquired 2D images and never were embraced in routine clinical practice.<sup>2</sup> The advent of a full matrix array transducer (x4, Philips Medical Systems, Andover, MA) permitted simultaneous acquisition of a 3D pyramidal data set that could be cropped in any desired plane. These newer transthoracic echocardiography systems

(7500 and iE33, Philips Medical Systems, Andover, MA) were upgrades of existing 2D systems, now capable of real time/live 3D imaging. The broadband 2-4 MHz x4 phased array transducer contains 3600-6400 elements (each as minute as a hair) connected to 10,000 channels and over 150 mini circuit boards, which permit instantaneous 3D volume-rendered imaging as well as color Doppler and harmonic generation capabilities. Two major display settings are used in the current 3D TTE systems: narrow angled and wide-angled display. The narrow-angled display is capable of 60 by 30 degree steering and permits real time imaging. This setting offers the advantage of beat-to-beat imaging with simultaneous cropping in any plane, but suffers from coverage of a narrow region. The wide-angled display utilizes ECG gating over 7 cardiac cycles to obtain a combination of four 15 by 60 degree scans, resulting in a stable 60 by 60 degree pyramidal data set capable of containing the entire heart in most individuals. Acquisition of this display mode is best accomplished with a 5-7 second breathhold. Additionally, color Doppler can be added to either display setting, but lengthens acquisition time and narrows the sector/pyramidal data set. An examination protocol for 3D TTE has been published<sup>2</sup> and highlights the malleable nature of the 3D exam. In our laboratory, we routinely acquire

wide-angled data sets from the apical and left parasternal locations with and without color Doppler. In cases of aortic pathology, we also commonly acquire right parasternal and suprasternal data sets. Instantaneous cropping by the sonographer or physician using the auto-crop function ensures an adequate acquisition. After successful acquisitions, detailed image evaluation can be performed on-line using the cropping functions or the Q lab software. Overall, the 3D TTE evaluation adds just minutes to image interpretation and, as we will review in the remainder of this manuscript, incremental value over 2D TTE in answering many clinical questions. 3D TTE is really a revolutionary technique that is currently being used primarily for assessment of left ventricular mass and function, but offers wider utility in many other areas.

### **Assessment of Ventricular Volumes and Ejection Fractions**

The assessment of left ventricular (LV) function is a vital component of decision making in routine clinical cardiology practice. An unbiased and accurate LV ejection fraction (EF) critically affects decisions for medical or device management in patients with cardiac complaints. 2D echocardiography has been the primary noninvasive imaging modality to evaluate LV function for decades, but this technique can be inaccurate due to foreshortening, reliance on geometric modeling, or observer variability. In initial reports using rotational reconstruction methods, 3D echocardiography showed potential for overcoming these pitfalls.<sup>3-5</sup> These pioneering studies have led to the wider application of 3D TTE in the clinical echocardiography laboratory, with the advent of real time imaging coupled to image analysis software. Using real time 3D TTE data sets acquired on the Philips 7500 system and offline processing with 4D-LV Analysis software (TomTec Imaging systems, +Unterschleisheim, Germany), Sugeng et al demonstrated superior correlation for 3D TTE measurements of LVEF over cardiac CT measurements, when compared with cardiac MR measurements as a reference standard.<sup>6</sup> In 31 patients, 3D TTE measures of EF showed no significant bias (+0.3%;  $p=0.68$ ) when compared with cardiac MR measures, while cardiac CT significantly underestimated EF (by -2.8%).

Likewise, 3D TTE demonstrated superior volume measurements, underestimating end-diastolic and end-systolic volumes only slightly (by 5 and 6 mL, respectively), while cardiac CT significantly overestimated end-diastolic and end-systolic volumes (by 26 and 19 mL, respectively). 3D TTE did demonstrate its observer bias however, demonstrating roughly two-fold variability in interobserver measurements when compared with cardiac CT. Overall, this report, and others like it,<sup>7-9</sup> suggest that real time 3D TTE offers rapid and accurate assessment of LV volumes and EF, overcoming the 2D pitfalls of foreshortening and geometric modeling and performing at least as well as other noninvasive imaging modalities. In addition to assessment of LV volumes and function, 3D TTE has been applied to right ventricular (RV) volumes and function with success<sup>10,11</sup>. Prakasa et al studied 58 patients [23 with arrhythmogenic right ventricular dysplasia (ARVD), 20 first-degree relatives with no ARVD, 8 with idiopathic ventricular tachycardia, and 7 healthy volunteers] using the Philips 7500 or iE33 ultrasound system and an off-line TomTec workstation to assess RV volumes and EFs<sup>10</sup>. Compared with cardiac MR-derived measures as a reference standard, there were good correlations for real time 3D TTE-derived measures of RVEF ( $r=0.88$ ;  $p<0.001$ ), RV end-systolic volume ( $r=0.72$ ;  $p<0.0001$ ) and RV end-diastolic volume ( $r=0.50$ ;  $p<0.0001$ ), with intra- and interobserver differences for EF and end-diastolic volume of less than 3% and 3 mL, respectively. While this evaluation is not currently integrated into the Q lab analysis software, the potential for on-line RV analysis is appealing in its application to disease processes such as ARVD, but also as a prognostic index or indicator for surgical interventions in patients with other cardiac disorders.

### **Assessment of Wall Motion Abnormalities and Applications to Stress Echocardiography**

Dobutamine or treadmill stress echocardiography is useful for the prognostic stratification or diagnosis of coronary artery disease,<sup>12,13</sup> but there are important limitations including time-limited acquisition of multiple cross-sectional views of the LV to obtain images of all segments.<sup>14</sup> Acquisition of full volume LV images using real time 3D TTE may offer a solution to these difficulties, since

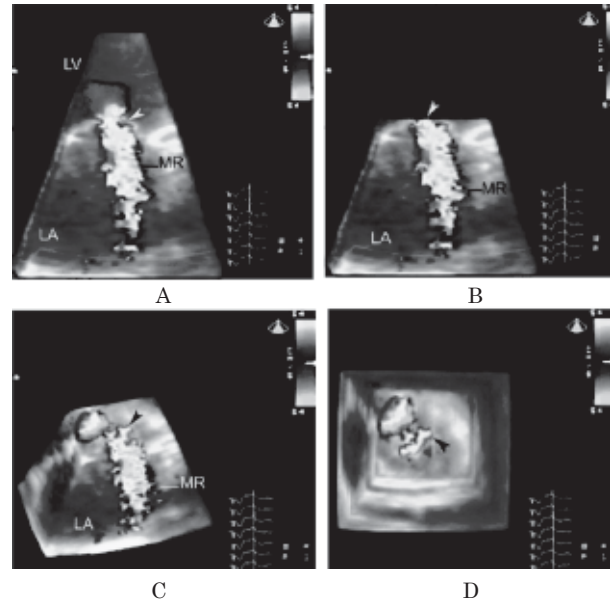
simultaneous and speedy acquisition of all LV segments is possible from a single apical view.<sup>15-17</sup>

In the first report of 3D TTE in dobutamine stress echocardiography (DSE), Matsumura et al compared results with standard 2D TTE and 201Thallium SPECT myocardial perfusion imaging.<sup>15</sup> In 56 consecutive patients, acquisition of 3D TTE images occurred quicker than with 2D TTE (29 v. 68 seconds) and with high success (92% and 89% at rest and peak stress, respectively). Wall motion analysis yielded similar results either by 2D or 3D TTE (accuracy of 82% and 84%, respectively) when compared to 201Thallium SPECT myocardial perfusion imaging as the reference standard. Subsequent reports have demonstrated added value for contrast-enhanced 3D TTE for chamber delineation during DSE,<sup>16,17</sup> and one report has demonstrated detection of perfusion abnormalities using contrast during DSE with 3D TTE in dogs.<sup>18</sup> As the technology advances, with improvements in frame rates and gated acquisition, 3D TTE offers promise in replacing 2D TTE during stress echocardiography studies.

### Assessment of Valvular Disorders

#### Regurgitation

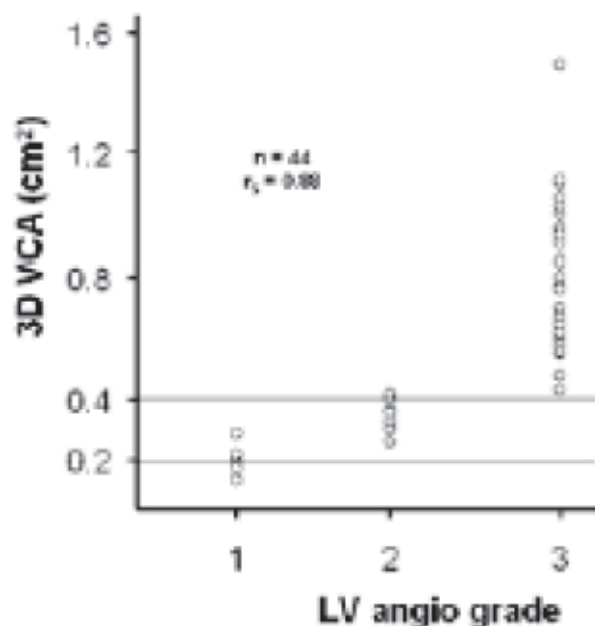
Due to the complex geometry involved, the impact of loading conditions on many standard parameters and the difficulty in measuring the small sizes of load-independent 4 parameters, precise quantification of regurgitant lesions has been challenging for the echocardiographer.<sup>19</sup> 3D TTE has been employed, even in its infancy,<sup>20</sup> as a technique to overcome these limitations. The current state of the art includes 3D TTE reports quantifying mitral, aortic, and tricuspid regurgitation with apparent incremental value over 2D methods.<sup>19-24</sup> By systematic cropping of the color Doppler 3D dataset, the echocardiographer can precisely identify the vena contracta (the narrowest portion of the regurgitant jet) using the anterior/posterior planes, and then obtain a true short axis view by cropping in a plane that is exactly perpendicular to the jet (Figure 1). Planimetered areas of the vena contracta have now been validated against other techniques as robust standards for regurgitation grading.<sup>22-24</sup>



**Fig.-1:** Live three-dimensional color Doppler transthoracic echocardiographic technique for assessment of vena contracta area. Three-dimensional color Doppler data set showing mitral regurgitation (MR, A) is cropped from top to the level of the vena contracta (arrowhead, B) and tilted to view it en face (C, D). The vena contracta is then planimetered by copying onto a videotape. LA = left atrium; LV – left ventricle. (Published with permission from Khanna D, et al: Quantification of mitral regurgitation by live three-dimensional transthoracic echocardiographic measurements of vena contracta area. Blackwell Publishing, Echocardiography 2004; 21: 737-743, Figure 2A-D)

Assessment of mitral regurgitation (MR) with 3D TTE was first demonstrated using the rotational method in 30 patients by Yao et al and demonstrated added diagnostic yield in 70% of the patients studied.<sup>20</sup> The contemporary foundation for 3D TTE assessment of MR was reported by Khanna et al,<sup>22</sup> in which comparisons were made to 2D TTE and left ventriculography in 44 consecutive patients with varying degrees of MR. Assessment by 3D TTE of vena contracta area (VCA) in a short axis plane perpendicular to and directly across the narrowest portion of the early regurgitant jet yielded a parameter that agreed best with angiographic grading, appearing to outperform 2D TTE measures of regurgitant jet area and vena contracta width. Results identified a grading scheme for MR, such that VCAs of 0.2 and 0.4 cm<sup>2</sup> divided mild moderate and moderate-severe grades, respectively (Figure 2).

These results are buttressed by the report of another independent laboratory demonstrating favorable comparisons with proximal isovelocity surface area (PISA) measures<sup>25</sup> and by a comprehensive review of MR assessment.<sup>19</sup>

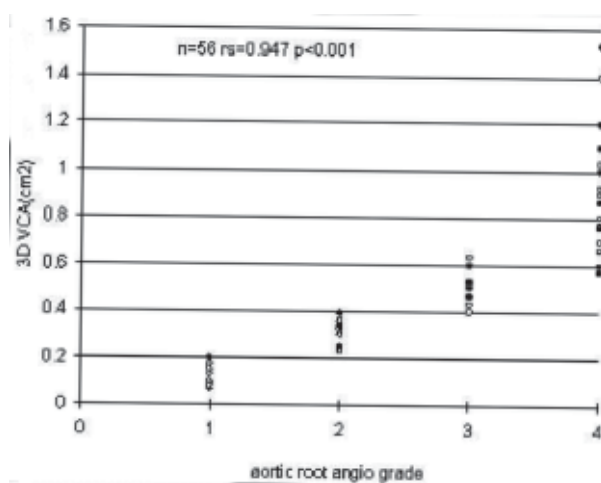


**Fig.-2:** Mitral regurgitation vena contracta area by live three-dimensional color Doppler transthoracic echocardiography (3D VCA) correlated with left ventricular angiographic (LV angio) assessment. (Published with permission from Khanna D, et al: Quantification of mitral regurgitation by live three-dimensional transthoracic echocardiographic measurements of vena contracta area. Blackwell Publishing, *Echocardiography* 2004; 21: 737-743, Figure 3)

Usefulness of 3D TTE has been likewise demonstrated for assessment of aortic regurgitation (AR) by quantification of VCA.<sup>23</sup> In 56 consecutive patients studied by 3D TTE, VCA of <0.2, 0.2-0.4, 0.4-0.6, and >0.6 cm<sup>2</sup> accurately predicted grades I, II, III, and IV AR, respectively, when assessed by aortography and at surgery (Figure 3). This 3D TTE measure added value beyond 2D TTE assessment of vena contracta width and 3D TTE correctly identified the pathological diagnoses of endocarditis and bicuspid aortic valves in involved cases. Since this technique can accurately characterize a measure of AR that is independent of load and

eccentricity, quantification of VCA with 3D TTE is employed routinely in the assessment of AR and MR in our laboratory.

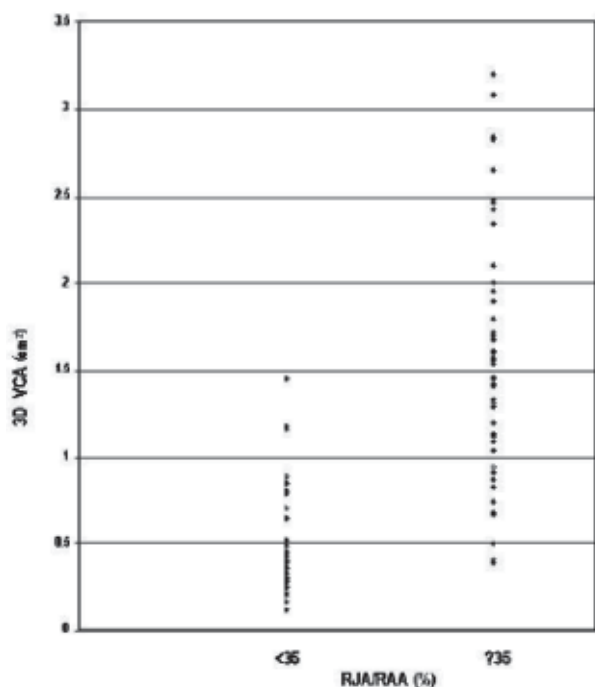
Most recently, we have experienced in assessing tricuspid regurgitation (TR) using the VCA parameter from 3D TTE.<sup>24</sup> In 93 consecutive patients who underwent 2D and 3D TTE with at least mild TR, we found good correlation with and acceptable separation for VCA of <0.5cm<sup>2</sup> for grade I, 0.5-0.75cm<sup>2</sup> for grade II, and >0.75 cm<sup>2</sup> for grade III TR as compared with the 2D measures of regurgitant jet area and vena contracta width (Figure 4). Torrential TR was defined by VCA>1.0 cm<sup>2</sup>, since this threshold had a very high positive predictive value (93%) for severe TR in our series.



**Fig.-3:** Shows the correlation between live three-dimensional transthoracic color Doppler echocardiographic measurements of aortic regurgitation vena contracta (3DVCA) and aortic root angiographic grading. The open circles denote patients with eccentric aortic regurgitant jets; closed circles denote central jets. (Reproduced with permission from Fang L et al: Assessment of aortic regurgitation by live three-dimensional transthoracic echocardiographic measurements of vena contracta area: Usefulness and validation. Blackwell Publishing, *Echocardiography* 2005; 22: 775- 781. Figure 2).

Demonstrating the incremental value of 3D TTE, we found that the vena contracta geometry was complex in most patients and would vary significantly if assessed by the simple 2D measure of width, depending upon the angle and orientation of the 2D plane (Figure 5). Likewise, we have

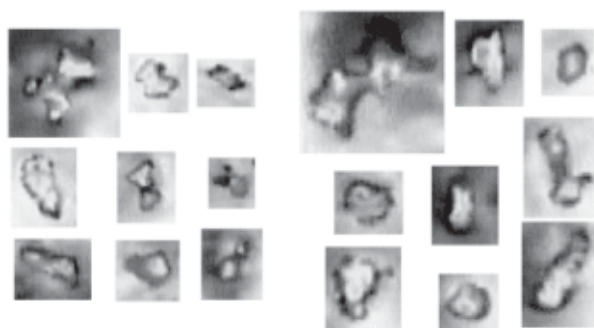
experience in cropping through the flow acceleration region and have found similar complex geometries that are not representative of symmetric hemispheric shells, suggesting that PISA measurements may not be as robust as a true 3D assessment.



**Fig.-4:** Shows percent ratio of regurgitant jet area (RJA) to right atrial area (RAA) of less than 35% and 35% or more plotted against three-dimensional (3D) vena contracta area (VCA). (Reproduced with permission from: Velayudhan DE et al: Quantification of tricuspid regurgitation by live three-dimensional transthoracic echocardiographic measurements of vena contracta area. Blackwell Publishing, Echocardiography 2006; 23: 793-800. Figure 4)

#### Stenosis

Assessment of the flow-limiting orifice with Doppler has been criticized, and is especially fraught with error when the stenotic orifice is tubular, the leaflets are domed, or there is a narrow inflow or outflow tract, due to pressure recovery principles. In the setting of catheter balloon treatment for valvar stenosis, Doppler measures are particularly misleading due to changes in loading conditions.<sup>26</sup> Using 2D TTE, attempts at direct measurements of the open orifice are complicated by the inability



**Fig.-5:** Live three-dimensional transthoracic echocardiographic assessment of tricuspid valve (TV) regurgitation. A,B. Depict complex geometric shapes of the vena contracta in different patients with TV regurgitation. (Reproduced with permission from: Velayudhan DE et al: Quantification of tricuspid regurgitation by live three-dimensional transthoracic echocardiographic measurements of vena contracta area. Blackwell Publishing, Echocardiography 2006; 23: 793-800. Figure 1E-F).

to ensure that the 2D plane is through the actual flow-limiting orifice, or at the leaflet tips. For these reasons, 3D TTE has been employed as a tool to directly and accurately measure valvar stenosis. The feasibility of assessing normal, sclerotic and stenotic aortic valves was demonstrated with early 3D echocardiographic techniques.<sup>27</sup> With the advent of the full matrix-array transducer and live/real time 3D TTE system, this prior cumbersome and time-consuming technique is now reaching clinical application.<sup>28-30</sup> By cropping the 3D dataset, the echocardiographer can rapidly and accurately assess aortic valvemorphology and orifice area without Doppler, aligning the 3D plane exactly parallel to the aortic valve orifice in the short-axis plane. Cropping above and below the aortic valve can identify the discrete area of stenosis and is useful in characterizing subvalvular stenosis.<sup>28</sup> For aortic valve pathology, 3D TTE assessment offers improved diagnostic accuracy over 2D TTE and multiplane transesophageal echocardiography (TEE) in a series reported by us.<sup>29</sup> Additionally, in complex patients with sub/supravalvar and aortic valve pathology who have two or more areas of stenosis in which continuous wave Doppler is particularly unreliable, 3D TTE permits direct visualization and planimetry of each stenotic orifice, improving clinical decision making.<sup>29, 30</sup>

2D TTE and conventional Doppler have been traditionally used in the assessment of mitral stenosis. Using 2D methods, planimetry of the mitral orifice at the leaflet tips overcomes many of the Doppler pitfalls and has been shown to provide a reliable estimate of MS severity when performed carefully. With 3D TTE, a pyramidal section of the heart can be acquired, containing the whole mitral valve apparatus. From this dataset, cropping can ensure that measurements of the mitral valve orifice are taken exactly parallel to and at the leaflet tips (Figure 6).<sup>31</sup> In a series of patients considered for mitral valve catheter balloon treatment using catheter measurements of mitral valve area as a reference standard, we found improved accuracy for the 3D TTE measurement of orifice area before and after the procedure as compared with 2D TTE planimetry or pressure half-time methods.<sup>31</sup> Others have described similar 3D TTE methods with validation against 2D TTE measurements and demonstration of clinical usefulness.<sup>32, 33</sup>

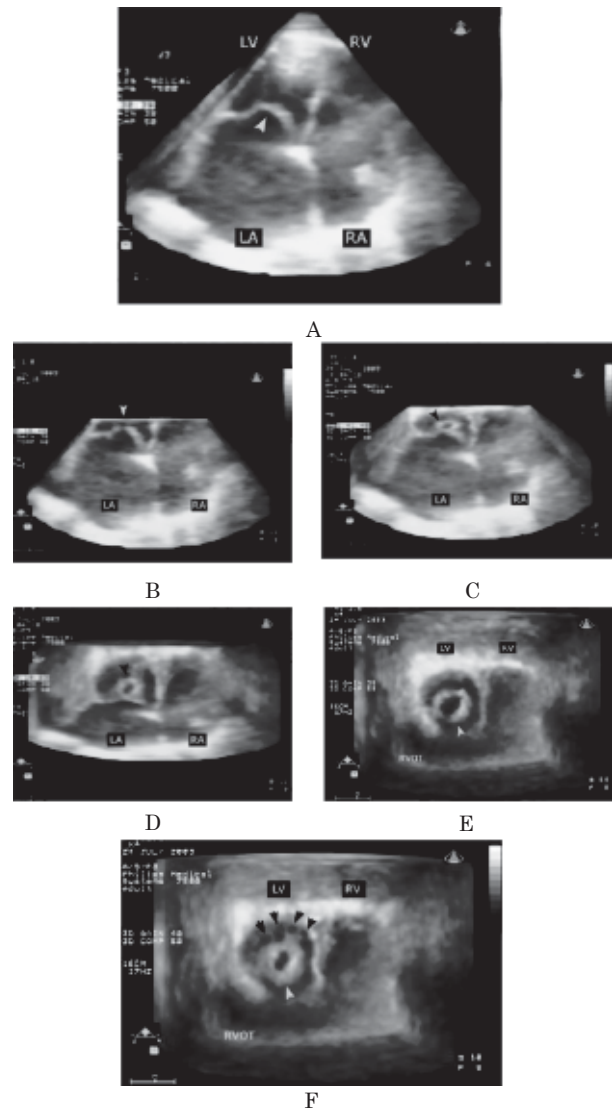
Demonstrating wider application of this principle, others have applied systematic cropping and orifice planimetry to the tricuspid valve, obtaining short axis images not usually possible with traditional 2D TTE.<sup>34</sup>

#### *Prosthetic Valves*

Assessment of prosthetic valve restriction and regurgitation is another problematic area for Doppler and traditional 2D echocardiography. Doppler gradients do not correlate with orifice areas in normally functioning valves,<sup>35</sup> and often it is difficult to visualize metallic leaflet motion. Recent reports and our recent experience suggest that 3D TTE will offer incremental value in determining integrity of prosthetic valve function.<sup>33</sup>

#### *Assessment of Congenital Heart Disease*

The ability to crop the 3D dataset in any direction permits en face imaging of defects and systematic tracking of conduits not possible with traditional 2D TTE planes. Hence, in patients with complex congenital heart disease prior to operative interventions, 3D TTE is particularly useful. 3D TTE has been employed in the evaluation of most major congenital lesions for over a decade,<sup>36</sup> and recently even in the evaluation of the live fetus in utero.<sup>37</sup>

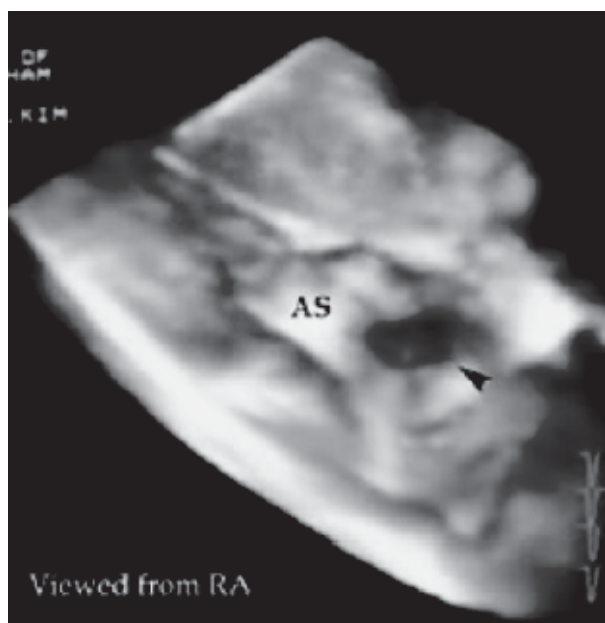


**Fig-6:** Live three-dimensional transthoracic echocardiography (3D TTE) in mitral stenosis. A-D. A useful and easy technique is to crop an apical four-chamber section at the tip of the mitral valve and tilt or rotate the image toward the examiner 10 to view the flow limiting mitral orifice (arrowhead) in short axis. E. Section taken at the base of the mitral valve (using apical four-chamber view) shows a much larger orifice (arrowhead). F. Demonstrates subvalvular chordal stenosis. The arrows point to multiple small openings produced by chordal fusion. The cumulative area of the openings measured 0.5 cm<sup>2</sup>, indicative of severe chordal stenosis. LA = left atrium; LV = left ventricle; RA = right atrium; RV = right ventricle; RVOT = right ventricular outflow tract. (Reproduced with permission from: Singh V et al: Live three-dimensional echocardiographic assessment of mitral stenosis. Blackwell Publishing, Echocardiography 2003; 20: 743-750. Figure 3A-F)

With the introduction of catheter-based techniques for closure of atrial and ventricular septal defects (ASD, VSD), assessment of defect anatomy and size has become more clinically important. In a series of 12 patients with ASD, we found that live 3D TTE measures of defect size (diameter and circumference) agreed well with 3D TEE and sizing balloon measurements.<sup>38</sup> In calculating areas and correlating with sizing balloon or occluder areas, we found the best correlation for an area that is calculated from the circumference or a “stretched diameter.” Important to the interventionalist, 3D TTE is able to characterize the tissue rims around the ASD, which can determine feasibility for percutaneous closure (Figure 7).

In a similar manner, measurements of VSD with 3D TTE can be clinically useful.

We reported our experience in 12 patients who underwent surgical repair of VSD and noted agreement between 3D TTE, 3D TEE, and surgical measurements.<sup>39</sup>



**Fig.-7:** Live three-dimensional transthoracic echocardiographic (3D TTE) assessment of atrial septal defect. Arrowhead points to a large secundum atrial septal defect visualized from right atrial (RA) aspect. AS = atrial septum. (Reproduced with permission from: Mehmood F et al: Usefulness of live threedimensional transthoracic echocardiography in the characterization of atrial septal defects in adults. Blackwell Publishing, Echocardiography 2004; 21: 707-713. Figure 1A)

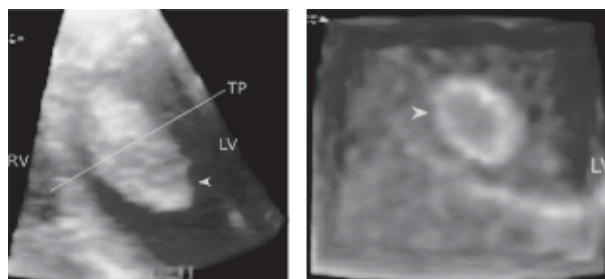
Assessment of atrioventricular septal defects has also been reported with 3D imaging.<sup>40-42</sup> The ability to produce an en face image or to reconstruct a surgical view can be an important tool in planning surgical correction of these defects.

Multiple case reports exist, demonstrating feasibility and usefulness of 3D TTE in the study of congenital lesions. Clinical entities such as subaortic stenosis,<sup>28</sup> patent ductus arteriosus,<sup>43</sup> transposition of the great arteries,<sup>36,44</sup> cor triatriatum,<sup>45</sup> cleft mitral valve,<sup>46</sup> and Ebstein’s anomaly<sup>47,48</sup> have been assessed with 3D echocardiography.

#### *Assessment of Cardiac Masses*

Accurate diagnosis and description of cardiac masses, which is necessary for surgical consideration, can be achieved with 3D TTE. As proof of principle, we have reported our experience using 3D TEE in diagnosing and accurately defining characteristics of left atrial myxomas, aortic and mitral valve fibroelastomas.<sup>49, 50</sup> With the newer application of live 3D TTE, we have found incremental value over 2D TTE in differentiating myxomas from hemangiomas, since the internal structure can be dissected by cropping through the tumors.<sup>51</sup> Isolated echolucent areas denoting hemorrhage or necrosis can be visualized in myxomas, while the vascular structure of the hemangioma can be appreciated with 3D TTE. Additionally, we have reported the value of 3D TTE in deciphering the attachment point for tumors. A pulmonic valve fibroelastoma could be better described by 3D than by 2D TTE in a recent report.<sup>52</sup>

In considering the differential diagnosis of cardiac masses, 3D TTE, as compared with 2D TTE, offers better description of and improved ability to exclude cardiac thrombus.<sup>53</sup> By rapidly cropping a single data set including the entirety of the left ventricle, thrombi can be excluded. Additionally, when present, 3D TTE can accurately localize attachment points, describe mobility (and hence likelihood of embolization) and delineate presence or absence of focal lysis within thrombi, which may have potential therapeutic and prognostic implications (Figure 8).<sup>53, 54</sup> Additionally 3D TTE has been used to diagnose right atrial and innominate vein thrombosis as reported in the literature.<sup>55, 56</sup>



**Fig-8:** Morphological assessment of left ventricular thrombus by live three-dimensional transthoracic echocardiography. A,B: Transverse plane (TP) section at mid-thrombus level showing clot lysis. Arrowhead points to the thrombus. LV = left ventricle; RV = right ventricle. (Published with permission from: Sinha A et al: Morphological assessment of left ventricular thrombus by live three-dimensional transthoracic echocardiography. *Echocardiography* 2004; 21: 649-655. Figure 1F-G)

In our laboratory we have found particular utility in using 3D TTE to evaluate the left atrial appendage and other cardiac chambers to “rule out cardiac source of embolus” in patients with stroke. Agoston et al evaluated their experience with this technique in 204 consecutive patients referred for 2D TTE or TEE.<sup>57</sup> They found that the left atrial appendage could be adequately visualized in 68.1% of patients studied by 3D TTE and in 45.5% by 2D TTE. In their series only 8 patients had left atrial appendage thrombus by TEE, but live 3D TTE correctly identified thrombus in all of these. We commonly utilize 2D TTE and 3D TTE in tandem in our laboratory to evaluate the left atrial appendage. Our experience would suggest that while the left atrial appendage can be visualized well with 2D TTE in many patients, 3D TTE offers improved confidence in excluding thrombus since the entirety of the left atrial appendage can be sectioned.

#### **Assessment of Vascular Disorders: Dissection and Coronary Arteries**

Rapid and accurate diagnosis of acute aortic dissection is vital since mortality can be as high as 1 to 2% per hour during the first 2 days.<sup>58</sup> Many of these patients are clinically unstable and can be challenging for TEE study by the echocardiographer. In patients with adequate acoustic windows, 3D TTE can be used to make the diagnosis of aortic dissection and facilitate surgical decision-making.<sup>59, 60</sup> In our

initial series, we reported 10 patients with acute aortic dissection in which 3D TTE was diagnostic.<sup>60</sup> In 2 of 6 patients in which it was requested, TEE could be averted due to the confidence in the 3D TTE diagnosis. For these reasons, we have found that performing a 3D TTE, while preparing for a TEE in patients with suspected aortic dissection, is a useful clinical exercise.

Since the entirety of the aortic root and surrounding epicardium can be captured in a single 3D dataset, 3D TTE can be useful in interrogating patency and anatomy of the proximal and mid coronary arteries.<sup>61-63</sup> Either by direct visualization or by color Doppler “angiography,” we demonstrated feasibility of assessing the coronary arteries to the level of the first septal perforator, the first marginal branch, and the proximal right coronary artery in one report.<sup>61</sup> Additionally, 3D TTE complements 2D TTE in assessing ostia locations for the coronaries and has been used to locate anomalous coronary arteries.<sup>62, 63</sup>

#### **Assessment of Cardiomyopathies**

In the assessment of cardiomyopathies, 3D TTE has found a place in determining synchrony and diagnosing left ventricular noncompaction. Contemporary management of congestive heart failure due to systolic impairment involves determination of intraventricular synchrony. Tissue Doppler imaging and M-mode are clinically validated for the assessment of dyssynchrony, with evaluation of the basal segments of the left ventricle.<sup>64</sup> 3D TTE offers a more holistic view with individual segment analysis built into the Q lab software system and early publications suggesting utility in the dyssynchrony evaluation.<sup>64</sup>

Noncompaction is a World Health Organization unclassified cardiomyopathy that results from a disorder of endomyocardial morphogenesis characterized by the echocardiographic findings of deep recesses between multiple, prominent myocardial trabeculations, with a noncompacted: compacted ratio > 2.65. Since this disorder occurs in a segmental distribution, usually distributed from the apex, assessment with 3D TTE provides accurate determination of the extent of involvement by systematic cropping of an apically acquired dataset, and delineation of this clinical entity from primary or metastatic tumors.<sup>66, 67</sup> Noncompaction has



varied clinical presentations and natural histories,<sup>65</sup> such that it is hopeful an echocardiographic parameter might better explain implications of this diagnosis.

### Conclusion

The rapid and accurate characterization of chamber volumes and function, valvular regurgitation and stenosis, and congenital and acquired lesions makes the recently introduced live/real time 3D TTE exam a powerful clinical tool. Numerous reports have already validated its application in routine clinical practice, often as a replacement for other non-invasive or invasive imaging techniques. As familiarity with 3D TTE grows and the technology continues to evolve, it should reach every corner of the imaging world.

### References:

- Dekker DL, Piziali RL, Dong E, Jr. A system for ultrasonically imaging the human heart in three dimensions. *Comput Biomed Res* 1974; 7(6): 544-53.
- Nanda NC, Kisslo J, Lang R, et al. Examination protocol for three-Dimensional echocardiography. *Echocardiography* 2004; 21(8): 763-8.
- Ghosh A, Nanda NC, Maurer G. Three-dimensional reconstruction of echocardiographic images using the rotation method. *Ultrasound in medicine & biology* 1982; 8(6): 655-61.
- Gopal AS, Schnellbaecher MJ, Shen Z, Boxt LM, Katz J, King DL. Freehand three-dimensional echocardiography for determination of left ventricular volume and mass in patients with abnormal ventricles: comparison with magnetic resonance imaging. *J Am Soc Echocardiogr* 1997; 10(8): 853-61.
- Mele D, Maehle J, Pedini I, Alboni P, Levine RA. Three-dimensional echocardiographic reconstruction: description and applications of a simplified technique for quantitative assessment of left ventricular size and function. *The American Journal of Cardiology* 1998; 81(12A): 107G-10G.
- Sugeng L, Mor-Avi V, Weinert L, et al. Quantitative assessment of left ventricular size and function: side-by-side comparison of real-time three-dimensional echocardiography and computed tomography with magnetic resonance reference. *Circulation* 2006; 114(7): 654-61.
- Kuhl HP, Schreckenberg M, Rulands D, et al. High-resolution transthoracic realtime three-dimensional echocardiography: quantitation of cardiac volumes and function using semi-automatic border detection and comparison with cardiac magnetic resonance imaging. *Journal of the American College of Cardiology* 2004; 43(11): 2083-90.
- Caiani EG, Corsi C, Zamorano J, et al. Improved semiautomated quantification of left ventricular volumes and ejection fraction using 3-dimensional echocardiography with a full matrix-array transducer: comparison with magnetic resonance imaging. *J Am Soc Echocardiogr* 2005; 18(8): 779-88.
- Jacobs LD, Salgo IS, Goonewardena S, et al. Rapid online quantification of left ventricular volume from real-time three-dimensional echocardiographic data. *Eur Heart J* 2006; 27(4): 460-8.
- Prakasa KR, Dalal D, Wang J, et al. Feasibility and variability of three dimensional echocardiography in arrhythmogenic right ventricular dysplasia/cardiomyopathy. *The American Journal of Cardiology* 2006; 97(5): 703-9.
- Chen G, Sun K, Huang G. In vitro validation of right ventricular volume and mass measurement by real-time three-dimensional echocardiography. *Echocardiography* 2006; 23(5): 395-9.
- Sawada SG, Segar DS, Ryan T, et al. Echocardiographic detection of coronary artery disease during dobutamine infusion. *Circulation* 1991; 83: 1605-14.
- Chuah S-C, Pellikka PA, Roger VL, McCully RB, Seward JB. Role of Dobutamine stress echocardiography in predicting outcome in 860 patients with known or suspected coronary artery disease. *Circulation* 1998; 97: 1474-80.
- Popp R, Agatston A, Armstrong W, et al. Recommendations for training in performance and interpretation of stress echocardiography. Committee on Physician Training and Education of the American Society of Echocardiography. *J Am Soc Echocardiogr* 1998; 11(1): 95-6.
- Matsumura Y, Hozumi T, Arai K, et al. Non-invasive assessment of myocardial ischaemia using new real-time three-dimensional dobutamine stress echocardiography: comparison with conventional two-dimensional methods. *Eur Heart J* 2005; 26(16): 1625-32.
- Pulerwitz T, Hirata K, Abe Y, et al. Feasibility of using a real-time 3-dimensional technique for contrast dobutamine stress echocardiography. *J Am Soc Echocardiogr* 2006; 19(5): 540-5.
- Takeuchi M, Otani S, Weinert L, Spencer KT, Lang RM. Comparison of contrastenhanced real-time live 3-dimensional dobutamine stress echocardiography with contrast 2-dimensional echocardiography for detecting stress-induced wall-motion abnormalities. *J Am Soc Echocardiogr* 2006; 19(3): 294-9.
- Chen LX, Wang XF, Nanda NC, et al. Real-time three-dimensional myocardial contrast echocardiography in assessment of myocardial perfusion defects. *Chinese Medical Journal* 2004; 117(3): 337-41.

19. Khanna D, Miller AP, Nanda NC, Ahmed S, Lloyd SG. Transthoracic and transesophageal echocardiographic assessment of mitral regurgitation severity: usefulness of qualitative and semiquantitative techniques. *Echocardiography* 2005; 22(9): 748-69.
20. Yao J, Masani ND, Cao QL, Nikuta P, Pandian NG. Clinical application of transthoracic volume-rendered three-dimensional echocardiography in the assessment of mitral regurgitation. *The American Journal of Cardiology* 1998; 82(2): 189-96.
21. Anayiotos AS, Smith BK, Kolda M, Fan P, Nanda NC. Morphological evaluation of a regurgitant orifice by 3-D echocardiography: applications in the quantification of valvular regurgitation. *Ultrasound in Medicine & Biology* 1999; 25(2): 209-23.
22. Khanna D, Vengala S, Miller AP, et al. Quantification of mitral regurgitation by live three-dimensional transthoracic echocardiographic measurements of vena contracta area. *Echocardiography* 2004; 21(8): 737-43.
23. Fang L, Hsiung MC, Miller AP, et al. Assessment of aortic regurgitation by live three-dimensional transthoracic echocardiographic measurements of vena contracta area: usefulness and validation. *Echocardiography* 2005; 22(9): 775-81.
24. Velayudhan DE, Brown TM, Nanda NC, et al. Quantification of tricuspid regurgitation by live three-dimensional transthoracic echocardiographic measurements of vena contracta area. *Echocardiography* 2006; 23: 793-800.
25. Watanabe N, Ogasawara Y, Yamaura Y, et al. Geometric differences of the mitral valve tenting between anterior and inferior myocardial infarction with significant ischemic mitral regurgitation: quantitation by novel software system with transthoracic real-time three-dimensional echocardiography. *J Am Soc Echocardiogr* 2006; 19(1): 71- 5.
26. Reid CL, Rahimtoola SH. The role of echocardiography/Doppler in catheter balloon treatment of adults with aortic and mitral stenosis. *Circulation* 1991; 84 (Suppl 3) : I240-9.
27. Nanda NC, Roychoudhury D, Chung SM, Kim KS, Ostlund V, Klas B. Quantitative assessment of normal and stenotic aortic valve using transesophageal three-dimensional echocardiography. *Echocardiography* 1994; 11(6): 617-25.13.
28. Agrawal GG, Nanda NC, Htay T, Dod HS, Gandhari SR. Live three-dimensional transthoracic echocardiographic identification of discrete subaortic membranous stenosis. *Echocardiography* 2003; 20(7): 617-9.
29. Vengala S, Nanda NC, S H, et al. Images in geriatric cardiology. Usefulness of live three-dimensional transthoracic echocardiography in aortic valve stenosis evaluation. *The American Journal of Geriatric Cardiology* 2004; 13(5): 279-84.
30. Rajdev S, Nanda NC, Patel V, Mehmood F, Singh A, McGiffin DC. Live/real-time three-dimensional transthoracic echocardiographic assessment of combined valvar and supra-valvar aortic stenosis. *The American Journal of Geriatric Cardiology* 2006; 15(3): 188-90.
31. Singh V, Nanda NC, Agrawal G, et al. Live three-dimensional echocardiographic assessment of mitral stenosis. *Echocardiography* 2003; 20(8): 743-50.
32. Sugeng L, Weinert L, Lammertin G, et al. Accuracy of mitral valve area measurements using transthoracic rapid freehand 3-dimensional scanning: comparison with noninvasive and invasive methods. *J Am Soc Echocardiogr* 2003; 16(12): 1292-300.
33. Sugeng L, Coon P, Weinert L, et al. Use of real-time 3-dimensional transthoracic echocardiography in the evaluation of mitral valve disease. *J Am Soc Echocardiogr* 2006; 19(4): 413-21.
34. Faletra F, La Marchesina U, Bragato R, De Chiara F. Three dimensional transthoracic echocardiography images of tricuspid stenosis. *Heart (British Cardiac Society)* 2005; 91(4): 499.
35. Keser N, Nanda NC, Miller AP, et al. Hemodynamic evaluation of normally functioning Sulzer Carbomedics prosthetic valves. *Ultrasound Med Biol* 2003; 29(5): 649- 57.
36. Salustri A, Spitaels S, McGhie J, Vletter W, Roelandt JR. Transthoracic three-dimensional echocardiography in adult patients with congenital heart disease. *Journal of the American College of Cardiology* 1995; 26(3): 759-67.
37. Maulik D, Nanda NC, Singh V, et al. Live three-dimensional echocardiography of the human fetus. *Echocardiography* 2003; 20(8): 715-21.
38. Mehmood F, Vengala S, Nanda NC, et al. Usefulness of live three-dimensional transthoracic echocardiography in the characterization of atrial septal defects in adults. *Echocardiography* 2004; 21(8): 707-13.
39. Mehmood F, Miller AP, Nanda NC, et al. Usefulness of live/real time three-dimensional transthoracic echocardiography in the characterization of ventricular septal defects in adults. *Echocardiography* 2006; 23(5): 421-7.
40. Singh A, Romp RL, Nanda NC, et al. Usefulness of live/real time three-dimensional transthoracic echocardiography in the assessment of atrioventricular septal defects. *Echocardiography* 2006; 23(7): 598-608.
41. Hlavacek AM, Crawford FA, Jr., Chessa KS, Shirali GS. Real-time three-dimensional echocardiography is useful in the evaluation of patients with atrioventricular septal defects. *Echocardiography* 2006; 23(3): 225-31.
42. Miller AP, Nanda NC, Aaluri S, et al. Three-dimensional transesophageal echocardiographic demonstration of anatomical defects in AV septal defect patients presenting for reoperation. *Echocardiography* 2003; 20(1): 105-9.

43. Sinha A, Nanda NC, Khanna D, et al. Live three-dimensional transthoracic echocardiographic delineation of patent ductus arteriosus. *Echocardiography* 2004; 21(5): 443-8.
44. Ahmed S, Nekkanti R, Nanda NC, Yousif AM. Three-dimensional transesophageal echocardiographic demonstration of intraatrial baffle obstruction. *Echocardiography* 2003; 20(7): 683-6.
45. Jacobs A, Weinert LC, Goonewardena S, Gomberg-Maitland M, Lang RM. Three-dimensional transthoracic echocardiography to evaluate cor triatriatum in the adult. *J Am Soc Echocardiogr* 2006; 19(4): 468 e1-4.
46. Sinha A, Kasliwal RR, Nanda NC, et al. Live three-dimensional transthoracic echocardiographic assessment of isolated cleft mitral valve. *Echocardiography* 2004; 21(7): 657-61.
47. Patel V, Nanda NC, Rajdev S, et al. Live/real time three-dimensional transthoracic echocardiographic assessment of Ebstein's anomaly. *Echocardiography* 2005; 22(10): 847-54.
48. Ahmed S, Nanda NC, Nekkanti R, Pacifico AD. Transesophageal threedimensional echocardiographic demonstration of Ebstein's anomaly. *Echocardiography* 2003; 20(3): 305-7.
49. Ahmed S, Nanda NC, Miller AP, et al. Volume quantification of intracardiac mass lesions by transesophageal three-dimensional echocardiography. *Ultrasound in medicine & biology* 2002; 28(11-12): 1389-93.
50. Dod HS, Nanda NC, Pacifico AD, et al. Images in geriatric cardiology. Definitive diagnosis of aortic valve papillary fibroelastoma by three-dimensional transesophageal echocardiography. *The American journal of geriatric cardiology* 2003; 12(1): 60-2.
51. Mehmood F, Nanda NC, Vengala S, et al. Live three-dimensional transthoracic echocardiographic assessment of left atrial tumors. *Echocardiography* 2005; 22(2): 137- 43.
52. Singh A, Miller AP, Nanda NC, Rajdev S, Mehmood F, Duncan K. Papillary fibroelastoma of the pulmonary valve: Assessment by live three-dimensional transthoracic echocardiography. *Echocardiography* 2006; 23: In Press.
53. Duncan K, Nanda NC, Foster WA, Mehmood F, Patel V, Singh A. Incremental value of live/real time three-dimensional transthoracic echocardiography in the assessment of left ventricular thrombi. *Echocardiography* 2006; 23(1): 68-72.
54. Sinha A, Nanda NC, Khanna D, et al. Morphological assessment of left ventricular thrombus by live three-dimensional transthoracic echocardiography. *Echocardiography* 2004; 21(7): 649-55.
55. Upendram S, Nanda NC, Vengala S, et al. Live three-dimensional transthoracic echocardiographic assessment of thrombus in the innominate veins and superior vena cava utilizing right parasternal and supraclavicular approaches. *Echocardiography* 2005; 22(5): 445-9.
56. Upendram S, Nanda NC, Mehmood F, et al. Images in geriatric cardiology: live three-dimensional transthoracic echocardiographic assessment of right atrial thrombus. *The American journal of geriatric cardiology* 2004; 13(6): 330-1.
57. Agoston I, Xie T, Tiller FL, Rahman AM, Ahmad M. Assessment of left atrial appendage by live three-dimensional echocardiography: early experience and comparison with transesophageal echocardiography. *Echocardiography* 2006; 23(2): 127-32.
58. Pretre R, Von Segesser LK. Aortic dissection. *Lancet* 1997; 349(9063): 1461-4.
59. Yelamanchili P, Nanda NC, Patel V, Bogabathina H, Baysan O. Definitive diagnosis of descending thoracic aortic dissection by real time/live three-dimensional transthoracic echocardiography. *Echocardiography* 2006; 23(2): 158-61.
60. Htay T, Nanda NC, Agrawal G, Ravi BS, Dod HS, McGiffin D. Live threedimensional transthoracic echocardiographic assessment of aortic dissection. *Echocardiography* 2003; 20(6): 573-7.
61. Vengala S, Nanda NC, Agrawal G, et al. Live three-dimensional transthoracic echocardiographic assessment of coronary arteries. *Echocardiography* 2003; 20(8): 751- 4.
62. Ilgenli TF, Nanda NC, Sinha A, Khanna D. Live three-dimensional transthoracic echocardiographic assessment of anomalous origin of left coronary artery from the pulmonary artery. *Echocardiography* 2004; 21(6): 559-62.
63. Mehta D, Nanda NC, Vengala S, Mehmood F, Taylor J. Live three-dimensional transthoracic echocardiographic demonstration of coronary artery to pulmonary artery fistula. *The American Journal of Geriatric Cardiology* 2005; 14(1): 42-4.
64. Yu CM, Bax JJ, Monaghan M, Nihoyannopoulos P. Echocardiographic evaluation of cardiac dyssynchrony for predicting a favourable response to cardiac resynchronisation therapy. *Heart (British Cardiac Society)* 2004; 90 Suppl 6: vi17-22.
65. Weiford BC, Subbarao VD, Mulhern KM. Noncompaction of the ventricular myocardium. *Circulation* 2004; 109(24): 2965-71.
66. Bodiwala K, Miller AP, Nanda NC, et al. Live three-dimensional transthoracic echocardiographic assessment of ventricular noncompaction. *Echocardiography* 2005; 22(7): 611-20.
67. Baker GH, Pereira NL, Hlavacek AM, Chessa K, Shirali G. Transthoracic realtime three-dimensional echocardiography in the diagnosis and description of noncompaction of ventricular myocardium. *Echocardiography* 2006; 23(6): 490-4.