

# Congenital Absence of Pericardium: A Rare Case Associated with Severe Mitral Stenosis with Pulmonary Hypertension

MI Zulkarnine<sup>1</sup>, BMM Choudhury<sup>2</sup>, MF Islam<sup>1</sup>, N Ahmed<sup>1</sup>

<sup>1</sup> Department of Cardiac Surgery, NICVD, <sup>2</sup> Department of Anaesthesiology, NICVD.

## Abstract:

**Key Words:**  
Mitral stenosis,  
Absent  
pericardium.

We report a rare case of congenital absence of pericardium in a 35 year old middle-aged man, who underwent closed mitral commissurotomy done for severe mitral restenosis developed after Percutaneous Transluminal Mitral Commissurotomy (PTMC) six months back. Operation was done under General Anaesthesia through left anterolateral thoracotomy. Pericardial defect was discovered intraoperatively. There was no clinical symptom that could be clearly related to the defect of the pericardial sac pre-operatively. The recovery of the patient was satisfactory and uneventful.

(*Cardiovasc. j.* 2011; 3(2): 222-225)

## Introduction:

Congenital Absence of Pericardium (CAP) is a rarely encountered clinical entity, occurring 1 in 1000 autopsies with a 5:1 male: female predominance.<sup>1</sup> CAP may be partial or complete and comprises partial left (70%), partial right (17%) or total bilateral (extremely rare) pericardial absence.<sup>2</sup> Most previous reports referred the patients who were asymptomatic and the defect were discovered incidentally during cardiac surgery or other intrathoracic operations for unrelated conditions or at post-mortem examination. Roughly 30% of patients with pericardial defects have associated cardiac or pulmonary anomalies.<sup>3</sup>

Again about 30% of patients have additional congenital abnormalities including Atrial Septal Defect, Bicuspid Aortic Valve, Congenital Mitral Stenosis, Patent Ductus Arteriosus, Tetralogy of Fallot or Pulmonary Malformation. Co-existence with pulmonary infections and endocarditis are also reported.<sup>4</sup> To the best of our knowledge and according to the post-operative registry of National Institute of Cardiovascular Diseases (NICVD) and other cardiac centres in Bangladesh, there is no case of CAP has so far been reported and according to the literature review this is the first case of CAP associated with severe Mitral Stenosis that underwent CMC. So we take the proud privilege

to report this case of rare entity for academic interest. Our case was diagnosed per-operatively while doing CMC for post PTMC Mitral Re-stenosis.

## Case Report:

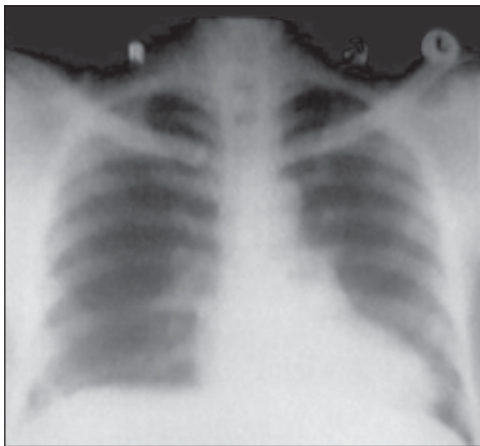
This middle-aged man of 35 years who is a cultivator presented with the complaints of increasing dyspnoea under mild to moderate exertion which refrained him from usual activities (NYHA Class-III) and occasional chest pain for the last two years with history of PTMC 6 months back. His chest pain was related to exertion and mostly in the left side of the chest and was not related to intake of meal or change of posture and having no diurnal variation.

His past medical history reveals that he was suffering from pain in different medium and small joints suggestive of rheumatic fever. With these presenting complaints and diagnosed as a case of Severe Mitral Stenosis With Pulmonary Hypertension he underwent PTMC. He passed a period of two months with less severity of symptoms. But after a period of two months his symptoms reappeared and were evaluated by echocardiography and were referred to Cardiac Surgeon. Echocardiography revealed Post PTMC Mitral Re-Stenosis with Pulmonary Hypertension and was planned for Closed Mitral Commissurotomy.

---

**Address of Correspondence:** Md.Iskandar Zulkarnine, Assistant Professor, Department of Cardiac Surgery, National Institute of Cardiovascular Diseases (NICVD), Dhaka, Bangladesh.

The patient was initially treated conservatively with diuretic, digitalis and phenoxymethyl penicillin but did not improve. On examination on the day before operation he was found well-oriented and cooperative, of below average body built, not anaemic not icteric or cyanotic and there was no edema or dehydration. There was no clubbing of fingers or toes and no rise of temperature. His pulse was 88 beats/minute, regular in volume and bilaterally symmetrical without any radio-radial or radio-femoral delay. Blood pressure was 110/70 mm Hg on sitting position. Neck veins were prominent but not engorged, JVP was slightly raised but not pulsatile and all accessible lymph nodes were not palpable.



**Fig.-1.** *Chest X-ray of the patient showing the enlarged heart silhouette displaced to left hemithorax & the less prominent right heart border placed over the spine.*

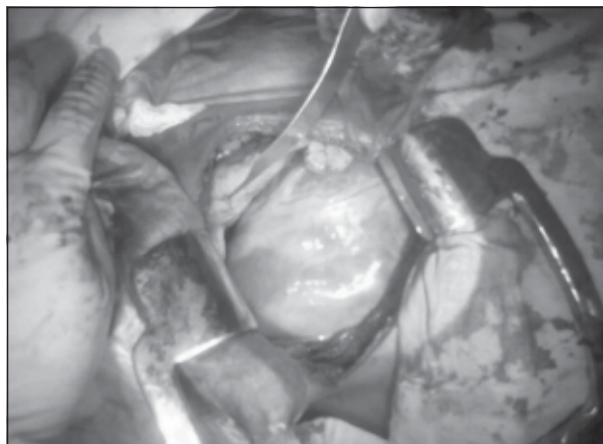
Examination of the cardiovascular system revealed normal precordium with apex beat shifted and palpable at 6<sup>th</sup> inters costal space, tapping in nature and producing moderate lift. First and second heart sounds were audible in all auscultatory areas but P<sub>2</sub> was loud and palpable. There was a mid-diastolic rumbling murmur audible at the mitral area. Respiratory system was normal with clear lung fields on both sides. All other systemic examinations revealed no abnormality.

Investigations revealed Haemoglobin-13 gm/dl, ESR-18mm in 1st hour, Total White cell and Differential cell count was within normal limits. Urinalysis, Renal function, Liver function and

Electrolytes were within normal limits. Echocardiography revealed dilated left atrium (42 mm) pulmonary artery dilated and hypertensive, there was no intra-cardiac mass or thrombus, Mitral valve leaflets were thickened, commissures fused with reduced Mitral Valve area (1.0 cm<sup>2</sup>).

Pulmonary Artery Systolic Pressure was 52mmHg, Interatrial and Interventricular septum were intact and there was no Mitral Regurgitation. Preoperative X-Ray Chest showed enlarged cardiac shadow in transverse diameter with less prominent right heart border placed over vertebral spine, left heart border was not straightened and the cardiac shadow was displaced to the left hemithorax. Electrocardiogram showed no abnormality.

**Per-Operative findings:** Under general anaesthesia chest was opened through left anterolateral thoracotomy in the left 4<sup>th</sup> intercostal space. After retraction of the left lung no tissue was found intervening between the mediastinal surface of left lung and the heart. It seemed that the pericardial cavity was directly in continuity with the pleural cavity. The left atrial appendage, the left ventricle and the pulmonary artery was visualized directly. There was complete absence of pericardium in all the surface of the heart. Usually in case of CMC, making pericardial cradle with pericardial slings lifts heart. But because of the absence of pericardium, pericardial cradle could not be made, rather after taking left atrial appendage purse-string and left ventricular apical pledgeted purse-string sutures, right index finger was introduced through left atrial appendage and finger fracture done. Then Tubbs dilator was introduced through left ventricular apex and its tip was passed across the mitral valve orifice with the guidance of the finger. Mitral valve was dilated by opening the Tubbs dilator up to 3.5 cm. Patient tolerated the procedure well and after securing proper haemostasis, ribs were approximated and wound closed in layers keeping a 32 Fr. chest drain tube. Patient's post-operative recovery was almost uneventful except an episode of supra-ventricular tachycardia, which was controlled with verapamil. Patient was discharged from the hospital on the 6<sup>th</sup> post-operative day.



**Fig-2:** *Intra-operative photograph showing complete absence of pericardium seen through antero-lateral thoracotomy during closed mitral commissurotomy operation.*

### Discussion:

Congenital absence of pericardium is an uncommon defect and total absence is yet extremely rare. This anomaly was first discovered in a live human being by Ladd in 1936 during surgical treatment of diaphragmatic hernia.<sup>5</sup> Hamoudeh et al reported congenital total absence of pericardium in a 74-year old patient who underwent surgical revascularization and a concomitant Aortic valve replacement.<sup>6</sup> Myocardial Stress Thallium Scan Scintigraphic images showed abnormal LV orientation and levo-rotation. Van San et al presented the Mayo Clinic experience of CAP which showed 15 cases in 34000 cardiac surgeries and all were diagnosed in the operating room.<sup>7</sup> Literature showed pre-operative diagnosis of CAP done mostly with patient having an abnormal chest skiagram and on further evaluation by CT scan or MRI or during cardiac catheterization.<sup>8</sup> Various types of CAP exist ranging from a small foramen to complete one sided or totally absent pericardium. Foraminal defects have the potential to cause herniation of the left atrium or both ventricle and constriction of the coronary arteries

by the pericardial rim.<sup>9</sup> There are a few cases of right-sided defects or complete defects but left sided defects are dominant. Only one report is found regarding anterior pericardial defect.<sup>10</sup>

Congenital absence of pericardium though rare but a well documented clinical phenomenon.<sup>11</sup> CAP takes place in the eighth week of intrauterine life

when premature atrophy of the left common cardinal vein (Cuvier's duct) compromises the blood supply to the pleuropericardial membrane with subsequent development of various degrees of CAP. Normally, the left common cardinal vein develops in to the left pleuropericardial membrane, and the right common cardinal vein forms the Superior Vena cava with concomitant closure of the right pleuropericardial membrane.

As it is a rare form of congenital malformation, the clinical features and diagnostic modalities of CAP deserve to be discussed to help physician in diagnosing the disease. Patients who have CAP may show no symptoms or intractable symptoms requiring surgery.<sup>12</sup> Symptomatic patients often describe a sharp, stabbing left sided chest pain that may be postural. With or without symptoms, CAP is difficult to diagnose. Clinical examination may show a significantly displaced apical impulse, which may be palpated in anterior or mid-axillary line. Basal ejection murmurs, apical mid-systolic clicks and murmurs may also be heard. Increased splitting of the second heart sound may be due to the presence of a right bundle branch block that is frequently associated with this defect.<sup>13</sup> Electrocardiographic manifestations of pericardial absence are-bradycardia, right bundle branch block, poor R-wave progression secondary to leftward displacement of the precordial transitional zone and prominent P-waves in the mid-precordial leads which denote right atrial overload.<sup>14</sup>

However, certain characteristic features can be identified by various imaging techniques.

Chest X-ray findings due to absence of pericardium are levo-position of the heart, flattening and elongation of the left ventricular border, lucent area between the diaphragm and the heart or aorta and pulmonary artery due to lung interposition. Frequently, however, the chest radiograph is not diagnostic. Echocardiography may rule out other structural defects. Due to pericardial absence heart forms a 'teardrop' appearance due to elongated atria and relatively bulbous ventricle because of suspension of the heart from its basal pedicle.<sup>15</sup> Findings in order of decreasing frequency are – unusual window ( a higher and more lateral window is required ), cardiac hypermobility (cardioptosis ) , abnormal swinging motion, paradoxical or flat systolic

motion of the ventricular septum with normal systolic thickening.<sup>16</sup> Computed tomography and MRI are especially useful as both the techniques can reveal levoposition of the heart, interposition of lung tissue between the inferior aspect of the heart, the diaphragm and abnormal extension of the main pulmonary artery and the left atrial appendage beyond the margins of the mediastinum.<sup>17,18</sup> The roentgenographic film of our patient as evaluated post-operatively showed evidence predictive of absence of pericardium. But because the patient had symptoms of mitral valvular disease who even underwent PTMC and developed re-stenosis with in less than 4 months of time, the main diagnostic workup and evaluative focus was mainly concerned with the primary diagnosis for which the patient presented to us.

### Conclusion:

Congenital total absence of the pericardium is a condition that is frequently missed antemortem and preoperatively because the patients are usually asymptomatic and the signs due to the lack of pericardial restrains are subtle.<sup>19</sup> When CAP is associated with underlying heart disease, diagnosis with conventional imaging techniques may be more difficult and treatment more problematic. The case described here is of post PTMC mitral restenosis in whom CAP was confirmed during surgical procedure of Closed Mitral Commissurotomy. No attempt was made to repair the defect as our target was CMC and the patient did not complain other than features of mitral stenosis. However, this publication may help cardiologists and cardiac surgeons to be aware of the condition and to apply the diagnostic tools so that the condition may be diagnosed preoperatively.

### References:

1. Bennet KR. Congenital foramen of the left pericardium. *Ann Thorac Surg* 2000; 70: 993-8.
2. Le Winter M.M.,Kabbani Samer. Pericardial disease. In :Braunwald E Zipes D, Libby P. Eds. *Heart disease*.7<sup>th</sup> ed . Philadelphia : W B Saunders, 2005: 1779.
3. Donald D Glower. Pericardium and Constrictive Pericarditis- Pericardial defects. In: Sabiston & Spenser.Eds. *Surgery of the Chest*, 7<sup>th</sup> ed. Philadelphia: Elsevier Saunders,2005: 1597.
4. Congenital absence of Pericardium and Straight Back Syndrome: Do They Have Similarities ? *The Internet Journal of Cardiology* 2007; 4(2). Available from: URL:<http://www.ispub.com>.
5. Ladd W. Congenital Absence of the Pericardium. *N Eng j Med* 1936; 214: 183.
6. Hammoudeh AJ, Kelly ME, Mekijian H. Congenital total absence of the pericardium: Case report of a 72-year-old man and review of the literature. *J Thorac Cardiovasc Surg* 1995; 109: 805-807.
7. Vanson JAM, Danielson GK, Schaff HV, Mullany CI, Julsrud PR, Breen J. Congenital partial and complete absence of pericardium. *Mayo Clin Proc* 1993; 68: 743-7.
8. Vedet Nisanoglu, MD, Nevzut Erdil, MD, and Bektas Battaloglu, MD. Complete left sided absence of the pericardium in association with Ruptured Aortic Dissection complicated by Severe Left Hemithorax. *Texas Heart Inst J* 2005; 32(2): 241-243.
9. Francisco Gregori J, Celso Otoviano, Corderio et all. Heart Transplant in a patient with complete absence of the pericardium. *Arq. Bras. Sao Paulo.Cardiol. Sept.* 2000. Vol 75 n-3.
10. Gregory N. Messner, DO, Peter Prendergast, MD, Yasmin Wadia, Thomas Chu, BS,Igor D.Gregoric, MD, Scott D. Flamm, MD, and O.H. Frazier, MD. Congenital Absence of Anterior Pericardium at Left Ventricular Assist Device Implantation. *Tex Heart Inst J* 2004; 31(1): 87-89.
11. Gatzoulis MA, Munk MD, Merchant N, Van Arsdell GS, McCrindle BW, Webb GD. Isolated congenital absence of the pericardium: clinical presentation, diagnosis, and management. *Ann Thorac Surg* 2000; 69; 1209-15.
12. Raman SV, Daniels CJ, Katz SE, Ryan JM, King MA. Congenital absence of the pericardium. *Circulation* 2001; 104: 1447-8.
13. Spodic D. Congenital abnormalities of the pericardium, The Pericardium: A Comprehensive Review.1<sup>st</sup>ed. New York: Marcel Dekker, 1997; 65-75.
14. Abbas AE, Appleton CP, Liu PT, Sweeny JP. Congenital absence of the pericardium: Case presentation and review of literature. *Int J Cardiol* 2005; 98: 21-5.
15. Alizad A and Seward J.B. Echocardiographic features of genetic diseases. *J. Am. Soc. Echocardiogr* 2000; 13: 796-800.
16. Connolly H.M.,Click R.L.Schattenberg T.T, Seward J.B. and Tajik A.J. Congenital absence of the pericardium : echocardiography as a diagnostic tool. *J. Am. Soc.Echocardiogr* 1995; 8: 87-92.
17. Gutierrez FR, Shakelford GD, McKnight RC, Levitt RG, Hartmann A. Diagnosis of congenital absence of left pericardium by MR imaging. *J Comput Assist Tomogr* 1985; 9: 551-3.
18. Daves ML, Groves BM. Computed tomography of absent left pericardium[letter]. *Radiology* 1981; 139: 753.
19. Gehlmann HR, Van- Ingen GJ. Symptomatic congenital complete absence of the pericardium. Case report and review of the literature. *Eur Heart J* 1989; 10(7): 670-5.