

A Young Bangladeshi Boy with Primary Ciliary Dyskinesia (Kartagener's Syndrome): A Rare Case

Bari MA¹, Hasan MJ², Ahmed S³

Abstract

Kartagener's syndrome, an autosomal recessive inherited disorder, is a subgroup of primary ciliary dyskinesias (PCD). This genetic disorder manifests from early life which distinguishes it from acquired mucociliary disorders. Kartagener's syndrome presents as a classical triad of situs inversus, sinusitis and bronchiectasis occurring majorly due to impaired ciliary motility. A 16 year-old boy from Fulbaria, Mymensingh with left sided consolidation for 1 month and recurrent episodes of nasal congestion and lower respiratory tract infection (LRTI) since his childhood. Clinical and imaging findings revealed left sided consolidation, chronic sinusitis, bronchiectasis, dextrocardia, and situs inversus. He was treated with orally administered antibiotics, bronchodilators, mucolytics, and chest physiotherapy. He was symptomatically better with the above therapy, and started on a long-term low-dose prophylactic antibiotic. As there is no easy, reliable non-invasive diagnostic test for Kartagener's syndrome and the correct diagnosis is often delayed by years, it may cause chronic respiratory problems with reduced quality of life. Genetic counseling and fertility issues should be addressed once Kartagener's syndrome is diagnosed.

CBMJ 2022 January: vol. 11 no. 01 P: 56-60

Keywords: Bronchiectasis; Kartagener's syndrome; Primary ciliary dyskinesia; Situs inversus

Introduction

In 1904, Siewert first described about Kartagener's syndrome (KS) which is a rare autosomal recessive genetic disorder. As Manes Kartagener firstly recognized this clinical triad in 1933 in detail, it bears his name.¹ Siewert described primary ciliary dyskinesia as a combination of situs inversus, chronic sinusitis, and bronchiectasis in 1904.² Camner *et al.* first suggested ciliary dyskinesia as the cause of KS in 1975. In 1977, Eliasson *et al.* first coined the term "immotile cilia syndrome" for KS to categorize infertility with chronic sinopulmonary infections.^{3,4} Most of the disease-causing mutations identified to date involve the heavy (dynein axonemal heavy chain 5) or intermediate (dynein axonemal intermediate chain 1) chain dynein genes in ciliary outer dynein arms, although a few mutations have been noted in other genes. Clinical molecular genetic testing for primary ciliary dyskinesia is available for the most common mutations. The respiratory manifestations of primary ciliary dyskinesia

(chronic bronchitis leading to bronchiectasis, chronic rhino-sinusitis, and chronic otitis media) reflect impaired mucociliary clearance owing to defective axonemal structure.⁵ Normal ciliary function is critical for respiratory host defense and motility of sperm, and ensures proper visceral orientation during embryogenesis. In KS, the gene mutation at *DNAI1* and *DNAH5* leads to impaired ciliary motility, which predisposes to recurrent sinopulmonary infections, infertility, and errors with left-right body orientation.^{6,7} In this article, we report a case of a 16 years old male

1. Dr. Muhammad Abdul Bari, Associate Professor, Department of Medicine, Community Based Medical College Hospital, Mymensingh.
2. Dr. Mahmud Javed Hasan, Associate Professor and Head, Department of Nephrology, Community Based Medical College Hospital, Mymensingh.
3. Dr. Sultan Ahmed; Associate Professor, Department of Medicine, Community Based Medical College Hospital, Mymensingh.

Address of Correspondence:

Email: abari.dr@gmail.com

who presented with features suggesting Kartagener's syndrome. This case report sheds light on clinical features, investigational procedures, and management strategy opted in this particular case.

Case presentation

A 16 years old male student normotensive, nondiabetic, non-smoker hailing from Fulbaria, Mymensingh presented with chest pain, cough with productive foul smelling purulent sputum and breathlessness for 1 month. He also complaints of high grade continued fever, highest temperature recorded was 104°F. The fever was associated with chills and rigors and profuse sweating, subsides with paracetamol. The left sided chest pain was compressive in nature, worse with inspiration and during coughing, but there was no radiation. He had been suffering from recurrent respiratory tract infection since his childhood. He was treated by local physicians with antibiotics, cough syrups and paracetamol, but no improvement. There was no similar illness in his family. There was no history of whooping cough, pulmonary TB or foreign body impaction.

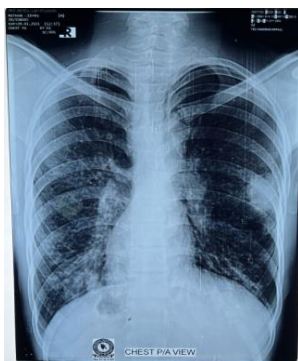

Fig 1: CXR PA View showing dextrocardia bronchiectasis and left sided Consolidation (Before Treatment)

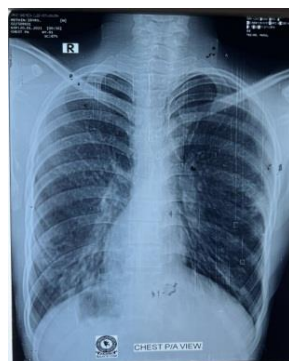

Fig 2: CXR PA View (After Treatment)

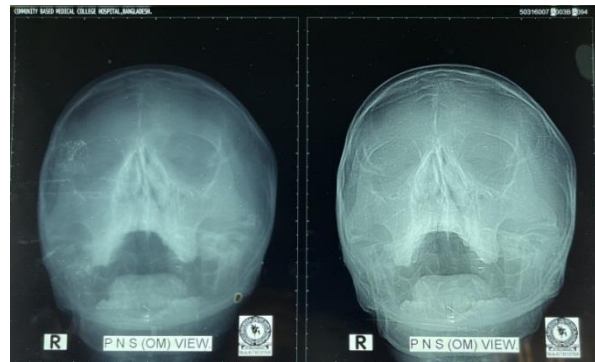


Fig 3: X-Ray PNS OM view showing bilateral maxillary sinusitis with DNS with Hypertrophied inferior turbinate

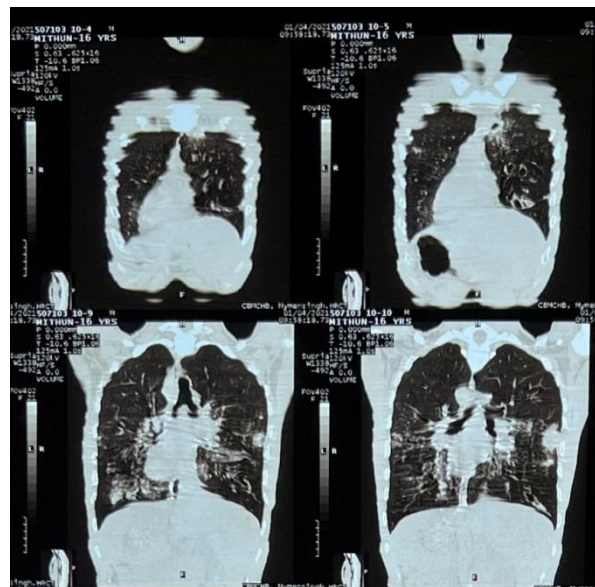


Fig 4: CT scan of chest and abdomen showing dextrocardia with radiographic evidence of bronchiectasis with situs inversus with left sided consolidation

On physical examination, he was ill looking, conscious, and oriented. His blood pressure (BP) was 100/70 mmHg, pulse rate (PR) 90 beats per minute, respiratory rate (RR) 26 breaths per minute, and temperature (T°) 101°F. His arterial oxygen saturation (SaO₂) was 93% with room air. He had a deviated left nasal septum and hypertrophied inferior turbinate. There was no lymphadenopathy in accessible sites. A respiratory system examination revealed coarse crackles and scattered rhonchi on both basal lung fields. On cardiovascular examination, apex beat was felt on right fifth intercostal space along

midclavicular line. Heart sounds were best audible on the left side of the chest. An abdominal examination revealed tympanitic note on percussion and no sign of fluid collection. Nervous system examination showed no abnormality.

A laboratory examination revealed hemoglobin 12 gm/dl, total leukocyte count 12,500/ μ l, and platelet count 250,000/ μ l. Sputum for acid-fast bacilli (AFB) staining (three times) was negative for *Mycobacterium tuberculosis*. Chest X ray PA view showed consolidation at left lung with bilateral bronchiectasis and dextrocardia due to situs inversus. CT scan of chest showed that situs inversus with bilateral infected bronchiectasis and evidence of left sided consolidation. X ray PNS OM view showed bilateral maxillary sinusitis with DNS left and hypertrophied right inferior turbinate. Ultrasound examination of his abdomen showed liver and inferior vena cava on left side, and spleen on right side, suggestive of situs inversus. Then, a diagnosis of left sided consolidation with Kartagener's Syndrome was made on the basis of clinical presentation and imaging features. He was treated with orally administered antibiotics, inhaled bronchodilators, mucolytics and chest physiotherapy. He was symptomatically better with the above therapy and started on long-term low-dose prophylactic antibiotic.

Discussion

Kartagener syndrome is a rare autosomal recessive disorder which is characterized by the clinical triad of chronic sinusitis, bronchiectasis, and situs inversus. The incidence is approximately 1 in 30,000 live births.⁸ Normal ciliary function is important for respiratory tract host defense, sperm motility, and normal visceral orientation during embryogenesis.⁸

Mutation of genes *DNAI1* and *DNAH5* are responsible for structural and functional abnormalities of ciliary ultrastructures such as dysfunction of dynein arms, radial spokes and microtubules of cilia. These faulty genes cause the cilia to be not in actual size or shape or move in the wrong way, making ciliary motility defective.^{9,10}

Abnormal ciliary motility leads to chronic recurrent sinopulmonary infections and infertility in female and sterility in male. Impaired ciliary motility during embryogenesis predisposes to left-right laterality defects like situs solitus (dextrocardia only) or situs inversus totalis where transpositions of thoracic and abdominal organs are noticed.⁹⁻¹¹

The diagnostic criteria recommended for this syndrome include history of chronic bronchial infection and rhinitis from early childhood, combined with one or more of following features: (a) situs inversus or dextrocardia in a patient or a sibling, (b) alive but immotile spermatozoa, (c) absent or impaired tracheobronchial clearance, and (d) cilia showing characteristic ultrastructural defect on electron microscopy.¹²

Current diagnosis requires a combination of technically demanding investigations, including nasal nitric oxide (nNO), high-speed video microscopy analysis (HSVA) and transmission electron microscopy (TEM). Historically, clinicians used the saccharine test to screen for PCD, but this is no longer advocated.¹⁵

Furthermore, more sophisticated diagnostic tests that might improve diagnostic accuracy (genotyping, immunofluorescence of ciliary proteins and electron microscopy tomography) are becoming increasingly available.

As there is no easy, reliable non-invasive diagnostic test for KS and the correct diagnosis is

often delayed by years, it may cause chronic respiratory problems with reduced quality of life.¹²⁻¹⁵ Our patient presented with left sided consolidation and history of recurrent episodes of sinopulmonary infections. Imaging findings revealed bronchiectasis, dextrocardia, and situs inversus, which met the diagnostic criteria for KS. Laboratory screening and confirmatory tests, which required a better clinical setup, were not done.

Conclusion

Patients with Kartagener's syndrome are often missed during evaluation of recurrent lower respiratory tract infections. As there is no easy, reliable non-invasive diagnostic test for KS and the correct diagnosis is often delayed by years, it may cause chronic respiratory problems with reduced quality of life. Genetic counseling and fertility issues should be addressed once KS is diagnosed. Early diagnosis and appropriate management of complications can significantly improve the morbidity and mortality associated with this disease. Genetic counselling is also an important aspect that needs to be addressed once Kartagener's syndrome is diagnosed.

References

1. Tadesse A, Alemu H, Silamsaw M, Gebrewold Y. Kartagener's syndrome: a case report. *J Med Case Rep.* 2018;12(1):5. Published 2018 Jan 10. doi:10.1186/s13256-017-1538-2.
2. Kartagener M. Zur pathogenese der bronchiectasien. I Mitteilung: Bronchiectasien bei situs viscerum inversus. *Betr Klin Tuberk* 1933;83:498–501.
3. Camner P, Mossberg B, Afzelius BA. Evidence of congenitally nonfunctioning cilia in the tracheobronchial tract in two subjects. *Am Rev Respir Dis.* 1975;112:807–9.
4. Eliasson R, Mossberg B, Camner P, Efzelius BA. The immotile cilia syndrome: A congenital ciliary abnormality as an etiologic factor in chronic airway infections and male sterility. *N Engl J Med.* 1977;297:1–6.
5. Leigh MW, Pittman JE, Carson JL, et al. Clinical and genetic aspects of primary ciliary dyskinesia/Kartagener syndrome. *Genet Med.* 2009;11(7):473–487. doi:10.1097/GIM.0b013e3181a53562.
6. Chilvers MA, Rutman A, O'Callaghan C. Ciliary beat pattern is associated with specific ultrastructural defects in primary ciliary dyskinesia. *J Allergy Clin Immunol.* 2003;112(3):518–24. doi:10.1016/S0091-6749(03)01799-8.
7. Lobo LJ, Zariwala MA, Noone PG. Ciliary dyskinesia: primary ciliary dyskinesia in adults. *Eur Respir Mon.* 2011;52:130–49.
8. Tadesse A, Alemu H, Silamsaw M, Gebrewold Y. Kartagener's syndrome: a case report. *J Med Case Rep.* 2018;12(1):5. Published 2018 Jan 10. doi:10.1186/s13256-017-1538-2
9. Chilvers MA, Rutman A, O'Callaghan C. Ciliary beat pattern is associated with specific ultrastructural defects in primary ciliary dyskinesia. *J Allergy Clin Immunol.* 2003;112(3):518–24.
10. Lobo LJ, Zariwala MA, Noone PG. Ciliary dyskinesia: primary ciliary dyskinesia in adults. *Eur Respir Mon.* 2011;52:130–49.
11. Rafi MK. Katagener's syndrome – A rare case series in female patients. *Indian J Med Case Rep.* 2016;5(4):33–40
12. Rafi MK. Katagener's syndrome – A rare case series in female patients. *Indian J Med Case Rep.* 2016;5(4):33–40.
13. Fraser RS, Muller NL, Colman N, Pare PD. Bronchiectasis and other bronchial abnormalities. In: Fraser RS, Muller NL, Colman N, Pare PD, editors. *Diagnosis of diseases of the chest.* 4. Philadelphia: W.B. Saunders Company; 1999. pp. 2281–3.

14. Jayashankar CA, Somasekar DS, Perugu PK, Reddy KV, Prakash B, Santosh KV. Kartagener's syndrome: A case report. *Sch J Med Case Rep.* 2014;2(1):7–10.
15. Barbato A, Frischer T, Kuehni CE, et al. Primary ciliary dyskinesia: a consensus statement on diagnostic and treatment approaches in children. *Eur Respir J* 2009; 34: 1264–1276.