

## Correlation between the Maximum Length and the Weight of the Human Humerus Bone

\*Haque SMA<sup>1</sup>, Mehataz T<sup>2</sup>, Afros F<sup>3</sup>, Mili DA<sup>4</sup>, Islam S<sup>5</sup>, Siddiquee T<sup>6</sup>, Tanzeem S<sup>7</sup>,  
Debnath D<sup>8</sup>, Ahmed M<sup>9</sup>, Sultana A<sup>10</sup>

### Abstract

The humerus bone of the humans is frequently used in anatomical science, forensic medicine and anthropological studies. This cross-sectional, descriptive study was done on 100 (43 right and 57 left) fully ossified dry human humerus in the Department of Anatomy, Mymensingh Medical College, Bangladesh, between July 2021 to June 2022. A non-random, purposive sampling technique was adopted. The maximum length was determined by measuring the distance between the most superior point on the head of the humerus and the most distal point of the trochlea of the humerus. The length was measured with a metallic scale, while the weight of the humerus was measured using a digital weighing machine. The mean ( $\pm$ SD) maximum length of the right humerus was 304.139 ( $\pm$ 17.652) mm, while the left humerus was 300.42 ( $\pm$ 20.779) mm. The mean ( $\pm$ SD) weight of the right humerus was 91.069 ( $\pm$ 26.944) gm and the left humerus was 93.965 ( $\pm$ 32.227) gm. A positive correlation was observed between the maximum length and the weight of the human humerus through regression analysis ( $r=0.653$  and  $r=0.824$  on right and left side respectively). The differences were statistically significant on both sides ( $P<0.001$ ).

CBMJ 2024 January: vol. 13 no. 01 P: 60-65

**Keywords:** Human humerus, maximum length, weight

### Introduction

The humerus is the bone of the arm. It is the longest and strongest bone of the upper limb.<sup>1</sup> It consists of three parts: upper end, lower end, and shaft. The upper end presents the five features: head, neck, greater tubercle, lesser tubercle, and

intertubercular sulcus. The lower end presents the seven features: capitulum, trochlea, radial fossa, coronoid fossa, olecranon fossa, medial epicondyle, and lateral epicondyle. The shaft is a long part of bone extending between its upper

1. \*Dr. Shah Md. Atiqul Haque, Lecturer, Department of Anatomy, Mymensingh Medical College, Mymensingh.
2. Dr. Tasnova Mehataz, Indoor Medical Officer, Department of Anaesthesiology, Community Based Medical College, Bangladesh (CBMC, B), Mymensingh.
3. Dr. Farzana Afros, Assistant Health Officer, Dhaka North City Corporation, Dhaka, Bangladesh.
4. Dr. Dilruba Afrose Mili, Lecturer, Department of Anatomy, Community Based Medical College, Bangladesh (CBMC, B), Mymensingh.
5. Dr. Shamima Islam, Lecturer, Department of Anatomy, Mymensingh Medical College, Mymensingh.
6. Dr. Tasnoma Siddiquee, Lecturer, Department of Anatomy, Mymensingh Medical College, Mymensingh.
7. Dr. Sabiha Tanzeem, Lecturer, Department of Anatomy, Mymensingh Medical College, Mymensingh.
8. Dr. Dhruvajit Debnath, Lecturer, Department of Anatomy, Mymensingh Medical College, Mymensingh.
9. Dr. Muntasir Ahmed, Assistant Professor, Department of Anatomy, Netrokona Medical College, Netrokona.
10. Dr. Arifa Sultana, M. Phil. (Thesis Part), Department of Anatomy, Mymensingh Medical College, Mymensingh.

### Address of Correspondence:

Email: dr.rony13@gmail.com

and lower ends. Morphometric study of bones plays an important role in identifying unknown bodies, parts of bodies, or skeletal remains. Knowing the maximum length and weight of the human humerus is very important for anatomical science, forensic medicine, and anthropological studies and may help the investigators to define the identity of a skeleton in their practice. Moreover, those data also help anthropological and archaeological investigations by providing with the evidence to indicate the characteristic features of a population.<sup>2-4</sup> To our knowledge, no study concerning morphometry of upper limb bones has been reported in our country. Hence, the importance of studying such morphometry and correlation carry immense prevails in our country.

## Methods

This cross-sectional, descriptive type study was performed between July 2021 and June 2022 in the Department of Anatomy, Mymensingh Medical College, Bangladesh. Samples were collected from the same department. One hundred fully ossified dry human humerus (43 right and 57 left) were collected for this study. A non-random, purposive sampling technique was used for sample selection. The sample was excluded if the bones were unossified, developmentally abnormal, and broken even partially. Measurement of the maximum length and weight of the humerus was done in this study. The maximum length of the humerus was measured by a metallic scale. One blade of the scale was placed over the most superior point on the head of the humerus and another blade was placed below the most distal point of the trochlea of the humerus (Fig. 1). The length was expressed in mm. Then, a digital weighing

machine was used to take the weight of the humerus. Specimen bones were placed upon the weighing machine and the reading was taken from the display and was recorded in grams (Fig. 2).

All the data were double-checked, compiled, and sorted properly. Data processing and data analysis was carried out using SPSS version 22.0 (Statistical Package for Social Science) for Windows. Pearson correlation was done to determine the relationship between those quantitative variables. All tests were two tailed and  $P < 0.05$  was considered statistically significant. Analyzed data were presented through histograms and scatter diagrams.



**Fig. 1:** Photograph showing the measurement of the maximum length of the humerus.

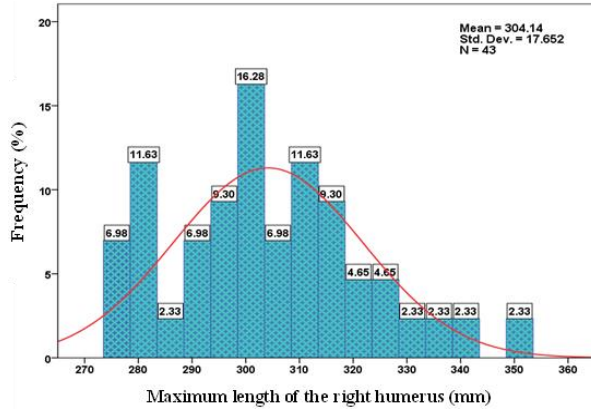


**Fig. 2:** Photograph showing the measurement of the weight of the humerus.

## Results

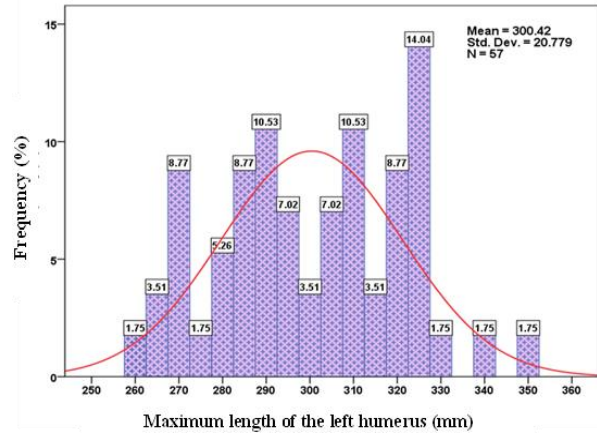
The mean ( $\pm$ SD) maximum length of the humerus was 304.139 ( $\pm$  17.652) mm and 300.42 ( $\pm$ 20.779) mm on the right and left sides

respectively. The maximum length of the right sided humerus ranged between 276 mm and 350 mm. More than 79% of samples were found within the range between 278 mm and 335 mm (Fig. 3).

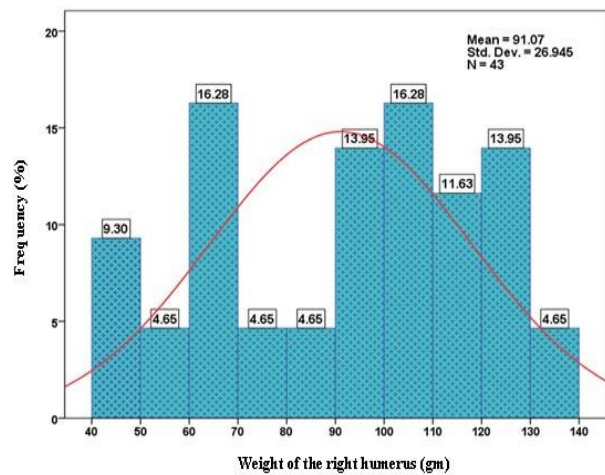


**Fig. 3:** Histogram showing the frequency distribution of the maximum length of the right humerus.

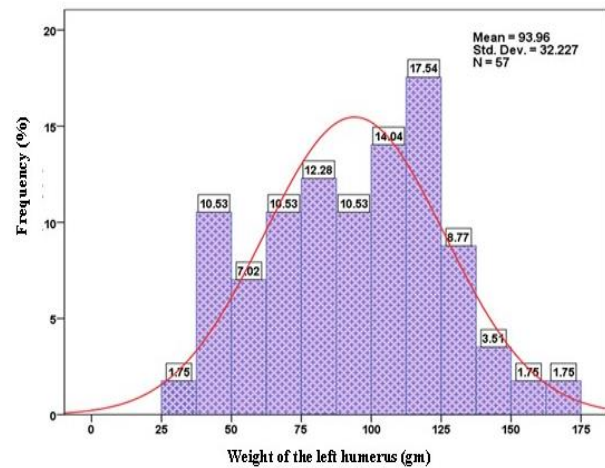
The maximum length of the left humerus ranged between 260 mm and 349 mm. More than 75% of samples were within 285 mm and 332 mm in length (Fig. 4). The mean ( $\pm$ SD) weight of the humerus was 91.069 ( $\pm$  26.944) gm and 93.965 ( $\pm$ 32.227) gm on the right and left sides respectively. The weight of the right sided humerus ranged between 41 gm and 138 gm (Fig. 5). More than 81% of samples were found within 60 gm and 130 gm. The weight of the left humerus ranged between 32 gm and 163 gm. More than 77% of samples were within 62.50 gm and 150 gm (Fig. 6). Pearson correlation test showed a positive correlation between the maximum length and the weight of the humerus. It was observed that the weight of the humerus gradually increased with the length of the humerus on both sides. The regression line showed the positive correlation (on the right side,  $r=0.653$ , while on the left side,  $r=0.824$ ). Both the differences were statistically significant ( $P<0.001$ ) (Fig. 7 & 8).



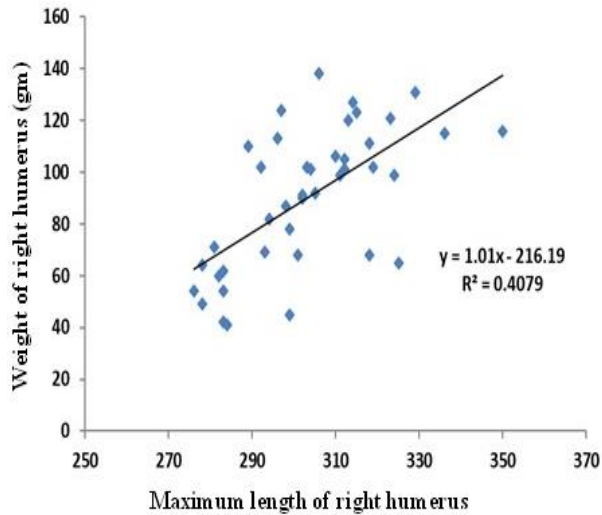
**Fig. 4:** Histogram showing the frequency distribution of the maximum length of the left humerus.



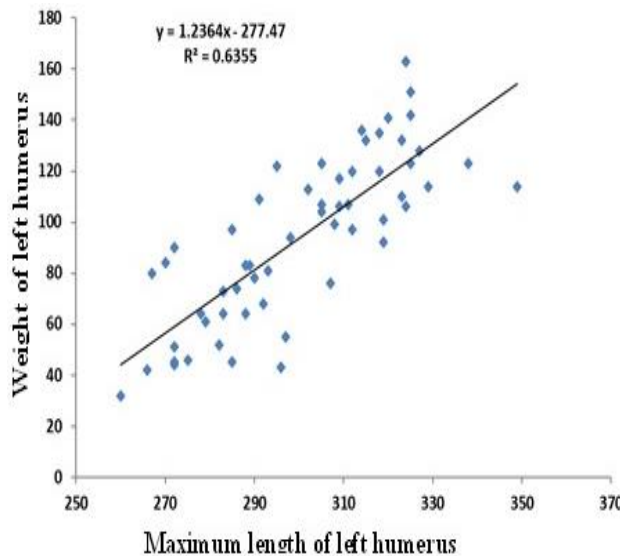
**Fig. 5:** Histogram showing the frequency distribution of the weight of the right humerus.



**Fig. 6:** Histogram showing the frequency distribution of the weight of the left humerus.



**Fig. 7:** Scatter diagram showing correlation between the maximum length and the weight of the right humerus.



**Fig. 8:** Scatter diagram showing correlation between the maximum length and the weight of the left humerus.

## Discussion

According to the present study, the mean ( $\pm$ SD) maximum length of the humerus was 304.139 ( $\pm$ 17.652) mm on the right side and 300.42 ( $\pm$ 20.779) mm on the left side. The mean value of right-sided humeri in the present study was very similar to the findings of the previous studies.<sup>4,6-10</sup> However, the mean value of this right side was

higher than the values reported in previous studies done in Indian population.<sup>11-14</sup> In contrast, our mean value of the right side was lower than the value described by some other studies.<sup>15-18</sup> The mean value of left-sided humeri in the present study was nearly similar to the value described by several studies.<sup>4,5,15,19-21</sup> The mean value we found for the left side was higher than the values described by some of the previous studies done in India.<sup>22-25</sup> In contrast, our mean value of the left side was lower than the value described by several studies.<sup>7-10,18,26</sup> According to the present study, the mean ( $\pm$ SD) weight of the humerus was 91.069 ( $\pm$ 26.944) gm and 93.965 ( $\pm$ 32.227) gm on the right and left sides respectively. Our values are lower than that of estimated by Niraj, Dangol & Ranjit<sup>9</sup> and Kabacki *et al.*<sup>19</sup> as they found 118.47 ( $\pm$ 15.81) gm and 111.63 ( $\pm$ 33.34) gm respectively.

Several evidence showed that the problem of such size differences between the race or ethnic groups was addressed by genetic differences, as well as total body weight, lifestyle, hormonal status, movement, workload of the skeleton. Same is true for the weight of the bones.<sup>27,28</sup>

## Conclusion

Our data suggests a positive correlation between the maximum length and the weight of the human humerus, as observed in both sides. The weight of the humerus gradually increased with the length of the humerus on both sides. The results of the present study will provide data for further study to enrich the information pool on our population. However, further studies with larger samples and advanced application of CT/MRI scans on different ethnicities in our country are recommended.

## References

1. Singh V. *Textbook of Anatomy: Upper Limb and Thorax*. 4th edition. Vol. 1. New Delhi: Elsevier; 2023. p.18.
2. Buttner A, Hubig M, Mall G. A sex determination and estimation of stature from the long bones of the arm. *Forensic Sci Int*. 2001;117:23-30.
3. Wright LE, Vásquez MA. Estimating the length of incomplete long bones: forensic standards from Guatemala. *Am J Phys Anthropol*. 2003;120(3):233-51.
4. Vinay G, Benjamin W, Das AK, Raviprasanna KH, Kumar DS. Morphometric study of the distal end of dry adult humerus of the South Indian population with its clinical applications. *Natl J Clin Anat*. 2021;10(2):70-4.
5. Ashiyani ZA, Solanki S, Mehta CD. The morphometric measurement of segments of humerus. *J Res Med Den Sci*. 2016;4(1):38-40.
6. Chaudhary RK, Dhakal A, Sah SK, Prajuli SB, Pokhrel S, Deo SK. Morphometric evaluation of dry humerus bone in a medical college of Eastern Nepal. *Birat J Health Sci*. 2019;4(2):729-33.
7. Gayatri D, Kamdi A, Sherke AR, Krishnaiah M, Sharada HR. Estimation of Humerus Length from its Segments in Telangana State. *IOSR J Dent Med Sci*. 2014;13(09):18-21.
8. Akman SD, Karakas P, Bozkir, MG. The morphometric measurements of humerus segments. *Turk J Med Sci*. 2006;36(2):81-5.
9. Niraj P, Dangol PMS, Ranjit N. Measurement of length and weight on non-articulated adult humerus in Nepalese corpses. *J Kathmandu Med Coll*. 2013;2(1):25-7.
10. Mutluay SD, Acikgoz AK, Bozkir MG. Estimation of the maximum length of the humerus from its segments' lengths. *Int J Morphol*. 2020;38(5):1350-5.
11. Jahan S, Srivastava R. Morphometric study of proximal end of humerus in North Indian population. *J Med Sci Clin Res*. 2020;8(8):102-8.
12. Meghana N, Savithri P. Morphological analysis of length of human humerus. *J Evo Med Dent Sci*. 2020;9(27):1940-3.
13. Kumari N, Subhash A, Sinha RR. Morphometric analysis and clinical significance of humeral condyles in dry bone. *Eur J Mol Clin Med*. 2020;7(10):3471-6.
14. Udhaya K, Devi KVS, Sridhar J. Regression equation for estimation of length of humerus from its segments: a South Indian population study. *J Clin Diagn Res*. 2011;5(4):783-6.
15. Murlimanju BV, Prabhu LV, Pai MM, Shreya M, Prashanth KU, Kumar CG, et al. Anthropometric study of the bicipital groove in Indians and its clinical implications. *Chang Gung Med J*. 2012;35(2):155-9.
16. Gupta S, Naqshi BF, Shah AB, Hassan N, Raina S, Khan HA, et al. Variations in the bicipital groove in North Indian population: a morphological and morphometric study and review of literature. *Int J Health Sci Res*. 2015;5(9):220-6.
17. Sinha SK, Kumar S, Dhan MR, Kumar V. Morphometric study of segments of humerus in population of Bihar. *Int J Anat Res*. 2020;8(1):7217-20

18. Zichao X, Haoliang D, Chuanzhen H, Haitao X, Zhiquan A. An anatomical study of the nutrient foramina of the human humeral diaphysis. *Med Sci Monit.* 2016;22:1637-45.
19. Kabakci AAD, Buyukmumcu M, Yilmaz MT, Cicekcibasi AE, Akin D, Cihan E. An osteometric study on humerus. *Int J Morphol.* 2017;35(1):219-26.
20. Kantha BML, Kulkarni R. Estimation of total length of humerus from its fragments in South Indian population. *Int J Anat Res.* 2014;2(1):213-20.
21. Somesh MS, Prabhu LV, Shilpa K, Pai MM, Krishnamurthy A, Murlimanju BV. Morphometric study of the humerus segments in Indian population. *Int J Morphol.* 2011;29(4):1174-80.
22. Srimani P, Saha R, Goswami B, Mazumdar S. Morphometric analysis of bicipital groove of humerus with its clinical implication: a study in West Bengal. *Int J Anat Res.* 2016;4(4):3009-15.
23. Goshu BT. Anatomical analysis of bicipital groove of dry adult human cadaveric humerus in Ethiopia. *EC Clin Exp Anat.* 2019;2(7):311-5.
24. Bhusaraddi PS, Shinde VK, Khona P. right humerus; an equation to estimate the length from its fragments. *IP Indian J Anat Surg Head Neck Brain.* 2019;5(4):101-4.
25. Singh A, Nagar M & Kumar A. An anthropometric study of the humerus in adults. research and reviews. *J Med Health Sci.* 2014;3(3):77-82.
26. Salles AD, Carvalho CRF, Silva DM, Santana LA. Reconstruction of humeral length from measurements of its proximal and distal fragments. *Braz J Morphol Sci.* 2009;26(2):55-61.
27. Looker AC. The skeleton, race, and ethnicity. *J Clin Endocrinol Metab.* 2002;87(7):3047-50.
28. Nurunnabi ASM, Alim A, Mahbub S, Begum M, Khatun M, Ara S. Weight of the human thyroid gland – a postmortem study. *Bangladesh J Med Sci.* 2010;9(1):44-8.