

Case report

Dr. Shahnaz Sultana Beauty
BDS, FCPS
Asst. Professor
Department of Conservative Dentistry
& Radiology
City Dental College, Dhaka

Dr. Shahana Dastagir Sunny
BDS, MPhil
Assoc. Professor & Head
Dept. of Dental Public Health
City Dental College, Dhaka

Prof. Dr. Md. Ali Asgor Moral
Professor
Dept. of Conservative Dentistry & Endodontics
Course Director, Faculty of Dentistry
Bangabandhu Sheikh Mujib Medical
University, Dhaka

Prof. Dr. Md. Shamsul Alam
Professor & Chairman
Dept. of Conservative Dentistry & Endodontics
Dean, Faculty of Dentistry
Bangabandhu Sheikh Mujib Medical
University, Dhaka

Correspondence to:
Dr. Shahnaz Sultana Beauty
BDS, FCPS
Asst. Professor
Department of Conservative Dentistry
& Radiology
City Dental College, Dhaka.
Email: shahnaz311@gmail.com

An Endodontic Enigma: A Case Report of External Inflammatory Root Resorption-2 years Follow up

Abstract:

In dentistry, root resorption is the breakdown or destruction and subsequent loss of the root structure of a tooth caused by living body cells attacking part of the tooth. When the damage extends to the whole tooth is called tooth resorption. Severe root resorption is very difficult to treat and often requires the extraction of teeth. Root canal therapy has been shown to be a very successful means of treating inflammatory resorption. It has been recommended to include a calcium hydroxide paste in the root canal therapy to enhance the success of the treatment outcome. Calcitonin has also been suggested as an interim root canal medicament to assist in the inhibition of osteoclastic bone and dentin resorption. Calcitonin penetrates the dentinal tubules in the outward direction, thus exerting a direct effect.

Keywords: Trauma, calcification, root resorption, Calcium hydroxide [Ca(OH)₂].

Introduction:

American Association of Endodontists has defined root resorption as physiological and pathological processes that result in loss of cementum and/or dentine from the root surface.¹⁻⁵ On the basis of the site of origin, it may be either internal or external and further, apical or cervical resorptions. Henry and Weinman have reported as high as 90% prevalence of root resorption in their study on 5800 teeth while Massler and Perreault have reported that resorption of teeth in Indians are found five times more often than in the United States. Females present higher incidence of root resorption than males. Root resorption in presence of periodontal diseases is found three times more often than in uninvolved teeth.²

External and Internal Root resorptions:

External root resorption occurs more frequently than internal root resorption. External root resorption is caused by an injury to the external root surface. After an injury such as concussion or

subluxation, cementum can be damaged, resulting in a localized inflammatory response and area of resorption. In about two weeks, the periodontium and root surface should repair spontaneously, and in those cases no treatment is needed. With severe injuries such as intrusion or avulsion (especially when implantation is delayed more than 60 to 90 minutes), active external inflammation can persist and histologically there will be multinucleated osteoclasts resorbing the dentin of the root. Seven to ten days after the injury, it is recommended to treat the tooth endodontically by placing Ca(OH)₂ in the canals long term and replacing the calcium hydroxide in one month and then at three months intervals until the process ends. The high pH of the calcium hydroxide seems to permeate through the dentinal tubules to kill bacteria and neutralize endotoxins, which stimulate inflammation if bacteria are thought to originate in the sulcus of the tooth (totally external), a vitality test will respond positively.

In cases, where infected pulp causes external root resorption usually in the apical or lateral aspects, a vitality test can be negative.³⁻⁸

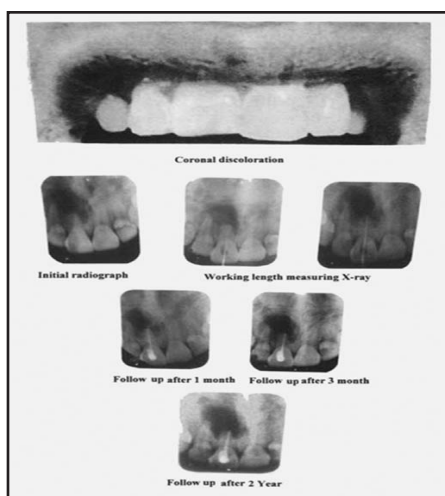
The cause of internal root resorption is unclear, but trauma and the extreme heat produced when using a high-speed drill without water have been suggested. Histologically, there is normal pulp tissue transforming into granulation tissue with giant cells resorbing the dentinal wall, and resorption will only occur if the odontoblastic layer and predentin are lost or altered. Internal root resorption usually contains some vital pulp and gives a positive vitality test, however, since necrotic pulp tissue is usually found coronal to the active resorbing cells which are more apical, the tooth can sometimes test negative. Internal root resorption resolves with root canal treatment because the resorbing cells will no longer have the blood supply to survive. In cases where internal root resorption causes buccal or lingual perforation, mineral trioxide aggregate (MTA) can be used to repair.³⁻¹⁰

Types of External Root resorption:

There are different forms of external root resorption. A classification system for external root resorption that has a known mechanism is 1) surface resorption 2) replacement resorption associated with ankylosis and 3) inflammatory resorption.

External Inflammatory Root resorption (EIRR):

This type of root resorption is a complication that can follow dental trauma. It begins as a surface resorption due to damage to the periodontal ligament in conjunction with the traumatic injury. The pulp is also damaged and become necrotic. As the surface resorption approaches the dentine, the osteoclast will carry on their resorption activity, as necrotic and possible infected pulp matter is released from the thus exposed dentine tubules. The pulp products will then maintain an inflammatory process in the adjacent periodontal tissues that in turn will trigger the continuance of the resorption. EIRR may occur rapidly in young teeth because the dentinal tubules are wide and allow the irritants to move freely to the external surface of the root.⁴⁻⁷



Case Report:

A male patient aged 22 years came to the Department of Conservative Dentistry and Endodontics at Bangabondhu Sheikh Mujib Medical University (BSMMU) on 11/3/2008. He complained of pain and swelling of right upper maxillary central incisor. On clinical examination, swelling on buccal surface and coronal discoloration were observed. Patient also gave a history of trauma on the affected tooth occurred several years back. Radiographic findings were complete obliteration of the canal having calcification and severe root resorption with a large periapical lesion. On the basis of clinical and radiographic examinations, the case was diagnosed as external inflammatory root resorption.

On the first visit, root canal was opened but it was not possible to negotiate the canal because of obliteration of canal due to calcification. On the second visit, canal was negotiated with No.8K file and then upto No.15K file and a working length measuring radiograph was taken. On the third visit, canal was prepared upto No.30K file and irrigated with normal saline. On the fourth visit, swelling was disappeared on buccal surface and become painless. A dressing with Ca(OH)₂ paste was given in the canal and patient was asked to attend 7 days later. Unfortunately, after 3 days, swelling again recurred on buccal surface. The root canal was again dressed with Ca(OH)₂ paste followed by pus drainage and curettage on the buccal surface. On the next visit, percussion pain disappeared and neither swelling nor exudation was observed in the canal. Then the canal was obturated with gutta-percha point and zinc oxide eugenol sealer. A radiograph was taken and patient was advised to attend for follow up one month later. On the follow up visit, patient was examined clinically and there was no pain and tenderness on percussion. On radiographic examination, there was no significant change was evident. Three months later, there was no pain and swelling and radiographic examination showed no further resorption. Follow-up taken after two years and the patient was completely alright clinically and radiographically, there was no further resorption or it was arrested.¹⁰

Discussion:

Pathological external root resorption is more common as compared to internal resorption.^{1,2} The present case was obtained by chance who attended the Department of Conservative Dentistry and Endodontics at BSMMU seeming that the EIRR may be prevalent among the cases of root resorptions in Bangladesh. Among the etiological factors, trauma is considered as one of the vital cause of tooth resorption.^{4,7} The present case had a history of trauma happened few years back along with the presentation of other signs and symptoms of EIRR.

The high pH of the calcium hydroxide seems to permeate through the dentinal tubules to kill bacteria and neutralize endotoxins, which stimulate inflammation if bacteria are thought to originate in the sulcus of the tooth (totally external), a vitality test will respond positively. In cases, where infected pulp causes external root resorption usually in the apical or lateral aspects, a vitality test can be negative. Seven to ten days after the injury, it is recommended to treat the tooth endodontically by dressing root canal using $\text{Ca}(\text{OH})_2$ repeatedly.³⁻⁸ The present report delineated that the external inflammatory root resorption was managed on the basis of VimalSikri et al. and others.

Conclusions:

External root resorption may be an uncontrolled phenomenon, and most known interventions have no effect. Currently, there are no effective treatment options for vital tooth that suffer from root resorption. Repeated $\text{Ca}(\text{OH})_2$ dressings followed by conventional root canal obturation technique maybe effective in the management of such problem. Further broad scale clinical trials may be conclusive.

References:

1. Root Resorption from wikipedia, Free Encyclopedia. <http://en.wikipedia.org/wiki/root-resorption>.
2. Root Resorption- An endodontic enigma. J Endodontol 1993; Dec.
3. Vimal S, Poonam S. Root resorption. Endodontol 1993; Dec.:1.
4. Finucane D, Kinirorns MJ. External inflammatory and replacement resorption of luxated, and avulsed replanted permanent incisors: a review and case presentation. Dent Traumatol 2003;19:170-74.
5. Sara K. Etiology, diagnosis and treatment of external and internal root resorption. Endo Articl 2008;Nov.-Dec.
6. Andreasen JO. Relationship between surface and inflammatory resorption and changes in the pulp after replantation of permanent incisor in monkey. J Endodont 1981;294:5-7.
7. Andreasen JO. External root resorption : its implication in dental traumatology, paedodontics, periodontics, orthodontics and endodontics. Internat J Endodont 1985;8:109.
8. Nisha G, Amit G, Textbook of Endodontics. India:1st ed. 2007:407.
9. Vimal S, Poonain S. Root Resorption. Endodontol 1993;Dec.:2-3.
10. Maryam J, Mina Z, Shiva S. External root resorption- arrested or progressing? Iranian Endodont J 2008;3;93-4.