

Case report

Dr. Sabrina Haque

BDS, MS
Assistant Professor
Department of Conservative Dentistry
Dhaka Dental College & Hospital
Dhaka-1206

Prof. Dr. Md. Zakir Hossain

BDS, PhD
Professor & Head, Deptt. of Orthodontics &
Dentofacial Orthopedics
Dhaka Dental College & Hospital
Dhaka-1206

Pulp Calcification: Case reports with difficult Endodontic Problem

Abstract:

Teeth with signs and symptoms with calcified pulp require treatment. If it is possible to introduce endodontic instrument into the canal, conventional root canal treatment is done. In cases where root canal treatment is not possible, surgical approach may be necessary [6].

In calcified canals, instrumentation is attempted very carefully because there often remains very fine pathway within the calcified materials. Once a fine file (no. 06) has reached the correct level, enlargement of the canal is a simple matter. Use of EDTA alone or RC preparation along with NaOCl irrigant will often help this stage of the operation. If instrumentation is not possible, one should use an engine driven instrument to grind away the stone with small round, long shanked burs. In symptomless tooth with calcification, no treatment is required. Such a tooth should be kept under yearly radiographic review, and if symptoms arise may best be treated surgically [1].

Introduction :

Calcification of the pulp tissue, a very common occurrence, especially in teeth with luxation injuries[6]. When the pulp is subjected to a rapid and overwhelming bacterial invasion or traumatic insult, little time may be available for normal reparative dentine formation. Under such situation, the dental pulp may die rapidly, leaving the canal space patent but full of necrotic and often infected tissue [2]. However, if irritant impact the tooth slowly over a long period, then both the pulp chamber and the pulp system undergoes calcific changes that may impede access during root canal preparation [3,4].

Fortunately, only a small percentage of cases that radiographically exhibit fine or unidentifiable canals or calcified blockages prove to be unmanageable using non surgical root canal techniques [4,5]. Of the numerous techniques available to locate and negotiate these canals

only procedures known to be effective in our clinical practice are considered here [4].The approach requires knowledge of the normal pulp chamber location together with root canal anatomy.

Causes of Pulpal Calcification:

1. Mostly unknown
2. Calcification may occur in case of
 - a. Caries
 - b. Medication (Steroid-Prednisilone for a long time)c.
 - c. Trauma-Extrusion, Lateral Luxation
 - d. Aging

Pathogenesis of Pulpal Calcification [1,6,7] :

- 1 Calcification may occur around a nidus of degenerating cells, blood thrombi, or collagen fibers
- 2 In Dystrophic calcification calcium is deposited in tissues which degenerate. Calcium phosphate crystals may be deposited within the cells
3. Calcification in the mature pulp is often assumed to be related to the aging process.

4. In age changes continuous formation of secondary dentin throughout the life gradually reduces the size of the pulp chamber and root canals. In addition, certain regressive changes in the pulp appear to be related to the cellularity and concomitant increase in the number and thickness of collagen fibers particularly in the radicular pulp. The thick collagen fibers may serve as a foci for pulpal calcification.

The odontoblast decrease in size and number and may disappear in certain areas of the pulp, particularly on the pulpal floor over bifurcation. With age, there is a progressive reduction in the number of nerves and blood vessels. The main changes in dentine is dentinal sclerosis and the number of dead tracts.

5. In teeth with extrusion & lateral luxation injuries pulp canal obliteration is common. The exact mechanism is unknown but it has theorized that the sympathetic & parasympathetic control of blood flow to the odontoblast is altered resulting uncontrolled reparative dentine formation.

Another theory is that hemorrhage & blood clot formation in the pulp after injury is a nidus for subsequent calcification.

Clinical presentation:

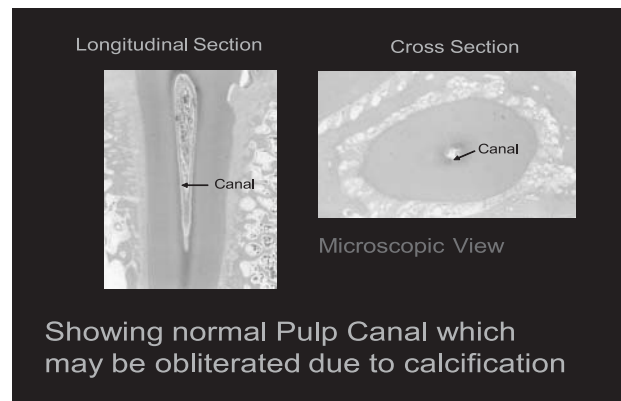
1. Calcified tooth may show a yellowish hue when compared with adjacent teeth.
2. In pulp stone cases usually pain & Sensitivity is frequently present
3. Occasionally the tooth may be slightly loose or displaced (History of Trauma)

Diagnostic Aids:

Radiographs: # Periapical X-ray, OPG X ray
 Approach through the canal by diagnostic instrument
 Detection of the canal orifice by endodontic mechanism.

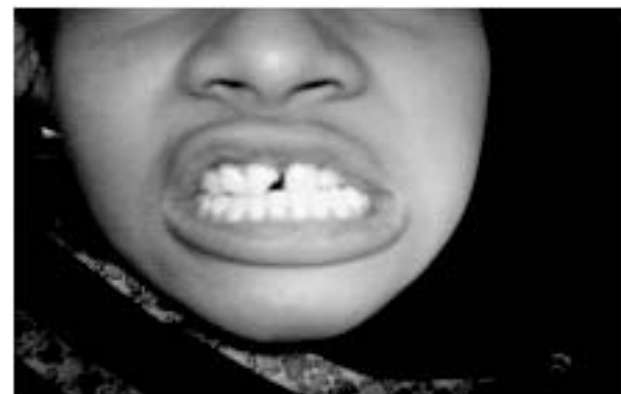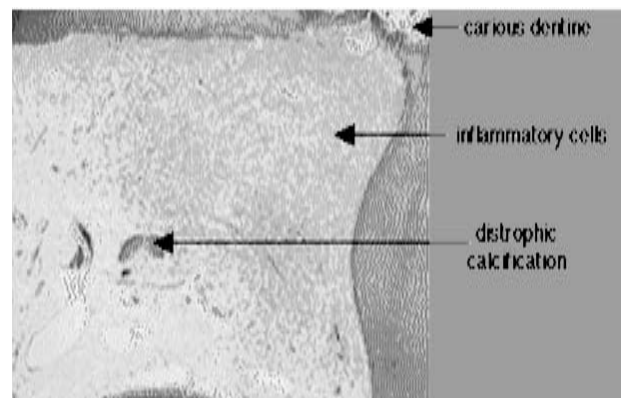
Methods of Locating Calcified Canal:

- Canals that look completely calcified radiographically can be instrumented with a fine file because a very fine pathway remains within the calcified material
- A long shanked no. 4 or no. 6 round bur is used to explore the assumed location of the main pulp chamber
- The endodontic explorer, DG 16, is used to explore the region of the pulpal floor. A slight “ tug-back” in the area of the canal orifice often signals the presence of the canal.



Negotiation of Calcified Canal:

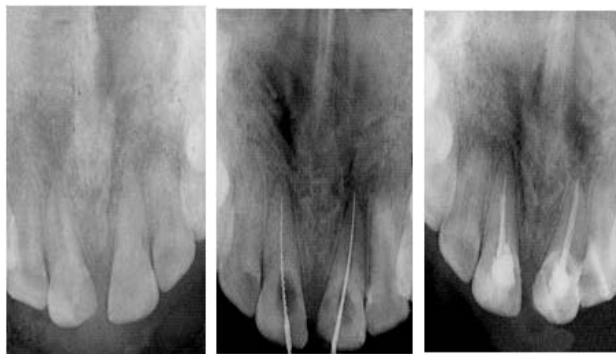- After locating the orifice of the canal the smallest instrument (usually no:06,08,or 10 file) should be introduced
- Gentle passive movement, both apical & rotational often produces some penetration
- A slight pull signaling resistance, is usually an indication that the clinician has located the canal
- Access to the canal orifice is to be widened using the Gates Glidden drill.
- The use of EDTA alone or RC preparation & NaOcl should facilitate instrumentation.



This Patient Ms. Shanta, age-16, visited BSMMU with the history of trauma on both upper central incisors. Clinically the Rt. Incisor has coronal fracture as shown. She complained of sensitivity of both teeth.

Case 1. Summary:

This Patient Ms. Shanta, age-16, visited BSMMU with the history of trauma on both upper central incisors. Clinically the Rt. Incisor has coronal fracture as shown. She complained of sensitivity of both teeth. Periapical X-ray showed no signs of radiolucency but obliteration of pulp canal of left incisor.

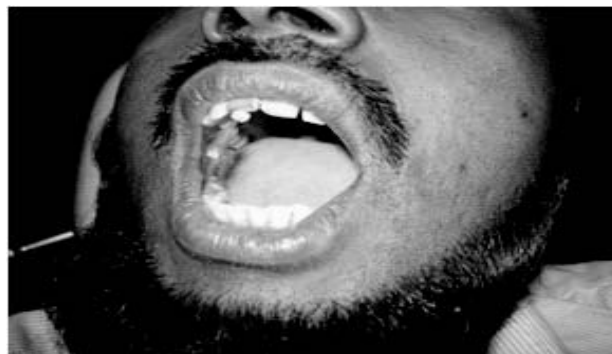

Negotiation of the Case: 1

After gaining access to the Pulp Chamber the canal was searched with a No. 10 file.

- At the very beginning I felt resistance
- However after careful searching a Pathway was found more lingually than the normal direction
- Then the canal was biomechanically prepared using NaOCl, EDTA gel (Irrigating solutions & Chelating agents) & Gates Glidden drills in a contra angle hand piece using slow speed.
- After assessment of the diagnostic length (20 mm) , the root canal was prepared in a step back technique with the gradual increase of file size up to no. 80. After the preparation, the canal was dried & obturated with GP & Zinc-oxide based sealer.

Case 1: X-ray evaluations,



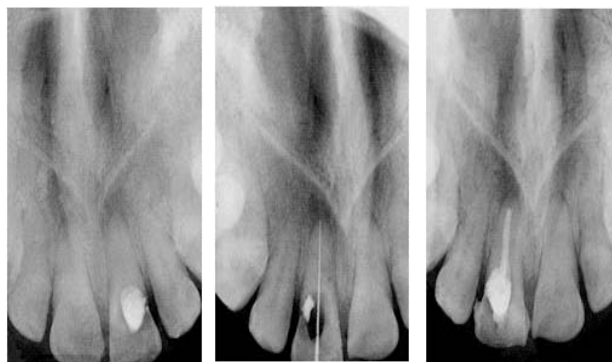After endodontic treatment followed by Pin retained composite restoration.

- After 7 days, finally the fractured crown was restored using pin retention with Photo-cure composite filling material
- Now the patient is under periodic follow up without any complain till now.

Case: 2

This case was previously attempted to treat endodontically ten years back, however, it was a failure case as the clinician could not locate the canal. Later, the patient attended the out patient Dental department of BSMMU.

The case was negotiated using the same procedure as Case: 1 but it was completed in two sittings to avoid any risk using calcium hydro-oxide dressing after the 1st sitting.



Calcified upper central Length measuring X-ray After Obturation

Conclusion:

Undoubtedly, endodontic management of the calcified root canal is a troublesome job in our clinical practice. Considering the etiological factors & patho physiological phenomenon it can be managed predictably with confidence by the application of knowledge, clinical expertisation & implication of new dimensional approaches.

Reference :

1. Pathways of the Pulp, 8th ed. Mosby 1998, Stephen Cohen, Richard C. Burns:p 21-23,447-453,218-2212.
2. Stanley HR , White CL, Mc Cray L; The rate of tertiary (reparative) dentin formation in the human tooth, Oral surg. 21:180, 19663.
3. Stanley HR.et al: The detection and prevalence of reactive and physiologic sclerotic dentin, reparative dentin and dead tracts beneath various types of dental lesions according to tooth surface and age, J oral pathol 12:257, 1983
4. Problem Solving in Endodontics, 4th ed. Mosby 2006,James L. Gutmann,Thom C. Dumsha, Paul E.Lovdahl : p 115-116
5. Dodds RN, Holcomb JB. McVicker DW: Endodontic management of teeth with calcific metamorphosis.
6. Fried K: Changes in pulp nerves with aging, Proc Finn Dental SOC 88 (sup): 517, 1992.
7. Weber DF: Human dentine sclerosis : a m icro radiographic study, Arch Oral Biol 19:163, 1974