

Recent Advancement in the Treatment of Open Apex: Materials and Technique

Dr. S. M. Akkas Ali

BDS, PhD
Assoc. Professor
Dept. of Science of Dental Materials
Dhaka Dental College, Dhaka

Dr. Md. Mukhles-Uz-Zaman

MBBS, MPH
Asst. Professor
Dept. of Community Medicine
Enam Medical College, Savar, Dhaka

Dr. Noor Mohammad

BDS, MDSc
Asst. Professor
Dhaka Dental College, Dhaka

Dr. Shahed Rafi Pavel

BDS, MPH
Lecturer, Dept. of Dental Public Health
City Dental College, Dhaka

Dr. K.M. Mohidul Islam

BDS, MPH
Asst. Professor, Conservative Dentistry
and Radiology
City Dental College, Dhaka

Dr. M. Hadiuzzaman

BDS
Dental Surgeon, Dhaka

Dr. Fahmida Begum

BDS, MPH
Assoc. Professor
University Dental College, Dhaka

Dr. Zakir Hossain Khandaker

BDS, MPH
Former Lecturer
Dhaka Dental College, Dhaka

Correspondence to: Dr. S. M. Akkas Ali
Mobile: 01711133582

Abstract :

Cessation of the root development occurred by traumatic injury and as a sequence of caries prevents obturation of the root canal during endodontic treatment and subsequent treatment like fixed prosthesis. Thus, the goal of apexification was to obtain an apical barrier to prevent the passage of toxins and bacteria into the periapical tissues from the root canal and to induce an apical barrier against which GP points can be condensed. Apexification has been carried out from long time where calcium hydroxide is the widely used material. Calcium hydroxide gained the widest popularity. It is bactericidal in nature with an alkaline pH that may be responsible for stimulating apical calcification. Despite its widest acceptance, it has some disadvantages including variability of treatment time, difficulty in patients follow up, delayed healing, needs multiple visits to the completion to induction of calcific barrier formation and it weakens the dentin of root. Thus, the scientists and clinicians felt urge to introduce new materials and techniques that will help to the quick resolution of the apical radiolucency and to form the apical barrier. MTA (mineral trioxide aggregate), a recently introduced material is successfully used in the treatment of apexification. Many renowned scientists and clinicians worked on this materials and got very good results. Recently a clinical study has been published showing the effects of a combined medicament prepared by mixing calcium hydroxide with cefadroxil on the resolution and formation of apical barrier. Although it was a multi visits treatment compared to the treatment with MTA but showed promising results in the treatment of apexification in presence or absence of radiolucency. Thus, this review article will expose the recently invented materials and techniques which will provide a helpful guide for the clinicians to perform apexification. This review article has been prepared from the internet information and reviewing the recently published papers and texts.

Key words: Blunderbuss, apexification, MTA (mineral trioxide aggregate).

Introduction :

An open apex refers to the absence of sufficient root development to provide a conical taper to the canal and is referred by some as a blunderbuss canal.

This means that the canal is wider towards the apex than it is near the cervical area.

The treatment process which is

long time being followed is called apexification. It is the method to induce development of root apex of an immature pulpless tooth by formation of osteocementum or other bone like tissues to establish an environment that facilitates the closure of the apical opening. Clinicians tried several materials to form apical barrier in the past.

These include: calcium hydroxide paste, calcium hydroxide powder mixed with different vehicles^{1,2,3}, tricalcium phosphate⁴, collagen calcium phosphate⁵, osteogenic protein-1, bone growth factor and oxidized cellulose⁶, proplast, (a polytetrafluor-ethylene and carbon felt-like porous material)⁷, barium hydroxide⁸, true bovine bone ceramics⁹, and dentin chips. Antibacterial paste has been also tried.¹⁰ Deliberate over instrumentation of the periapical area to produce a blood clot that will induce apical closure has also been described.¹¹ Among those materials, Ca(OH)₂ has got widest acceptance to induce bone for the development of calcific barrier. But during the induction period it has to be repeatedly renewed and it can weaken the root apex. Because of these problems associated with Ca(OH)₂, scientists felt urge to introduce new materials and techniques to the treatment of apexification so that apexification can be performed easily with higher success. One of the recently introduced materials is MTA. It was developed at Loma Linda University for use as filling material.¹² It has shown promising results in the successful treatment of apexification.^{13,14}

Bio-resorbable demineralized bone matrix¹⁵ (DBBM) is the protein component of bone and is widely used in various clinical conditions such as periodontal defects and oral maxillofacial bone defects. Periodontal defects grafted with demineralized bone matrix allograft shows histologic evidence of regeneration of new bone and periodontium. Considering its osteoconductive potential and proven success of demineralized bone matrix allograft in the management of periodontal defect, it has been considered as an excellent alternative for the use in the management of large periapical radiolucency.

MTA has the following advantages over Ca(OH)₂ :

1. It can be used as a root canal filling material
2. Repair material for root resorption
3. As pulpotomy medicament because of its excellent sealing capacity in presence of moisture
4. It takes less time to the apexification because it is a single visit medicament
5. It has antimicrobial capacity because of its high pH
6. It neither gets resorbed nor weakens the root canal dentin
7. It is less toxic than the other materials used in pulpal therapy
8. Biocompatible. It is osteoconductive and promotes formation of cementum like hard tissues.
9. This material sets in about three hours to form phase of discrete crystals (mainly calcium and silica and amorphous structures mainly calcium and phosphate).

10. The seal produced by this material is reported superior than that of the other material like amalgam, EBA.

It has shown promising results in the successful treatment of apexification. Jun-Beom and Jeong¹⁶ used this material to the treatment of open apices of maxillary first premolar. He concluded that the use of this material to the treatment of open apex is convenient and effect is pretty good. He followed the conventional method to the preparation of root canal to receive MTA. Guo et al.¹⁷ used this material to the treatment of open apices. He carried out his study on 63 permanent teeth with open apices with periapical periodontitis to observe the effects of MTA. His overall success rate was 95%. Felipe et al.¹⁸ carried out a research on the dog's 20 premolars teeth with open apices to observe the effect of the MTA in the healing of the periapical tissues. They used Ca(OH)₂ and propylene glycol paste. After one week, the former paste was replaced by MTA. He concluded that MTA favoured the occurrence of the apexification and periapical healing.

Recently Akkas et al¹⁹ worked on the apexification process with successful apical barrier formation. He worked with an alternative medicament which was a combination of calcium hydroxide with cefadroxil where local anesthetic solution was the vehicle. The results of this medicament were excellent. He worked on the tooth having blunderbuss apex in presence or absence of radiolucency. The apical barrier formed within 6 months with resolution of radiolucency.

Differences between the apexification process by Ca(OH)₂ and MTA- Various materials have been suggested for use in the apexification process but calcium hydroxide gained the widest popularity. It is bactericidal in nature with an alkaline pH that may be responsible for stimulating apical calcification. Despite its widest acceptance, it has some disadvantages including variability of treatment time, difficulty in patients follow up, delayed healing, needs multiple visits to the completion to induction of calcific barrier formation, may weaken the dentine of root. But in apexification process with calcium hydroxide do not need to place any resorbable material to the open apex as it is indeed in the treatment of apexification with MTA.

The apexification process carried out by Calcium hydroxide is a multi visits system. Here the treatment continues at least 3 -6 months. The dressing is to be changed in every 4 weeks and the result is the resolution of the periapical inflammation and formation of cementoid hard substance. MTA is a single visit medicament. Success rate is high. It is also bactericidal.

Methods to the use of MTA:

Preparation of root canal to place MTA-

1. An accurate radiograph is taken for future reference.
2. Application of the rubber dam or placement of cotton wool rolls on each side of the tooth under operation in presence of high power suction to carry out all the operational procedures in a dry and aseptic environment.
3. Preparation of an optimal access cavity by a suitable sized round diamond bur.
4. Irrigation of the canal thoroughly with 5.2% sodium hypochlorite solution or normal saline.
5. Establishment of the canal length. It should be at least 1-2 mm shorter than the actual tooth length just to avoid the wounding of the apical tissues during filing. Some authors used electric device to the determination of working length. But there is a problem associated with the electric device to the determination of working length of root canal. The canal may be exudative and false reading may be shown by the device.
6. With a large blunted file, the necrotic canal contents are removed and entire perimeter of the canal is thoroughly and circumferentially filed until clean white dentin appears in the reamer. Constantly the canal is to be irrigated to expel out the debris from the canal. The morphology of this canal is different than that of the matured root. Here the root apex is divergent and thus to achieve proper shape of the canal, the reamer should be leaned against the canal walls during filing and debridement.
7. Dry the canal by absorbent paper point or by a plain broach wrapped with cotton. The canal must be dry and sterile before placement of MTA.

Placement of MTA within the canal-

8. Before placing MTA, a synthetic collagen matrix is placed at the apex using hand plugger to produce a barrier at the level of the apex.²⁰ Such bio-resorbable and biocompatible material is essential against which MTA is condensed very gently to control its extrusion.
9. Now paste of MTA is placed against the previously placed collagen material. However, it can be used in powder form. The thickness of the MTA paste should be 3-5 mm. Care should be paid not to extrude the paste beyond the root apex.
10. The blunt end of the absorbent paper moist with water is placed over the MTA for few minutes to promote setting of MTA.
11. Radiograph is taken to confirm adequate placement and thickness of MTA.

12. In the access opening, cotton pellet was placed and the tooth is restored with glass ionomer.

2nd visit to obturate the canal with gutta percha (GP)-

A hand plugger of suitable size is placed within the canal and it is lightly tapped against the compacted MTA to test whether it has set hard or not. If it is found hard then the canal walls are painted with thin mix of ZOE (zinc oxide eugenol) and the canal is sealed with customized GP.

Technique to prepare a customized GP point to seal the canal-

Several GP points are placed in the eucalyptic oil for about 4 seconds in order to soften its surface. Thereafter, upon a sterile glass slab, a mixing spatula is used to shape an appropriate GP point to the diameter of the canal. The shaped GP point is inserted into the canal and condensed. If this oil is not available then several GP points can be attached and soften by passing it over a spirit lamp flame and shaped either by index finger or spatula rolling against the glass slab to the required shape that conforms the shape of the canal.

Apexication method with combined medicament- 1st step

Control of infection-

The access opening and the canal is prepared following the technique as stated above:

1. The tooth is isolated by placing cotton wool rolls on each side of the tooth under operation.
2. The canal is irrigated very gently with normal saline. Exudates of the canal is removed with cotton wrapped in the plain reamer. Irrigation and removal of the exudates are repeated until the canal becomes dry.
3. In the well dried canal, slurry mix of cefadroxil is placed.

Procedure to prepare a slurry mix of cefadroxil

A fresh cefadroxil capsule is opened. Its powder is placed on the sterile glass slab. The glass slab is sterilized by moving it on the spirit lamp flame several times. Now by a sterile cement spatula, the powder particles are minced to fine granules on the cooled glass slab. The fine granules are then mixed with anesthetic solution and mixed to slurry. Now the slurry mix is placed in the canal. Every precaution should be paid to keep the canal clean and dry. The canal is totally filled up with the medicament. The excess liquid is removed by absorbent paper. The access opening is then sealed with ZOE. The patient is dismissed.

4. At the second visit after 7 days: The tooth is isolated and accessed as before. The canal is checked whether it is dry or exudative. At the 2nd visit, if the canal is exudative then the canal is to be irrigated, dried and fresh medicament is to be placed. If the canal is dry then the canal is ready to be subjected to induction. Usually the canal becomes dry within one or two visits in this process of treatment.

Induction step:

Placement of intracanal medicament- The intracanal medicament is a combination of antibiotic of cefadroxil with calcium hydroxide in the proportion of 1:2. The vehicle is local anaesthetic solution. The medicament is very carefully placed within the canal for apexification. The canal is fully packed with the medicament. Excess vehicle is absorbed with absorbent paper point. Every after two month, the patient is checked up and radiograph is taken to examine the improvement. The apexification is successful within 6 months. But if it is not then the process of treatment should be repeated.

Obturation step :

If the radiograph shows formation of apical barrier along the open apex of the root and the patient is totally symptomless then the canal is further debried, clean and obturated with customized warm GP.

Results:

Fig.1(A & B), and 2(A & B) show the results of the apexification that was carried out by the alternative medicament. Although it was a multivisit apexification process but the results was excellent and the failure rate was also very low. Success rate was (85%). Besides, the treatment procedure was also very easy and no elaborate arrangement was required. The results of the single visit apexification carried out by the renowned scientists and clinicians are shown by the Fig.3(A & B). Here the recently developed medicament MTA in conjunction with other material have been used. The single visit apexification results were excellent although there procedure is little technique sensitive and the clinicians should be very much cautious to perform the apexification. The success rate by MTA was 95%.

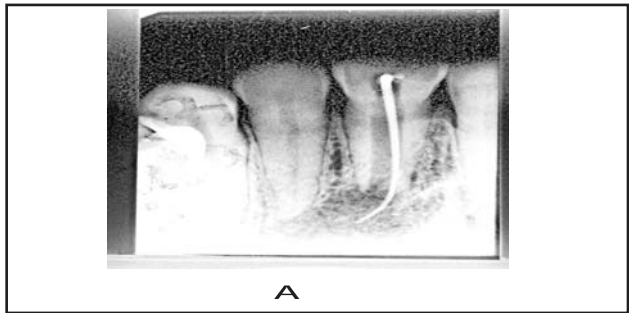


Fig-1. A, Upper central incisor Showing large periapical pathosis with blunderbuss root. The apical radiolucency had the dimension of (14 mm x 7 mm = 98 mm²)

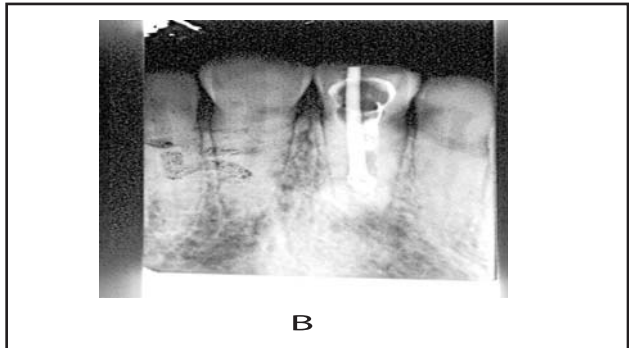


Fig. B, Success of apexification. within 6 months (Medicament : Alternative medicament).

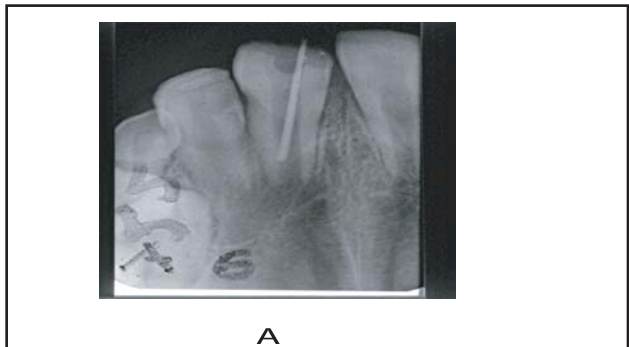
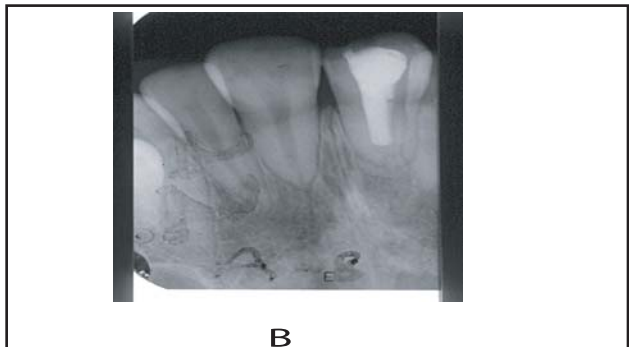


Fig-2. A, Upper central incisor showing large periapical pathosis with blunderbuss root.



B, Success of apexification within 6 months. (Medicament : Alternative medicament).

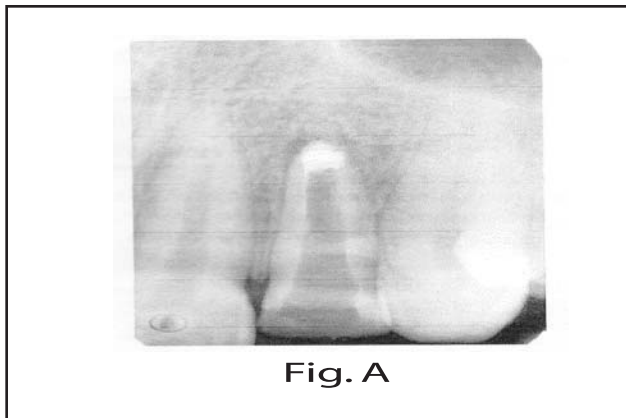



Fig.3. Shows the successful apexification by M.T.A. Fig. A shows the radiograph to confirm placement of M.T.A. apical plug using hand pluggers. Fig. B shows the completed obturation using sealer and injectable thermoplasticized GP.



Discussion :

Treatment of blunderbuss root apex by surgical means is successful but there are some problems associated with surgical approach:

1. Incompletely formed apex has thin fragile dentinal walls that made it difficult to achieve apical seal.
2. To achieve apical seal a larger portion of the soft root has to be removed resulting poor crown /root ratio. The poor crown tooth ratio will hamper the subsequent treatment like fixed prosthesis.
3. The child may not co-operate and thus general anesthesia has to be used to perform surgery.

Most of the clinicians prefer apexification. Researchers accepted the osteogenic potentiality of calcium hydroxide.²¹⁻²⁵ Recent research does not attribute the efficacy of calcium hydroxide to only its pH or antimicrobial activity. Although the alkaline pH could activate alkaline phosphatases which play an important role in hard tissue formation.^{26,27} But it is not free from disadvantages. The patient has to attend several times to receive treatment. Despite the higher success rate of apical barrier formation using calcium hydroxide, long-term follow-up is essential.

Problems such as failure to control infection, recurrence of infection, and cervical root fracture may occur.²⁸

Akkas et al.¹⁹ used a combined medicament to the successful apexification where the main component was Ca(OH)_2 . In their study, they assumed that the cefadroxil, the auxiliary component might have enhanced the activity of Ca(OH)_2 to the barrier formation. So, the successful cases by combined medicament should be under long term post-operative follow up to check the condition and the subsequent treatment like prosthesis should be used as early as possible to prevent fracture.

Apexification using MTA provides an alternative treatment modality in immature pulpless teeth. Apexification with MTA requires significantly less time. MTA has superior biocompatibility and sealing ability and is less cytotoxic than other materials currently used in pulpal therapy. The 5-mm barrier is significantly stronger and shows less microleakage as compared to the 2-mm barrier of MTA. It promotes apexification similar to Ca(OH)_2 . The application of MTA is not so much technique sensitive and thus recently clinicians have concentrated on the use of MTA for apexification.²⁹

However, clinicians during its placement within the canal must be very cautious. They have to place this medicament in a highly dry canal and in an aseptic environment. The common cause of failure is bacterial contamination usually caused by inadequate debridement and dislodgement of the interim restoration. So, the operator should pay attention over these factors.

It has convenience over calcium hydroxide is that it can be used by single visit and the success rate is above 95% as reported by some reporters.

An excellent result came from the combined medicament as reported by Akkas et al.¹⁹ The procedure of this medicament is rather easier than that of the placement of MTA. The only disadvantage related to the combined medicament is that it is a multi visit procedure. Another point should be discussed and that is MTA sets in presence of moisture but it must be condensed against an artificial resorbable matrix that is to be placed before its placement. Calcium Hydroxide should be placed in dry canal to get better function. The clinicians should bring it into account during using these techniques. Another important step of the apexification is the obturation by GP. Barrier may be formed by many materials but this barrier may be partial or complete but constantly there is minute communication with the periapical tissues.

Thus, obturation of the canal should be perfect to prevent the secondary infection. According to different clinicians, success rate of apexification is higher. So, the canal should be obturated by GP. But, as the canal size is little different than the normal so handmade customized GP is to be used. Thus, the clinician should be cautious to prepare a customized GP so that it will obturate the canal perfectly. A perfectly obturated canal will prevent the secondary infection. Despite the higher success rate of apical barrier formation of using calcium hydroxide, long-term follow-up is essential.

Conclusion:

Treatment of blunderbuss root apex is little difficult and thus a great challenge for the clinicians. Tooth associated with such a problem must be treated perfectly to make it ready for the subsequent treatment. Recently the clinicians have concentrated to the treatment of blunderbuss root with MTA. This review article presented the method to the use of MTA. The clinicians can confidentially use MTA to the treatment of blunderbuss root in presence or absence of radiolucency. Combined medicament as stated in the article can also be an alternative medicament to the treatment of apexification. The use of combined medicament is rather easy and the clinicians of all status can use this material.

References:

1. Michanowicz JP, Michanowicz AE. A conservative approach and procedure to fill an incompletely formed root using calcium hydroxide as an adjunct. *J Dent Child* 1967;34:42-7.
2. Pitts DL, Jones JE, Oswald RJ. A histological comparison of calcium hydroxide plugs and dentin plugs used for the control of Guttapercha root canal filling material. *J Endod* 1984;10:283-93.
3. Schumacher JW, Rutledge RE. An alternative to apexification. *J Endod* 1993;19:529-31.
4. Coviello J, Brilliant JD. A preliminary clinical study on the use of tricalciumphosphate as an apical barrier. *J Endod* 1979;5:6-13.
5. Nevins A, Finkelstein F, Laporta R, et al. Induction of hard tissue into pulpless open-apex teeth using collagen-calcium phosphate gel. *J Endod* 1978;4:76-81.
6. Dimashkieh MR. A method of using silver amalgam in routine endodontics, and its use in open apices. *Br Dent J* 1975;138:298-300.
7. Eleazer PD, McDonald TW, Sinai IH, et al. Proplast as an apical barrier in root canal therapy. *J Endod* 1984;10:487-90.
8. Narang R, Wells H. Experimental osteogenesis in periapical areas with decalcified bone matrix. *Oral Surg Oral Med Oral Pathol Oral Radiol Endod* 1973;35:136-43.
9. Yoshida T, Itoh T, Saitoh T, et al. Histopathological study of the use of freeze-dried allogenic dentin powder and True Bone Ceramic as apical barrier materials. *J Endod* 1998;24:581-6.
10. Thibodeau B, Trope M. Pulp revascularization of a necrotic infected immature permanent tooth: Case report and review of the literature. *Pediatr Dent* 2007;29:47-
11. Ham JW, Patterson SS, Michell DF. Induced apical closure of immature pulpless teeth in monkeys. *Oral Surg Oral Med Oral Pathol Oral Radiol Endod* 1972;33:438-
12. Torabinejad M, Hong CU, McDonald F, et al. Physical and chemical properties of a new root-end filling material. *J Endod* 1995;21:349-53.
13. Arcangelo DC, Amario DM. Use of MTA for orthograde obturation of nonvital teeth with open apices: Report of two cases. *Oral Surg Oral Med Oral Pathol Oral Radiol Endod* 2007;104:e98-101.
14. Gutmann JL. The use and predictable placement of Mineral Trioxide Aggregate in one-visit apexification cases. *Aust Endod J* 2003;29:34-42.
15. Mellonig JT. Bone Allografts in periodontal therapy. *Clin Orthop Relat Res* 1996;324:116-25.
16. Jun-Beom and Jeong. Use of mineral trioxide aggregate in the open apex of a maxillary first premolar. *J Oral Science* 2008;50(3):355-358.
17. Guo FQ, Gao YS, Sun Y. Treatment of teeth with open canal system using mineral trioxide aggregate as apical barrier under the dental operating microscope; Stomatological Hospital of Hefei City, Hefei.
18. Fellipe WT, Fellipe MC, Rocha M. The effect of mineral trioxide aggregate on the apexification and periapical healing of teeth with incomplete root formation. *Int Endod J* 2006;39(1):2-9.
19. Parashos P. Apexification: a case report. *Austr J* 1997;42(1):43-6.
20. Mitchell DF, Shankwalker GB. Osteogenic potential of calcium hydroxide and other materials on soft tissue wounds. *J Dent Res* 1958;37:1157-63.
21. Matsumiya S, Kitamura M. Histo-pathological and histo-bacteriological studies of relation between condition of sterilization of the interior of the root canal and healing process of periapical tissues: experimentally infected root canal treatment *Bull Tokyo Dent Coll* 1960;1:1-19.
22. Freeman K, Ludington JR, Svec TA, et al. Continually infused calcium hydroxide: its influence on hard tissue. *J Endod* 1994;20:272-5.
23. Rafter M. Apexification: a review. *Dent Traumatol* 2005;21:1-8.
24. Haga CS, Stern Ph. Responses of osteoblastic cells (UMR 106) exposed to elevated extracellular calcium. *J Endod* 1993;219:462-5.
25. Freeman K, Ludington JR, Svec TA, et al. Continually infused calcium hydroxide its influence on hard tissue repair. *J Endod* 1994; 20:272-5.
26. Hasheminia SM, Norozynasab S, Fezianfard M. The effect of three different calcium hydroxide combinations on root dentin microhardness. *Res J Biol Sci* 2009;4:121-5.
27. Stock CJR. Calcium hydroxide: root resorption and perio-endo lesions. *Br Dent J* 1985;158:325-34.