

## CASE REPORT

# An Unusual Case of Bilateral Bronchiectasis Following Foreign Body Aspiration

Bulbul Parveen<sup>1</sup>, S.M. Abdur Razzaque<sup>2</sup>, Golam Sarwar Liaquat Hossain Bhuiyan<sup>3</sup>, Manoranjan Roy<sup>3</sup>, Nirmal Kanti Sarkar<sup>3</sup>, Goutam Sen<sup>1</sup>, Miraz Mahmud<sup>1</sup>, Md Rowshan Arif<sup>1</sup>, Niaz MD. Mehedi Hasan<sup>4</sup>, Shadia Aroby<sup>4</sup>

### Abstract:

*Foreign body (FB) aspiration can be fatal if it obstructs the glottal opening, larynx, or trachea. Delayed presentations usually occur when the foreign matter obstructs one of the principal or distal bronchi and results in recurrent pneumonia, bronchiectasis, lung abscess or pyopneumothorax. FB aspiration is more common in younger children below the age of three years but not uncommon in older children and young adults. It is an uncommon cause of bronchiectasis. Here, we present a case of a 12 years boy who suffered an incidence of FB aspiration seven months back and presented with bilateral bronchiectasis and pneumonia. Development of bilateral bronchiectasis due to a single airway foreign body is very unusual. Nevertheless, this patient was revealed to have bilateral bronchiectasis along with consolidation.*

**Keywords:** Foreign body aspiration, Bilateral bronchiectasis, Consolidation

[Chest Heart J. 2021; 45(2) : 99-102]

DOI: <http://dx.doi.org/10.33316/chab.j.v45i2.2019643>

### Introduction:

Foreign body (FB) aspiration can be defined as introduction of solid or liquid matter into the airway at the level or below glottis. It can be lodged at larynx, trachea, or bronchi. The complications can be immediate or late. Immediate complications usually occur when the foreign body is lodged in the glottal opening, larynx, or trachea, partially or completely obstructing the airway. Delayed complications usually occur when the foreign matter obstructs one of the main or distal bronchi and results in recurrent pneumonia, bronchiectasis, lung abscess and pyopneumothorax. Bronchiectasis refers to reversible or irreversible dilatation of bronchi due to damage to the bronchial walls.

Common causes are infections, aspiration, defects in host defenses, genetic syndromes, anatomical defects and external airway compression<sup>1</sup>. In contrast, foreign body obstruction is an uncommon cause of bronchiectasis<sup>2</sup>. In this paper, we present a rare case of bilateral bronchiectasis and pneumonia following foreign body aspiration.

### Case Presentation:

A 12 years old boy presented with cough and recurrent episodes of fever for last 7 months. The cough was persistent, productively with large amount of mucoid or mucopurulent sputum production. On this occasion, he was suffering from fever for 7 days which was high grade and continued. He had been

1. Medical Officer, National Institute of Diseases of the Chest and Hospital (NIDCH), Mohakhali, Dhaka.
2. Associate Professor, Respiratory Medicine, NIDCH, Mohakhali, Dhaka.
3. Assistant Professor, Respiratory Medicine, NIDCH, Mohakhali, Dhaka.
4. MD Resident (Phase B), Pulmonology, NIDCH, Mohakhali, Dhaka.

**Correspondence to:** Dr. Bulbul Parveen, Medical Officer, NIDCH, Mohakhali, Dhaka. Cell: 01712754463, e-mail: [bulbulbonny@gmail.com](mailto:bulbulbonny@gmail.com)

**Submission on:** 10 June, 2021

**Accepted for Publication:** 27 June, 2021

Available at <http://www.chabjournal.org>

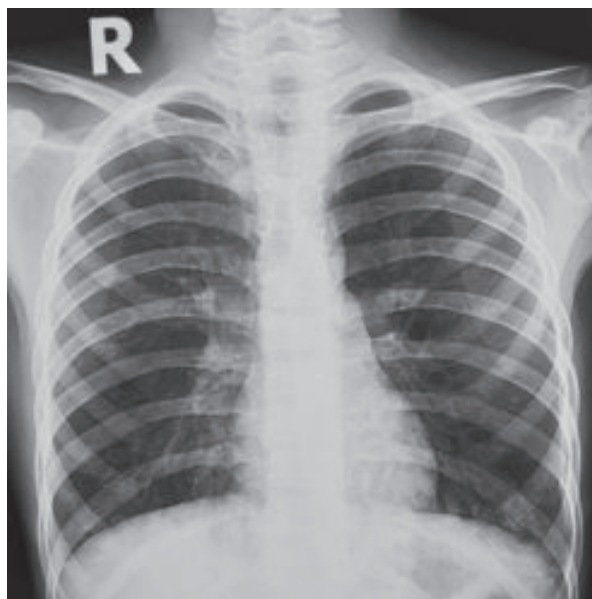suffering from repeated episodes of fever for last seven months. He also complained of shortness of breath for the same duration which is progressive but mostly on exertion. There was no haemoptysis or chest pain.

He gave history of accidental aspiration of a plant seed into the airway followed by choking and coughing seven months back. But as the initial attack was subsided, the incidence was ignored and his parents failed to seek further medical attention at that time. There was no history of recurrent respiratory tract infection prior to the incidence of foreign body aspiration or history of previous pulmonary tuberculosis.

On examination, his vitals were normal except raised temperature. Other parameters of general examination were normal. Examination of his respiratory system revealed bilateral coarse crepitations altered after coughing over lower parts of chest. The patient was given symptomatic management and antibiotic.

His chest x-ray was unremarkable except inhomogeneous opacity in left lower zone. Complete blood count showed neutrophilic leukocytosis with raised ESR. His random blood sugar, serum creatinine and SGPT were normal. Sputum for C/S revealed no growth and sputum Xpert MTB reported as 'not detected'.

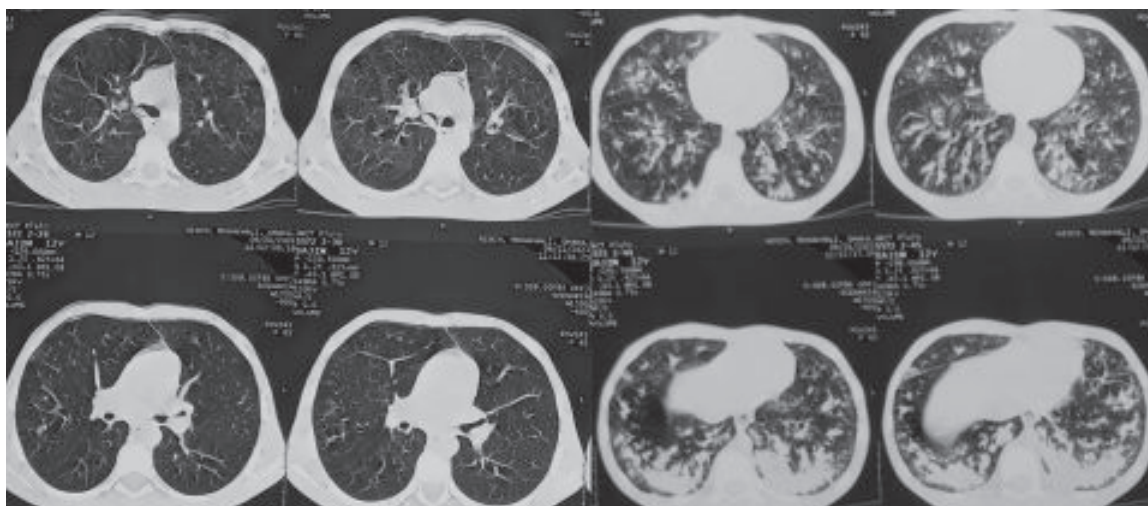
CT scan of chest showed an elliptical structure (Foreign body measuring about 12mm × 4mm) with



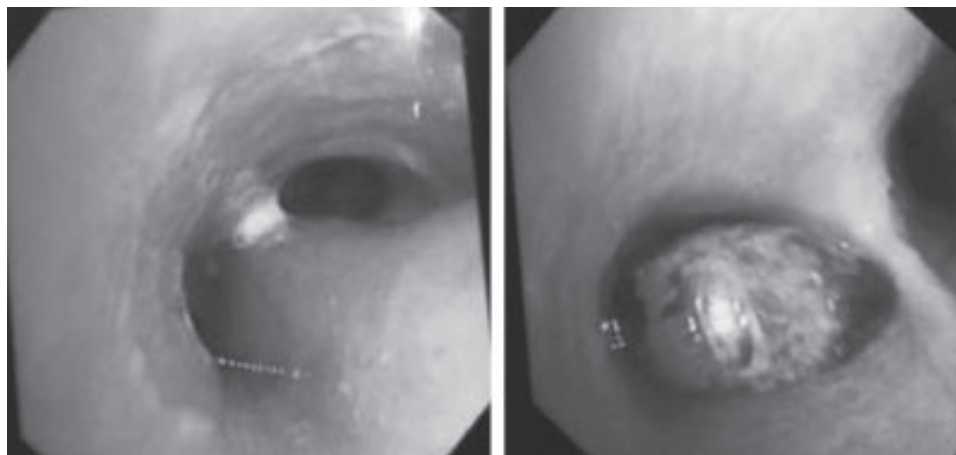
**Fig-1:** Chest X-ray

smooth outline in the most proximal part of right principal bronchus. There were areas of consolidation in lower lobes of both lungs. Bronchiectasis was noted in lingular segment of upper lobe of left lung, middle lobe of right lung and lower lobes of both lungs.

Fiberoptic bronchoscopy (FOB) revealed a mobile foreign body in the proximal bronchial tree. The foreign body could not be removed through FOB. Rigid bronchoscopy was done after four days and the foreign body was extracted without any complication. The patient was discharged two days later and advised for follow up after one month.



**Fig-2:** CT scan of chest showing a foreign body in the proximal part of right principal bronchus (A) and consolidation and bronchiectasis in lower lobes of both lungs (B)



**Fig.-3:** Fiberoptic bronchoscopy (FOB) showing carina (no foreign body) (A) and (after some time) foreign body at the beginning of left principal bronchus (B)

### Discussion:

We reported a case of a 12 years old boy with foreign body aspiration presenting with delayed complications. But airway FB has unique demography where 80% of cases are younger than three years old, with a peak incidence occurring in one to two years old. In a retrospective case series, Asif et al.<sup>3</sup> reported 77.8% of foreign body aspiration in children under five years old, 16% between five and fifteen years and 6.2% by those above fifteen years old. Foreign body inhalation is more common in male children than female.

The variety of clinical presentations and outcomes of FB aspiration depends on many factors like the age of the child, site and extent of airway obstruction, period of foreign body impaction and availability of health care facility<sup>4,5</sup>. The emergency complication of foreign body aspiration is acute respiratory distress leading to death. Non-removal of foreign body leads to various delayed clinical features from simple coughing and wheezing to recurrent or chronic pulmonary infections, bronchiectasis and lung abscess. The diagnosis of a tracheobronchial foreign body requires a high index of suspicion and skill. Early management of FBA can prevent morbidity and mortality due to delayed or inappropriate diagnosis<sup>5,6</sup>. This was a delayed case of FB aspiration presenting with recurrent pneumonia and bilateral bronchiectasis.

The incidence of bronchiectasis following foreign body aspiration is reported to be between 1 to 5.6%<sup>7</sup>. Development of bronchiectasis depends on the size,

shape, localization and retention time of the FB<sup>8</sup>. The type of FB and the time of retention within the bronchial tree are the most important factors. It was reported that the risk of bronchiectasis increases with the retention time from aspiration to diagnosis<sup>9</sup>. In our case, the child presented seven months after the event of FB aspiration.

The diagnosis of FB aspiration requires obtaining a proper history. Whenever a choking episode is mentioned, bronchoscopy is indicated without relying on other diagnostic tools<sup>10,11</sup>. Flexible bronchoscopy is recommended for children newly diagnosed with bronchiectasis to exclude a foreign body or obstructive lesion<sup>12</sup>. Chest X-ray may not be of much help to identify foreign body. CT scan of chest should be performed in patients with chronic and recurrent bouts of cough and also haemoptysis, non-responsive to routine treatment and in case of recurrent or persistent consolidations in the same location. In the mentioned case, chest X-ray was unremarkable except inhomogeneous opacity in left lower zone. CT scan of chest showed an elliptical foreign body at the beginning of the right principal bronchus. CT revealed bilateral bronchiectasis and consolidation in both lungs.

Delayed cases of foreign body aspiration usually present with recurrent pneumonia of the same site or localized unilateral bronchiectasis. But this was a rare presentation of bilateral bronchiectasis and pneumonia following FB aspiration. During fiberoptic bronchoscopy it was observed that the foreign body was mobile, obstructing both the principal

bronchi from time to time. The mobile nature of the FB was probably the reason for the development of bilateral lung disease.

### Conclusion:

Foreign body aspiration into the tracheobronchial tree may result in a wide spectrum of presentations ranging from asymptomatic to death. Many patients do not report an aspiration event. These make the diagnosis of FB aspiration difficult and time consuming. Proper evaluation of suspected cases is very important. Early identification of airway FB and proper management can prevent the irreversible lung damage.

### References:

1. Bush A and Floto RA. Pathophysiology, causes and genetics of Paediatric and adult bronchiectasis. *Respirology*. 2019;24(11): 1053-1062.
2. Brower KS, Del Vecchio MT, Aronoff SC. The etiologies of non-CF bronchiectasis in childhood: a systematic review of 989 subjects. *BMC Pediatrics*. 2014;14(1):4.
3. Asif M, Shah SA, Khan F, Ghani R. Analysis of tracheobronchial foreign bodies with respect to sex, age, type and presentation. *J Ayub Med Coll Abbottabad*. 2007;19(1):13-15.
4. Amer HS, El-Anwar MW, Raafat A, Al Shawadfy M, Sobhy E, Ahmed SA, et al. Laryngo-tracheo-bronchial foreign bodies in children: clinical presentations and complications. *Iran J Otorhinolaryngol*. 2017;29:155-159.
5. Sehgal A, Singh V, Chandra J, Mathur NN. Foreign body aspiration. *Indian Pediatr*. 2002;39:1006-1010.
6. Naragund AI, Mudhol RS, Harugop AS, Patil PH, Hajare PS, Metgudmath VV. Tracheobronchial foreign body aspiration in children: a one-year descriptive study. *Indian J Otolaryngol Head Neck Surg*. 2014;66:180-185. 10.1007/s12070-011-0416-2.
7. Altuntas B, Aydin Y, Eroglu A. Complications of tracheobronchial foreign bodies. *Turkish Journal of Medical Sciences*. 2016;46(3): 795-800.
8. Sirmali M, Turut H, Kisacik E, Findik G, Kaya S, Tastepe I. The relationship between time of admittance and complications in paediatric tracheobronchial foreign body aspiration. *Acta Chirurgica Belgica*. 2005;105(6):631-634.
9. Karakoc F, Cakir E, Ersu R, et al. Late diagnosis of foreign body aspiration in children with chronic respiratory symptoms. *International Journal of Pediatric Otorhinolaryngology*. 2007;71(2):241-246.
10. Boren EJ, Teuber SS, Gershwin ME. A review of non-cystic fibrosis pediatric bronchiectasis. *Clinical Reviews in Allergy and Immunology*. 2008;34(2):260-273.
11. Qiu W, Wu L, Chen Z. Foreign body aspiration in children with negative multidetector computed tomography results: own experience during 2011–2018. *International Journal of Pediatric Otorhinolaryngology*. 2019;124:90-93.
12. Pizzutto SJ, Grimwood K, Bauert P, et al. Bronchoscopy contributes to the clinical management of indigenous children newly diagnosed with bronchiectasis. *Pediatric Pulmonology*. 2013;48(1):67-73.