

Management of Distal Femoral Fracture with Distal Femoral Nail

Jabed Jahangir^{1*}
Md Iqbal Hossain¹
Md Myen Uddin Mojumder²
Mohammad Hossain¹
Md Anwar Hossain¹
Md Imroz Uddin¹

¹Department of Orthopaedics
Chittagong Medical College
Chittagong, Bangladesh.

²Department of Orthopaedics
Chittagong General Hospital
Chittagong, Bangladesh.

*Correspondence to:

Dr. Jabed Jahangir
Assistant Professor
Department of Orthopaedics
Chittagong Medical College
Chittagong, Bangladesh.
Mobile : +88 01711441285
E-mail : jiptmtr@gmail.com

www.banglajol.info/index.php/CMOSHMCJ

Abstract

Background: For a long time distal femur fracture were considered difficult to heal and often led to a degree of disability. The incidence of malunion, nonunion and infection are relatively high in many reported series. The management goal of distal femur fractures are correction of axial alignment, length, and rotation, restoration of motion and rapid union so as to return the patient to normal function. We present here result of retrograde nailing of extra-articular (AO 33A1 to A3) fractures of the distal femur using Distal Femoral Nail (DFN). **Methods:** In Between 2008 to 2010 total 17 patients (One lost to follow up so 16 available for final assessment) underwent open reduction and internal fixation for distal femoral fracture in Chittagong Medical College Hospital and Private Hospital in Chittagong city. There were 13 male and 3 female patients, age range from 18 years to 70 years, mean age 42.75 years. Average length of follow-up was 17.5months (12 months to 24 months). **Results:** Total 16 patients was available for follow up. Regular fracture healing was observed in 14 cases. Delayed union in 2 case. One patient had infection, and two patients had leg shorting of 0.5 and 1 cm. Axial misalignment (Varus/valgus angulations) was found in 4 cases (5°-10°) there were no implant failures. On the bases of a Leung score to measure functional outcome, 4 cases had excellent, 8 cases had good and 4 cases had fair result. Poor results were not seen in any patient. In this series 13 cases were satisfactory and 3 cases were unsatisfactory. **Conclusion:** Distal Femoral Nail is handsome tool to treat distal femoral fracture.

Key words: Distal Femur; Fracture; Distal Femoral Nail (DFN); Internal fixation.

INTRODUCTION

Distal femur fracture comprise 4-6% of all femoral fractures^{1, 2}. There is a bimodal distribution of distal femur fracture in general population, 15-50 years of age, predominantly in males, sustaining high-energy trauma, and 50+ years of age predominantly in females, with osteoporosis, who sustain relatively low energy trauma². Biomechanically the quadriceps, adductors, hamstrings and gastrocnemius muscles can all cause displacement of the fracture fragments³. The gastrocnemius may cause posterior angulation of the distal fragment, overriding can caused by the combined action of the quadriceps and hamstrings. The heads of gastrocnemius may also rotate and spread intercondylar fractures. The adductors may cause varus or valgus deformities, depending on the fracture configuration and its relationship to the adductor tubercle. For a long time they were considered difficult to heal and often led to a degree of disability. These difficulties become greater when they are associated with elderly patients who present with a high degree of osteopenia. So when considering fixation, fixation system needs to be strong enough to resist these deforming forces and yet adaptable enough to deal with the various fracture patterns.

The popliteal artery is relatively fixed and lies in close relation to distal femur and can be damaged by a posteriorly angulated fracture, but this is rare, with an incidence of approximately 0.2%³. Another important consideration is regaining full knee motion and function which may be difficult because of the proximity of these fractures to the knee joint. The incidence of malunion, nonunion and infection are relatively high in many reported series⁴. The goals of management of distal femur fractures are correction of axial alignment, length, and rotation, restoration of motion and rapid union so as to return the patient to normal function⁵. The treatment of distal femoral fractures has undergone a substantial evaluation in the last three decades. Initial publication by Neer, Connolly, Mooney and Stewart and their colleagues conclude that non operative methods primarily traction alone or the combination with a cast, were superior to open reduction and internal fixation. But later work from AO (Arbeitsgemeinschaft für Osteosynthesefragen) group and others with better fixation device and soft tissue handling it was clearly demonstrated that operative treatment is superior to non operative one and has been abandoned as treatment for fractures of the distal femur at the end of 1960ies⁶. For operative treatment many different fixation methods have been described, Angled Blade Plate (ABP) Dynamic Condylar Screw (DCS) Condylar Buttress Plate (CBP) antegrade intramedullary nail, retrograde nail, flexible nail, Minimally Invasive Skeletal Stabilization (LISS) plate, external fixation, total knee replacement⁷. We investigated the feasibility and functional outcome of retrograde nailing of extra-articular (AO 33A1 to A3) fractures of the distal femur using Distal Femoral Nail (DFN).

MATERIALS AND METHODS

It is a prospective study conducted in Chittagong Medical College Hospital and Private Hospital in Chittagong city. Study period from July 2008 - June 2010. Total 17 patients irrespective of sex, with history of the fracture of distal third of femur AO type -A enrolled in the study. One patient lost to follow-up. So, Finally 16 patients available for evaluation. Inclusion criteria was age 18-70 years, fracture involving distal third of femur (AO type A) Closed fractures. Patient excluded if age below 18 years or above 70 years, Open fractures, Pathological fractures, Patients with medical problem eg. DM. Patients were managed according to standard protocol. After initial stabilization of patient complete history of the selected cases were taken. Complete local and general examination done. Radiological and general investigation done and patient was finally prepared for operative treatment. Proper counseling of the patients done regarding operative procedure, its merits and demerits, other surgical options, availability of treatment elsewhere, probable operative and post operative complications that may occur, possible post operative sequels. Informed written consent was taken from each case included in this study. All issues regarding patient's welfare was approved by the local ethical committee. All patients was operated under spinal anaesthesia and was receive prophylactic antibiotics.

Postoperatively limb was elevated on a pillow keeping the knee in 15-20° flexion. The patient was started isometric quadriceps exercises after operation as patient tolerated. After 48 hours, drain was removed. The patient was allowed to move out of bed using crutches and passive range of motion was started. Stitches were removed on the 10th to 14th postoperative day. Patients were follow up clinically and radiologically at 6, 12, 18, 24 weeks. Evaluation of the final outcome was based on the Leung score for distal femoral fractures.

RESULTS

This was a clinical trial carried out at Chittagong Medical College Hospital and Private Hospital Chittagong city from July 2008 to June 2010 involving 17 patients with distal femoral fractures. One patient lost to follow up so ultimately 16 patients available for final assessment. Each patient was treated by open reduction and internal fixation by Distal Femoral Nail (DFN). Average length of follow-up was 17.5months (12 months to 24 months).

Table 1 : Age and sex distribution of study (n=16).

| Age group (Years) | Number of patients | Percentage | Average age (Years) | Sex | |
|-------------------|--------------------|------------|---------------------|------|--------|
| | | | | Male | Female |
| 18-29 | 03 | 18.75% | | 03 | 00 |
| 30-39 | 06 | 37.50% | | 06 | 00 |
| 40-49 | 02 | 12.50% | | 02 | 00 |
| 50-59 | 02 | 12.50% | 42.75 | 00 | 02 |
| 60-70 | 03 | 18.75% | | 02 | 01 |

There were 13 male and 3 female patients, age range from 18 years to 70 years, mean age 42.75 years. Out of 16 patient's 3-drivers, 2-day worker, 2- business man, 2-service holder, 3-students and 3-house wife, others-1.

Table 2 : Mechanism of injury.

| Mechanism | Number of patients | Percentage |
|--|--------------------|------------|
| High energy trauma | 12 | 75.00% |
| Motor vehicle accident | 07 | 43.75% |
| Motor cycle accident | 02 | 12.50% |
| Auto-pedestrian accident | 02 | 12.50% |
| Fall from height | 01 | 6.50% |
| Low energy trauma (Fall from bed, chair) | 04 | 25.00% |

There were 11 patients involving right side and 5 patients involving left side. There was 7 AO type A1 fractures, 6 AO type-A2 fractures, 3 AO type-A3 fractures.

Table 3 : Time and Rate of healing.

| Time of union (Weeks) | No. of patients | Percentage | Union rate (Regular) |
|-----------------------|-----------------|------------|----------------------|
| 12 | 02 | 12.50% | |
| 14 | 04 | 25.00% | |
| 15 | 08 | 50% | 87.50% |
| 25 | 01 | 6.50% | |
| 28 | 01 | 6.50% | |

Regular fracture healing (Formation of circumferential bridging callus across the fracture allowing full weight bearing) was observed in 14 cases. Delayed union (Union time over 24 weeks) was observed in 2 case. Fracture consolidation occurred after an average time of 15.81 weeks (Range 12-28 weeks).

Table 4 : Range of knee motion.

| Range of knee motion | No. of cases | Percentage |
|----------------------|--------------|------------|
| 130-140 | 01 | 6.25% |
| 120°-130° | 02 | 12.50% |
| 110°-120° | 07 | 43.75% |
| 90°-110° | 05 | 31.25% |
| 75°-90° | 01 | 6.25% |

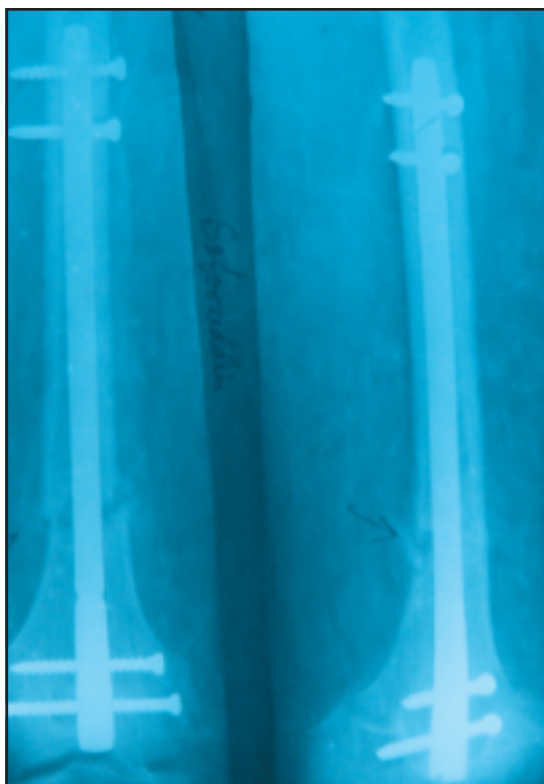


Image 1 : Distal femoral fracture.

Although there were no problem with the wound healing in any patients, two patients had a delayed union, one patient had infection, and two patients had leg shorting of 0.5 and 1 cm. Axial misalignment (Varus/valgus angulations) was found in 4 cases (5°-10°) there were no implant failures. One patient present with wound infection at first follow-up visit. He was treated first with antibiotic according to culture sensitivity. But there was repeated collection, so, debridement done. Patient was ultimately infection free at 16 weeks with delayed union at 28th weeks. On the bases of a Leung score to measure functional outcome, 4 cases had excellent, 8 cases had good and 4 cases had fair result. Poor results were not seen in any patient. In this series 13 cases were satisfactory and 3 cases were unsatisfactory.

DISCUSSION

Retrograde intramedullary nailing was developed in an attempt to overcome the limitations of antegrade nailing. Distal femur fracture where maintaining alignment is difficult with antegrade nailing, in morbid obese patients, fracture involving ipsilateral femur and tibia fracture, multi-system injuries (Necessity of extension table) or distal fracture type and to ensure the advantages of minimal invasive technique in contrast to plate osteosynthesis. While retrograde nailing is an accepted minimally invasive procedure for osteosynthesis of femoral fractures, it's particularly recommended for type 33 A1 to A3 and C1 fractures according to the AO classification⁸. In the present series, the age of the patients varied from minimum 18 years to maximum 70 years, mean age being 42.75 years. Similar findings were also been noted by Seifert et al, Leung et al and Gellman et al were 44 years (Range 17-92 years) 46.5 years (Rang 22-85years) and 50 years (Range 26-84 years) respectively⁹⁻¹¹. The mechanism of injury and the bimodal distribution of high energy fractures occurring in younger males and the low energy fractures in elderly females were comparable with previous studies. Period of fracture healing was average 17.5 weeks (Range 8-68 weeks) in the series of Handolin et al, average 12 weeks (Range 8-24 weeks) in Leung et al series and average 12.5 weeks (Range 8-16 weeks) in the series of Gellman et al^{12,10,11}. Average healing time in our series was 15.81 weeks (Range 12-28 weeks). 87.50 percent of the fracture were united in this series and were capable of full weight bearing. 100 percent of the fractures were healed in the series of Seifert et al, Gellman et al and Grass et al^{9,11,13}. But in the in series of Handolin et al 95 percent of the fractures were healed in regular healing time (Less than 24 weeks)¹². No nonunion occurred in present series. Similar finding were found in the series of Seifert et al, Grass et al and Gellman et al^{9,13,11}. But Ostrum et al, Ricci et al, Handolin et al found nonunion of 6%, 6% and 4.7% cases respectively in their series^{14,15,12}. Delayed union occurred in 2 patients (12.50%) in this series and ultimately healed. Similar finding was found in the series

