

Inguinal Lymphatic Malformation: A Rare Case Report

Musrat Rahman^{1*}
SAM Alim²
Morsheda Akhter³
Shahana Sultana⁴

¹Department of Pediatric Surgery
Ad-din Women's Medical College Hospital
Dhaka, Bangladesh.

²Department of Anaesthesiology
Ad-din Women's Medical College Hospital
Dhaka, Bangladesh.

³Department of Microbiology
Ad-din Women's Medical College Hospital
Dhaka, Bangladesh.

⁴Department of Surgery
Ad-din Women's Medical College Hospital
Dhaka, Bangladesh.

*Correspondence to:

Dr. Musrat Rahman
Associate Professor & Head
Department of Pediatric Surgery
Ad-din Women's Medical College Hospital
Dhaka, Bangladesh.
Mobile: +880-1720581711
E-mail: musrat.deeba@gmail.com

Abstract

Lymphatic malformation are most commonly located in regions of confluence of major lymphatic channels, including the neck (75%), axilla (20%), mediastinum, retroperitoneum, pelvis and groin. We are reporting here a very rare case in which a 15 months old boy presented with a painless lump in the right groin. Preoperative imaging, exploration, macroscopic and microscopic examination of the excised specimen revealed it a case of lymphatic malformation (cystic hygroma). This case is unique in terms of site of presentation.

Key words : Lymphatic malformation; lymphangiomas; hygromas.

INTRODUCTION

Lymphatic malformations have traditionally been called cystic hygromas or lymphangiomas. Lymphatic malformations represent morphogenic errors in the development of the lymphatic vessels. Most commonly, those with large cysts have been called hygromas and those with more tissue parenchyma have been called lymphangiomas. They are most commonly located in regions of confluence of major lymphatic channels, including the neck (75%), axilla (20%), mediastinum, retroperitoneum, pelvis and groin. Malformations may be detected antenatally and are usually visible at birth.

These vascular anomalies may become infected or sustain intralesional hemorrhage in addition to causing disfigurement.

Predominantly macrocystic lymphatic malformations may often be successfully treated with cautious intralesional sclerotherapy. Sclerosants employed include ethanol, doxycycline, sodium tetradecyl sulfate, and OK-432(a killed strain of group-A streptococcus). Sclerotherapy is best performed under fluoroscopic guidance. Persistent malformation and recurrent swelling are unfortunately common after sclerotherapy.

Surgical resection is the only way to "cure" these malformations. The strategy should be to perform as thorough a resection as possible in a single anatomic region at each operative procedure. Extensive lesions cannot usually be removed completely, even with multiple procedures. Excision may result in a number of potential complications. Re-enlargement of residual lesion is not uncommon if an anatomic region is not adequately resected. Malformations tend to invest normal structures. Thus injury to vital structures may occur. Great care must be taken to avoid injury to vital structures. Bleeding should be minimal, with blood transfusion rarely necessary. Mortality is not expected.

CASE REPORT

A 9months old Bangladeshi boy presented with history of a slowly progressive swelling in the right inguinal region since birth (Figure-1). The physical examination revealed a large non-tender, softly cystic swelling which was irreducible and did not have any impulse on coughing. The ultrasound examination revealed a large multiloculated cystic mass. Decision was made to perform an inguinal exploration.



Figure 1: Inguinal Cystic Hygroma (Pre-operative)

Surgery was performed through the right inguinal incision. A large multicystic mass measuring 7 cm x 4 cm x 2 cm (Figure 2) was found in the subcutaneous

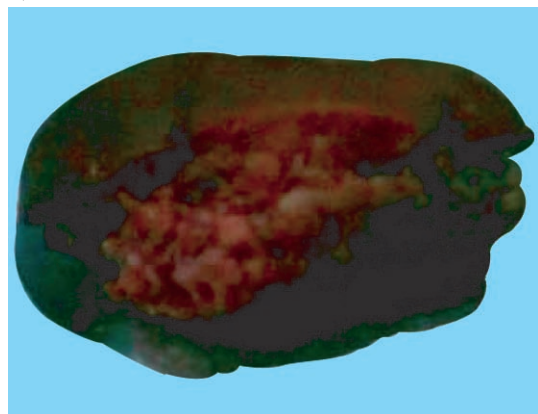


Figure 2: Excised specimen of Inguinal Cystic Hygroma

plane superficial to the external oblique aponeurosis. The mass was carefully excised by preserving the structures of the spermatic cord. On gross examination, the multicystic mass was well defined but there was no capsule and was filled with clear fluid. On microscopic examination, sections show many cystic spaces lined by single layer of endothelium suggestive of cystic hygroma (lymphangioma). The patient was discharged on the 4th post-operative day and the post-operative course was largely uneventful. During follow-up period, after one year the patient was completely alright without any sign of recurrence (Figure 3).

DISCUSSION

Cystic swellings during inguinal dissection are rare to find¹. Although hernia is the most common abnormality of the inguinal region², other pathological entities may also be found

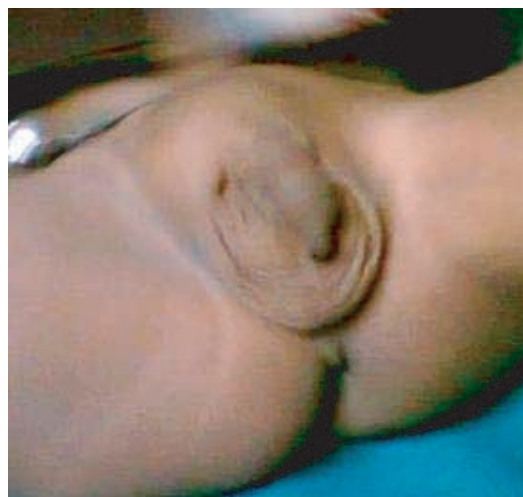

Figure 3: Follow-up after one year of surgery

in this area³. Lymphangiomas are malformations of the lymphatic system that occur as a result of the failure of lymph to drain from sequestered lymphatic vessels with consequent dilatation of the ducts and formation of a cystic mass. Majority of these lesions are congenital but they may also occur secondary to trauma, infection, inflammation or degeneration. Most commonly, those with large cysts have been called hygromas and those with more tissue parenchyma have been called lymphangiomas. Both terms are antiquated and should be abandoned. The International Society for the Study of Vascular Anomalies (ISSVA) has accepted the terminology proposed by Mulliken in 1982 more appropriately describing these lesions as lymphatic malformations⁴⁻⁶. They are subdivided into macrocystic, microcystic and combined varieties. They usually appear on the neck (75%), armpit or groin areas. They often look like swollen bulges underneath the skin. Draining lymphangiomas of fluid provides only temporary relief, so they are removed surgically. Ultrasonography is very accurate at identifying the cystic nature of the swelling and marking the extent of the lesion. The final diagnosis is usually made only after the histopathologic examination. In conclusion, we have presented a rare case of a large lymphangiomas presenting at an unusual site and mimicking an irreducible inguinal hernia. Although rare, this lesion must always be kept as a differential diagnosis while dealing with cystic inguinal masses. Ultrasonography is helpful in delineating the cystic nature and extent of the lesion whereas surgery remains the mainstay of treatment.

CONCLUSION

Although hernia is the most common abnormality of the inguinal region, other pathological entities may also be found in the area. Some of these may mimic an irreducible inguinal hernia and pose an initial diagnostic dilemma. Cystic hygroma in inguinal region is a rare entity, but we can find it. So, we should always keep in mind when we deal with an irreducible inguinal mass.

REFERENCES

1. Welch B, Barton TK. Inguinal cord cysts, *Hernia* 2002; 6:33-5.
2. Yang DM, Kim HC, Lim JW, Jin W, Ryu CW, Kim GY et al. Sonographic findings of groin masses. *J Ultrasound Med* 2007;26:605-14.
3. Poenaru D, Jacobs DA, Kamal I. Unusual findings in the inguinal canal: a report of four cases. *Pediatr Surg Int* 1999;15:515-6.
4. Leeming R, Olsen M, Ponsky. Inguinal dermoid cyst presenting as an incarcerated inguinal hernia. *J Pediatr Surg* 1992;27:117-8.
5. Salemis NS, Karagkiouzis G, Sambaziotis D, Tsiambas E. Large dermoid cyst of the spermatic cord presenting as an incarcerated hernia: a rare presentation and literature review. *Hernia* 2010;14:321-3.
6. Mulliken JB, Fishman SJ, Burrows PE. Vascular anomalies. *Current Problems in Surgery* 2000; 37: 517-84.