

# Prenatal Diagnosis of Prepyloric Diaphragm: A Case Report

Md. Qumrul Ahsan<sup>1</sup>  
Arni Das<sup>2</sup>  
Tahmina Banu<sup>2\*</sup>

<sup>1</sup>Department of Radiology and Imaging,  
Chattogram Maa-O-Shishu Hospital Medical College,  
Chattogram, Bangladesh.

<sup>2</sup>Chattogram Research Institute for Children Surgery (CRICS),  
Chattogram, Bangladesh.

## Abstract

*The prepyloric diaphragm (A type of pyloric atresia) is a rare type of congenital malformation of gastrointestinal tract of unknown etiology. A thin two layered mucus membrane of about 2 to 4 mm, proximal to pylorus causes the gastric outlet obstruction in neonate. We are reporting a case of prepyloric diaphragm which had been diagnosed at 37 weeks of gestation by Ultrasonography and diagnosis was confirmed after birth during surgery. Prenatal ultrasonography of a 37 weeks pregnant mother revealed polyhydramnios, persistently dilated, a fluid filled blind sac at epigastrium and right hypochondrium with peristaltic wave and to & fro movements of fluid contents. There was no double bubble sign. The baby boy was born by Caesarean Section. After breast feeding, baby had non-bilious vomiting with mild abdominal distension. Postnatal ultrasonography showed dilated fluid filled stomach. Exploratory laparotomy on 14<sup>th</sup> day of life revealed a prepyloric diaphragm with a central hole, 1 cm proximal to the pylorus. The 2 mm thick diaphragm was excised circumferentially. Postoperative period was uneventful. Milk feeding started at 6<sup>th</sup> post-operative day and discharged with advice at 7<sup>th</sup> post-operative day. Prepyloric diaphragm or antral web is to be considered as provisional diagnosis if there is prenatal suspicion of gastric outlet obstruction, polyhydramnios of mother and persistent non-bilious vomiting in neonate; as simple excision of the diaphragm is curative for this unusual abnormality if there is no other associated abnormality.*

**Key words:** Prenatal Diagnosis; Antral web; Prepyloric diaphragm; Pyloric Atresia.

## INTRODUCTION

Congenital prepyloric diaphragm or antral web (A type of pyloric atresia) is a rare cause of gastric outlet obstruction in neonate which is seen in one in 100,000 live births<sup>1</sup>. A circumferential thin fenestrated diaphragm of two layers of mucosa causes the obstruction in the pyloric region of stomach<sup>2</sup>. Due to similar ultrasonographic findings of congenital pyloric diaphragm, pyloric atresia and prepyloric antral diaphragm, prenatal diagnosis may be difficult. So diagnosis is confirmed usually after operation<sup>3,4</sup>. We present a case report of congenital prepyloric diaphragm which has been suspected in prenatal period at 37 weeks of gestation by Ultrasonography and confirmed our diagnosis during surgery.

## CASE REPORT

Ultrasonography of a 31-year old pregnant mother at 37 weeks of gestation (Fig 1, 2, 3) showed single viable fetus with persistently dilated, seems to be a fluid filled blind sac at epigastric and right hypochondrium with peristaltic wave and to & fro movement of fluid contents with polyhydramnios (Amniotic Fluid Index 29 cm). Fetal weight was 3025 gm. No other abnormality was seen in the ultrasonography. Ultrasonographic diagnosis was gastric outlet obstruction in the fetal abdomen.

\*Correspondence to:

**Professor (Dr) Tahmina Banu**  
Director  
Chattogram Research Institute for Children Surgery (CRICS)  
Chattogram, Bangladesh.  
Mobile : +88 01711 72 06 35  
Email: profahmina@gmail.com

Date of Submission : 10.05.2019  
Date of Acceptance : 30.06.2019

[www.banglajol.info/index.php/CMOSHMCJ](http://www.banglajol.info/index.php/CMOSHMCJ)

Ultrasonography reviewed after one week and revealed single viable fetus of 38 weeks of gestational age with same findings. Fetal weight was 3092 gm. There was no history of consanguinity among parents of the baby. The baby was otherwise healthy and no other abnormalities found in imaging evaluation.

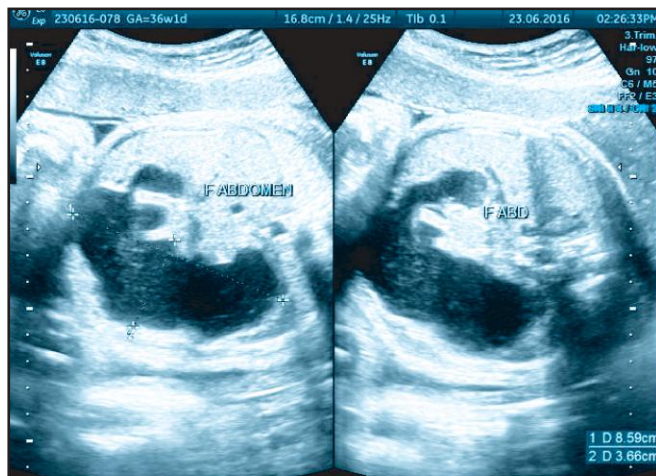

Figure 1 : Ultrasonography of abdomen at 37 weeks of gestation

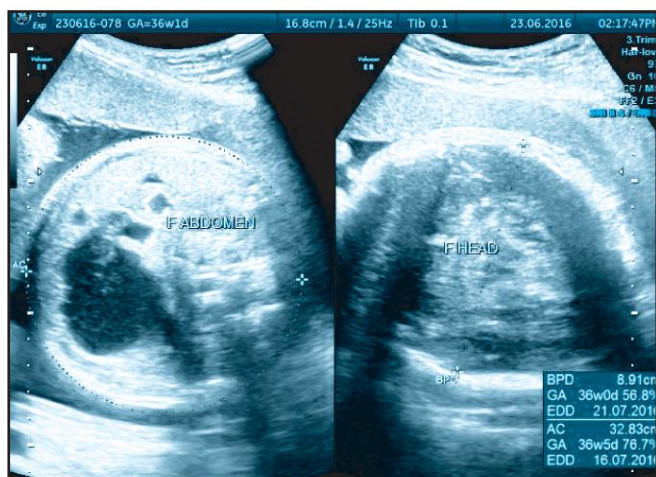


Figure 2 : Ultrasonography of abdomen at 37 weeks of gestation

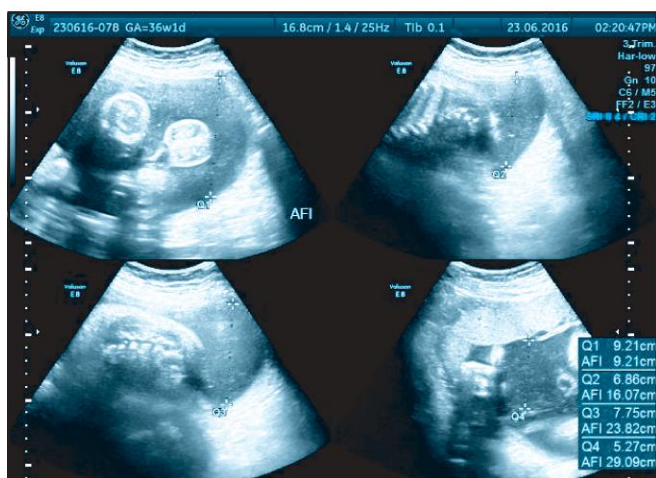


Figure 3 : Ultrasonography of abdomen at 37 weeks of gestation

One day later the patient was admitted in a private hospital with Ante partum haemorrhage and less fetal movement. Emergency Lower Segment Caesarean Section (LSCS) was done and a healthy male baby was delivered. Birth weight was 3 kg. Clinically there was no evidence of other abnormalities.

His postnatal Ultrasonography showed persistently dilated stomach with peristaltic wave and to and fro movement of fluid contents. There was no double bubble sign. The baby started persistent non bilious projectile vomiting from day 3 immediately after feeding.

The baby underwent exploratory laparotomy on 13<sup>th</sup> day of life infiltrating local anesthesia. During operation, a prepyloric diaphragm with central hole one cm proximal to the pylorus was found with Meckel's diverticulum & malrotation. Excision of Pyloric diaphragm and Meckel's diverticulum with correction of malrotation was done. Both per operative and post-operative period were uneventful, he recovered well, started feeding from 6<sup>th</sup> postoperative day and was discharged on 7<sup>th</sup> post-operative day.

Follow up after 1 month 4 days, Baby was healthy with no history of vomiting with normal bowel movement and micturition. Ultrasonographic scan was done before and after breast feeding. Stomach was found dilated with free passage of fluid from stomach to duodenum. Two years follow up showed the baby was growing well, lively with no complaints.

## DISCUSSION

In 1937, the first case of pyloric atresia or prepyloric diaphragm was reported by Bennett<sup>5</sup>. Gerber first classified this rare anomaly which causes gastric outlet obstruction on the basis of gross anatomy in 1965<sup>1</sup>. The exact etiology is still not known but there are several theories like rapid proliferation of epithelial cells, incomplete re-vacuolization that cause remnant left in the gastro-intestinal tract during 2<sup>nd</sup> month of embryogenesis<sup>6</sup>. Main symptoms of prepyloric diaphragm in child are upper abdominal distension, persistent bile free vomiting and polyhydramnios of mother which is usually found in more than 50% cases during antenatal period and in our case we found mild polyhydramnios of mother at 37<sup>th</sup> gestational weeks<sup>7-9</sup>. Lloyd described due to obstruction in the proximal portion of gastrointestinal tract fetus usually fails to transport amniotic fluid that leads to polyhydramnios<sup>10</sup>. Prognosis of this rare disease depends on early diagnosis and associated congenital anomalies. Kodoma et al. reported 38.8% mortality rate has been found in children with congenital web or diaphragm and mortality rate goes up if there are other gastrointestinal anomalies (92.1%)<sup>11</sup>. Affected neonates usually die due to respiratory distress, aspiration pneumonia, metabolic alkalosis resulting from persistent vomiting, and even gastric perforation<sup>11</sup>. Meckel's Diverticulum and malrotation have been found as associated anomalies during surgery in our case. In our patient the diagnosis was done during prenatal period and operation was done earlier in the post natal period. The

outcome was excellent. Surgical options depend on the anatomy of anomaly such as antroplasty or web excision with or without pyloroplasty<sup>1</sup>. If endoscopic intervention is feasible it can be another option for surgical treatment. We did circumferential web excision without pyloroplasty. Polyhydramnios of mother, dilated blind fluid filled sac of fetal upper abdomen, absence of double bubble sign in antenatal ultrasonography should raise suspicion of prepyloric diaphragm. Awareness of this rare congenital anomaly of gastrointestinal tract can lead early surgical correction with favorable outcome.

#### Ethical Issue

Informed consent was taken from both parents. Confidentiality was maintained strictly.

#### CONCLUSION

The procedure performed in human participant was in accordance with the ethical standards of the institutional research committee and with the 1964 Helsinki declaration and its later amendments or comparable ethical standards. This article does not contain any studies with animals performed by any other authors.

#### DISCLOSURE

All the authors declared no competing interest.

## REFERENCES

1. Gerber BC. Prepyloric diaphragm, an unusual abnormality. A case report. *Arch Surg.* 1965;90:472–480.
2. Bell MJ, Ternberg JL, McAlister W, Keating JP, Tedesco FJ. Antral Diaphragm -- a cause of gastric outlet obstruction in infants and children. *J Pediatr.* 1977;90:196–202.
3. Lui KW, Wong HF, Wan YL, Hung CF, Ng KK, Tseng JH. Antral web – a rare cause of vomiting in Children. *Pediatric Sug Int.* 2000; 16: 424 -425.
4. Sharony R, Sinow R, Asch M, Lachman R. Prenatal ultrasound diagnosis of gastric outlet obstruction due to a pyloric web. *Prenat.Diagn.* 1995; 15: 56-59.
5. Bennett RJ. Jr. Atresia of Pylorus. *Amer J Dig Dis.* 1937; 4:44. 1937.
6. Hait G. Prepyloric Mucosal Diaphragm (Antral Web). *Archives of Surgery.* 1972; 105(3): 486.
7. Kume K, Ikeda K, Hayashida Y, Naito K, Teraoka H, Nishibayashi Y, Nagai S. Congenital Pyloric atresia. A report of three cases and review of literature. *J. Jpn. Soc. Pediatr. Surg.* 1980;16:259-268.
8. Bronsther B, Nadeau MR, Abrams MW. Congenital pyloric atresia, A report of three cases and areview of the literature. *Surgery.* 1971;69:130-136.
9. Tan K, Murugasu JJ. Congenital pyloric atresia in siblings. *Arch. Surg.* 1973;106:100 -102.
10. Lloyd JR, Clatworthy HW. Hydramnios as an aid to the early diagnosis of congenital obstruction of the alimentary tract; A study of the maternal and fetal factors. *Pediatrics,* 1958;21:903-909.PMID:13553578.
11. Kodama Y, Kawamoto M, Iwashita K, Fujisaki T, Tazaki K, Kawamura K, Horikoshi Y, Kawabata T, Shoji T Congenital pyloric atresia.A report on a successfully treated case and existing research. *Journal of Nippon Medical School.* 1986; 53(4):409-415.