

# Advanced Abdominal Pregnancy of 32 Weeks with Alive Baby: A Rare Event

Adiba Malik<sup>1\*</sup>

<sup>1</sup>Department of Obstetrics & Gynaecology  
Chattogram Maa-O-Shishu Hospital Medical College  
Chattogram, Bangladesh.

## Abstract

**Background:** Abdominal pregnancy is a rare form of ectopic or extrauterine pregnancy with an incidence of 1:10000 and 1:30000. Advanced abdominal pregnancy is extremely rare with high maternal and perinatal mortality.

**Case Presentation:** We report a case of abdominal pregnancy at 32 weeks gestation with persistent abdominal pain and severe anemia, who was referred from another hospital to our center with an Ultrasonogram, missed the diagnosis of abdominal pregnancy, which was confirmed in our center as abdominal pregnancy at 32 weeks with live fetus. With laparotomy a 1.2 kg female baby was born without much difficulty and post operative recovery was uneventful. But the baby died at 27<sup>th</sup> post operative day.

**Conclusion:** High index of clinical suspicion is necessary for early diagnosis of abdominal pregnancy and timely laparotomy with multidisciplinary surgical team can save the life of a mother.

**Key words:** Abdominal pregnancy; Alive baby; Uterus.

## INTRODUCTION

Abdominal pregnancy is an extremely rare form of extrauterine or ectopic pregnancy.<sup>1</sup> Advanced abdominal pregnancy is defined as pregnancy go beyond 20 weeks with signs of alive fetus anywhere in the peritoneal cavity exclusive of tubal, ovarian or broad ligament.<sup>2</sup> Pouch of douglas is the most common location of abdominal pregnancy followed by mesosalpings and omentum. Incidence of abdominal pregnancy differs in various publications and ranges between 1: 10000 and 1: 30000 pregnancies.<sup>3</sup> The incidence is high in developing countries due to high rate of pelvic inflammatory disease and pelvic infection and pregnancy with Intra uterine contraceptive device. Abdominal pregnancy has a maternal mortality of 0.5 to 18% and perinatal mortality 40- 95%.<sup>4</sup> High rate of morbidity and mortality often results from delay in diagnosis. The placenta can be attached to the uterine wall, bowel, mesentery, bladder and has a good blood supply to maintain fetal growth and development. But it can detach at any time during pregnancy leading to torrential blood loss and maternal death.<sup>5</sup> Abdominal pregnancy is classified as primary and secondary. Most are secondary due to early tubal abortion or rupture with secondary implantation into the peritoneal cavity.<sup>6</sup> Persistent abdominal pain is present in 80% of cases often noticed from early pregnancy.<sup>7</sup> Fetal movements may be painful or absent in case of fetal death and there may be history of vaginal bleeding early in pregnancy.<sup>8</sup>

High index of suspicion and a good Ultrasonogram can diagnose abdominal pregnancy early before serious complications arise and that can save the life of a mother.

\*Correspondence to:

**Dr. Adiba Malik**

Associate Professor

Department of Obstetrics & Gynaecology

Chattogram Maa-O-Shishu Hospital Medical College

Chattogram, Bangladesh.

Mobile : +88 01817 73 26 98

Email : dradibamalik@yahoo.com

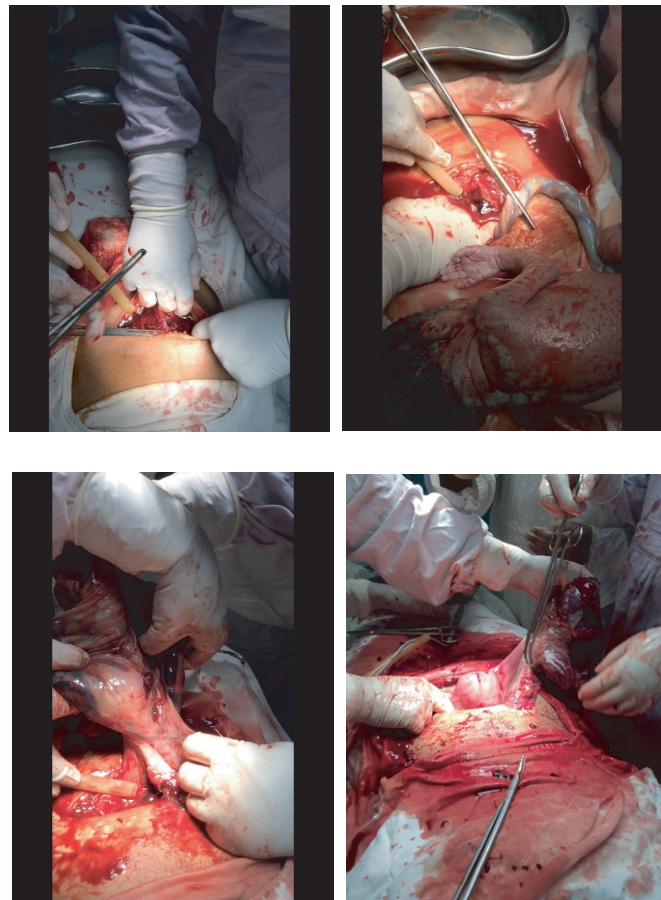
Date of Submission : 12.11.2022

Date of Acceptance : 10.12.2022

[www.banglajol.info/index.php/CMOSHMCJ](http://www.banglajol.info/index.php/CMOSHMCJ)

### CASE PRESENTATION

We present a 22 years primi gravida admitted on 2<sup>nd</sup> September 2021 at 2.18 pm at CHATTAGRAM Maa-O-Shishu Hospital Medical College (CMOSHMC) at 32 weeks pregnancy with persistent abdominal pain, severe anemia, less fetal movement and respiratory distress. She was referred to our hospital from periphery hospital with an Ultrasonogram showed 32 weeks intrauterine pregnancy. The patient also gave history of persistent abdominal pain from early pregnancy and occasional vaginal bleeding. On examination she was malnourished, severely anemic, Pulse 118/minute, Blood pressure 90/60 mm of Hg, Lungs- clear, Oxygen saturation 87% on room air, temperature normal and other general examination findings were normal. Abdominal examination revealed Uterus 32 weeks size with palpable fetal parts in the right side of the flank and fetal heart sound was present. On vaginal examination, cervical os was closed with high up presenting part. Immediately Oxygen was given, we sent urgent CBC which showed Hemoglobin 04 gm/dl. 3 units packed red blood cell was slowly given. Her Rapid antigen test was negative. An Ultrasonogram in our hospital revealed 32 weeks extrauterine abdominal pregnancy with alive fetus and minimal ascites with the impression of amniotic cavity containing single live fetus outside the uterus covering the pelvis and abdomen extending upto epigastric region, fetal cardiac pulsation present, placenta anterior, amniotic fluid adequate. We gave Injection Dexamethasone and counselling done for laparotomy. With 4 units of cross matched blood and informing general surgeons, Urologist and Neonatologist, patient underwent laparotomy. On opening of abdomen there was blood stained ascitic fluid with a leaky amniotic cavity. After amniotomy a 1.2 kg female baby was born and immediately managed and shifted to NICU. The placenta was attached with the omentum, broad ligament and dilated fallopian tube of right side. As placenta was densely adherent with right tube, right salpingectomy and partial omentectomy was done and was safely removed with out much bleeding. Uterus was slightly enlarged, both ovaries and left tube was healthy. After proper hemostasis abdomen was closed keeping a drain in situ. Patients post operative period was uneventful. But the baby was not improving in NICU and the diagnosis of preterm, IUGR with neonatal sepsis. After prolonged hospital stay on 25<sup>th</sup> post operative day they discharge the baby with risk bond and the died at home on 27<sup>th</sup> post operative day.



**Image 1** Steps of operation

### DISCUSSION

Advanced abdominal pregnancy with alive fetus is a rare event. A review of literature from 2008 to 2013 showed that 38 cases of advanced abdominal pregnancy resulting in live birth were identified from 16 countries.<sup>9</sup> Diagnosis of abdominal pregnancy was commonly missed or delayed due to varied and non specific presentations. The patient of abdominal pregnancy typically have persistent abdominal pain through out pregnancy which was similar to our patient.<sup>7,8,9</sup> With alive fetus fetal movement is painful and it was true in our case.<sup>7,8</sup> Abdominal tenderness and easily palpable fetal parts are present in abdominal pregnancy and that was also seen in our patient.<sup>7,8</sup> Ultrasonogram is the most effective method for diagnosis of abdominal pregnancy. But even in ideal condition, a sonographic diagnosis is missed in half of the cases, which was also happened in our patient as the first ultrasonography suggested intrauterine pregnancy.<sup>10,11</sup> An ultrasonogram may reveal one or more of the following features: The fetal head located outside the uterus, the fetal body outside the uterus, an ectopic placenta, failure to demonstrate the uterine wall between the fetus and the urinary bladder and recognition of a close approximation of fetal parts and the maternal abdominal wall.<sup>12</sup> A high index of suspicion is important for early clinical diagnosis. An Oxitocin stimulation test and the finding of

abnormally high serum alpha fetoprotein have been proposed.<sup>13</sup> The treatment of abdominal pregnancy has traditionally been laparotomy and the favourable outcome depend on availability of safe blood transfusion, accessibility of multidisciplinary surgical team if needed. The timing and nature of intervention will depend on the gestational age and the viability of the fetus at the time of diagnosis.<sup>8</sup> Bleeding from the placental site can be life threatening. Placental management should be individualized. The placenta should only be removed if it is safe to do so. If the blood supply of the placenta can be safely secured complete removal of placenta usually results in uncomplicated post operative recovery, which was true in our case.<sup>13</sup> Occasionally it may be necessary to ligate the placental blood supply and remove the pelvic organs upon which placenta has implanted that is hysterectomy, which leads to end of obstetric future of a woman, salpingoophorectomy, omentectomy, resection of gut or bladder. It also imposes financial burden in terms of prolong hospital stay, need of ICU, NICU, multidisciplinary surgical team.

## CONCLUSION

Advanced abdominal pregnancy is an extremely rare condition with high maternal and perinatal morbidity and mortality. High clinical index of suspicion and a good Ultrasonogram can diagnose abdominal pregnancy earlier. Timely and effective management by multidisciplinary surgical team can save the life of a mother.

## DISCLOSURE

The author declared no competing interest.

## REFERENCES

1. Yildizhan R et al. Primary omental pregnancy .Saudi Med J. 2008;29:606-609.
2. Worley KC et al. Cunningham FG. Advanced extrauterine pregnancy: Diagnostic and therapeutic challenges. Am J Obstet Gynecol.2008;198(3):297e1-7.
3. Jurkovic D. Diagnosis and management of ectopic pregnancy. British Medical Journal.2011;342:3397.
4. Zhang J et al. Full-term abdominal pregnancy. A case report and review of the literature. Gynecol Obstet Invest. 2008;65(2):139-141.
5. Ang LP et al. Abdominal pregnancy: a case report and literature review. Singapore Med J. 2000;41:454-457.
6. David James et al. High risk pregnancy. Cambridge University Press. New Delhi, India. 5<sup>th</sup> edition. 1527-1531.
7. Nkusu Nonyalulendho D et al. Advance abdominal pregnancy: A case report and review of 163 cases. Rural remote health. 2008;8:1087-1090.
8. Huang K et al. Advanced abdominal pregnancy: An increasingly challenging concern for Obstetricians. Int J Clin Pathol. 2014;7 5461-72.
9. Mengistu et al. term abdominal pregnancy: A case report. J Med Case Rep. 2015;9:168.
10. Bertrand G et al. Imaging in the management of abdominal pregnancy: A case report and review of literature. J Obstet Gynaecol Can: JOGC.2009;31(1):57-62.
11. Amritha B et al. A rare case of term viable secondary abdominal pregnancy following rupture of rudimentary horn: A case report. J Med Case Rep. 2009; 3:33.
12. Masukume G. Live births resulting from advanced abdominal extrauterine pregnancy. A review of cases reported from 2008 to 2013. Webmed central Obstet Gynaecol. 2014 ;5(1).
13. Aliyu LD et al. A multicenter study of advanced abdominal pregnancy. A review of six cases in low resource settings. Europe J Obstet Gynaecol Reprod Biol. 2013; 170:33-38.