

## The Role of Transvaginal Ultrasonography in the Evaluation of Postmenopausal Bleeding

Maherunnessa<sup>1</sup>, Shahana Shermin<sup>2</sup>, Shahnaz Rahman<sup>3</sup>, Nurun Naher<sup>4</sup>, Mehbuba Jahan<sup>5</sup>

### Abstract

**Background:** Endometrial cancer is currently the most common malignancy of the female genital tract. Most of the women with endometrial cancer initially present with postmenopausal bleeding (PMB) and may be assessed initially with either endometrial biopsy or transvaginal ultrasonography. **Objective:** The objective of this study was to evaluate transvaginal ultrasound (TVS) measurement of endometrial thickness (ET) in diagnosing endometrial cancer in women with postmenopausal bleeding. **Materials and method:** This was a prospective study. Transvaginal ultrasonography and Papanicolaou smear were performed in 291 women presenting with postmenopausal bleeding aged >50 years and were followed up for one year in BIRDEM General Hospital from September 2017 to August 2018. **Results:** One hundred and seventeen women had an endometrial thickness  $\leq 4$  mm and one endometrial cancer (0.85%) was diagnosed in this group. Endometrial biopsy was performed in women who had recurrent bleeding. But in women with an endometrial thickness of  $\geq 5$  mm (174 out of 291 women), endometrial cancer was diagnosed in 9.77%, atypical hyperplasia in 5.17%, ovarian malignancy in 1.72% and total malignancy was 17.8%. **Conclusion:** Transvaginal ultrasonography using a  $\leq 4$  mm cut-off has high sensitivity for detecting endometrial cancer and can identify women with PMB who are highly unlikely to have endometrial cancer, thereby avoiding more invasive endometrial biopsy.

**Keywords:** Postmenopausal bleeding; Endometrial cancer; Transvaginal ultrasonography; Endometrial biopsy.

*Delta Med Col J. Jul 2021;9(2):91-95*

### Introduction

Endometrial cancer is currently the most common malignancy of the female genital tract in Europe, USA and Hong Kong. Around 90% of women eventually diagnosed with endometrial cancer initially present with postmenopausal bleeding

(PMB).<sup>1</sup> It is a common problem representing 5% of all gynaecology outpatient attendance.<sup>2</sup> Risk factors for endometrial cancer are exogenous oestrogen, tamoxifen use for breast cancer, polycystic ovarian disease, nulliparity, hereditary

### Author information

1. Associate professor, Department of Obstetrics & Gynaecology, Ibrahim Medical College and BIRDEM General Hospital, Dhaka, Bangladesh.
2. Registrar, Department of Obstetrics & Gynaecology, Ibrahim Medical College and BIRDEM General Hospital, Dhaka, Bangladesh.
3. Assistant professor, Department of Obstetrics & Gynaecology, Ibrahim Medical College and BIRDEM General Hospital, Dhaka, Bangladesh.
4. Registrar, Department of Obstetrics & Gynaecology, Ibrahim Medical College and BIRDEM General Hospital, Dhaka, Bangladesh.
5. Resident Medical Officer, Department of Obstetrics & Gynaecology, BIRDEM General Hospital, Dhaka, Bangladesh.

**Correspondence:** Dr. Maherunnessa. e-mail: mmaherun@gmail.com

nonpolyposis colorectal carcinoma, obesity and diabetes.<sup>3</sup> Management depends upon history and examination by a gynaecologist within two weeks.<sup>4</sup> The clinical approach to postmenopausal bleeding requires prompt and efficient evaluation to exclude or diagnose carcinoma. Women with postmenopausal bleeding may be assessed initially with either endometrial biopsy or transvaginal ultrasonography; this initial evaluation does not require performance of both tests. When transvaginal ultrasonography is performed for patients with postmenopausal bleeding and an endometrial thickness of  $\leq 4$  mm is found, endometrial sampling is not required. When bleeding persists despite negative initial evaluations, additional assessment usually is indicated.

In general, thicker the endometrium, the higher the likelihood of important pathology i.e. endometrial cancer being present. A thickness of  $\geq 5$  mm gives 7.3% likelihood of endometrial cancer.<sup>5</sup> Whereas, thickness of  $\leq 4$  mm has a negative predictive value of 98%.<sup>3</sup> A definitive diagnosis in postmenopausal bleeding is made by histology.

### Materials and method

Two hundred and ninety one women aged  $\geq 50$  years with postmenopausal bleeding were taken from Gynae outpatient department in BIRDEM General Hospital from September 2017 to August 2018 and were followed up for one year. The women were requested to complete a questionnaire that included a general medical history, menstrual history, history of gynaecological operation and menopausal data, the use or nonuse of hormone replacement therapy were recorded. A woman was considered to have PMB if there was an occurrence of bleeding after one completed year of amenorrhoea. Exclusion criteria were, if they: (1) had incidental finding of thickened endometrium on TVS; (2) had fluid inside the uterine cavity; (3) did not have satisfactory endometrial thickness (ET) measurement.

All women underwent a thorough gynaecologic examination and transvaginal ultrasonogram examination for endometrial thickness and

adnexal region to exclude any pelvic mass and also Papanicolaou smear. Women who were found to have an endometrial thickness of  $\geq 5$  mm, underwent endometrial sampling or D & C for endometrial biopsy or total hysterectomy with bilateral salpingoophorectomy. But women who were found to have an endometrial thickness of  $\leq 4$  mm at first visit, were requested to return after 3 months interval upto 12 months for gynaecological and transvaginal ultrasonographic examination. The women were thoroughly informed regarding study and the importance at contacting examining doctor if new bleeding should occur. If there was another episode of vaginal bleeding during follow up period an endometrial biopsy was performed.

### Results

During the period between 2017 and 2018 there were 291 new referrals for postmenopausal bleeding to the Gynae outpatient department in BIRDEM General Hospital. Endometrial thickness was  $\geq 5$  mm in 174 of the 291 women (59.79%).

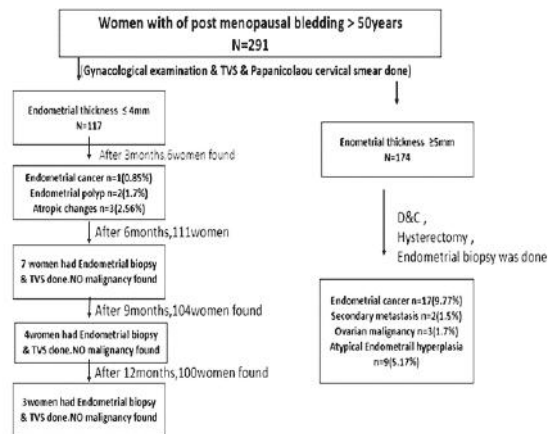
In women with postmenopausal bleeding and  $\geq 5$  mm endometrial thickness, either an endometrial biopsy or D & C or total hysterectomy was done. Seventeen women were found to have a primary endometrial cancer (9.77%), two women had a metastasis in endometrium from primary breast cancer (1.15%), nine women were found to have atypical endometrial hyperplasia (5.17%) and 3(1.72%) women were found to have ovarian cancer (stage I-A). In total 31(17.8%) of 174 women were found to have some form of cancer. Rest of the women 143(82.2%) had no gynaecological malignancy.

One hundred and seventeen women were found to have an endometrial thickness of  $\leq 4$  mm and were followed up at 3 months interval. Six women came with another bleeding episode at the end of 3 months. Transvaginal sonography and endometrial biopsy were done. Two women had endometrial polyp (1.7%), three (2.56%), had atrophic changes of endometrium (endometrial thickness of 3 mm) and one had endometrial carcinoma (0.85%) after hysterectomy (endometrial thickness 4-5 mm).

After 6 months, seven women came with per vaginal bleeding (7 of the 111 women, 6.3% at 9 month visit). Transvaginal ultrasonography and endometrial biopsy were done. Three (2.7%) had atrophic changes of endometrium, endometrium thickness (3 mm, 2 mm, <2 mm), one had endometrial polyp with endometrial thickness of 4 mm (0.9%) and three had simple hyperplasia without atypia (2.7%).

After 9 months, 4 women underwent endometrial biopsy and transvaginal sonography with episode of pervaginal bleeding (4 of the 104 women, 3.8% at 9 month visit). One had atrophic changes of endometrium (0.9%), one had adenomyosis after hysterectomy (0.9%) and two had simple endometrial hyperplasia (1.9%).

At 12 months visit, 3 women came with episode of per vaginal bleeding (3 of the 100 women, 3%). Endometrial biopsy and transvaginal sonography was done. Two had atrophic changes of endometrium (2%) and one had simple endometrial hyperplasia (1%). Two women were not available in this study period. One woman died of cardiac failure and one woman had not been available because she had emigrated. During the follow up period of 1 year, endometrial biopsy was performed in 20(17.09%) of 117 women for the indication of per vaginal bleeding. Rest of the 95 women had no per vaginal bleeding during 1 year follow up period.



**Fig. 1: Schematic description of study design and main results. TVS – Transvaginal ultrasonography. In total, 194(66.66%) of 291 women underwent biopsy during the study**

## Discussion

In this study, endometrial cancer was diagnosed in 1 of the 117(0.85%) of woman who had an endometrial thickness of  $\leq 4$  mm, versus 17(9.77%) of the 174 women who had an endometrial thickness of  $\geq 5$  mm. No endometrial cancer was subsequently diagnosed in 116 of 117 women with an endometrial thickness of  $\leq 4$  mm during the 1 year follow up period after the initial transvaginal ultrasonographic examination. This study confirms earlier reports that endometrial cancer is an uncommon finding among women with a thin endometrium as measured by transvaginal ultrasonography.<sup>6-26</sup>

Traditionally curettage procedure and in more recent years, other simpler endometrial biopsy techniques have been used in the diagnosis of postmenopausal bleeding or irregular bleeding during hormone replacement therapy. It has been reported that a curettage procedure carries a false negative rate of between 2% and 6% for diagnosis of endometrial cancer and hyperplasia.<sup>27,28</sup> This is perhaps not an unreasonable findings, because curettage is a blind procedure and in approximately 60% of curettage procedures less than half of the uterine cavity is actually curatted.<sup>27</sup>

Hysteroscopy has been shown to be very accurate for diagnosis of endometrial disorder.<sup>28-30</sup> Technical improvements and video techniques have made this method more suitable for office use. It is, however, still a rather invasive method that carries a false negative rate of 3% and complication may occur.<sup>30</sup> In this study the false negative rate for transvaginal ultrasonography alone was only 0.85%.

This analysis illustrates two important points. First, endometrial cancer will occasionally be missed when a cut off value of  $\leq 4$  mm is used as shown in some studies.<sup>21,22</sup> However, the number of missed cancer does not appear to be greater than that reported for curettage or endometrial biopsy techniques. Second, this study also illustrates the value of performing a Papanicolaou cervical smear not only for diagnosis of cervical cancer but

also for diagnosis of endometrial abnormalities. Most women with endometrial cancer have postmenopausal bleeding as the first symptom and there generally are not repeated bleeding episodes.<sup>31</sup>

It has been estimated that about 10% of women with postmenopausal bleeding are subsequently found to have an endometrial carcinoma and a further 20% to 40% have hyperplasia and endometrial polyp or some other endometrial pathologic condition as the cause of the bleeding.<sup>20,21</sup> Thus most women with postmenopausal bleeding (50% - 60%) will have bleeding related to a benign condition which will be confirmed as such on examination of the biopsy specimen.<sup>20,21,32</sup> Once cervical lesion has been excluded, the cause of the bleeding is usually considered to be fragility of blood vessels in the thin atrophic mucosa of the endometrium or vaginal skin.<sup>8,33</sup>

Previous studies have suggested that endometrial cancer and other endometrial pathologic conditions are extremely uncommon among the women in whom the endometrial thickness is  $\leq 5$  mm.<sup>6-26</sup> The result of this study supports the argument that transvaginal ultrasonography is at least as effective as endometrial biopsy techniques as a means of excluding serious pathologic conditions along with postmenopausal bleeding in whom endometrial thickness is  $\leq 4$  mm.

### Conclusions

Transvaginal ultrasonography using a  $\leq 4$  mm cut off has high sensitivity for detecting endometrial cancer and can identify women with postmenopausal bleeding who are highly unlikely to have endometrial cancer, thereby avoiding more invasive endometrial biopsy.

### References

1. American College of Obstetricians and Gynaecologists. The Role of Transvaginal Ultrasonography in the Evaluation of Postmenopausal Bleeding. ACOG Comm Opin No. 440. *Obstet Gynecol.* 2009 (reaffirmed 2013); 114:409-11.
2. Moodley M, Roberts C. Clinical Pathway for the Evaluation of Postmenopausal Bleeding with an Emphasis on Endometrial Cancer Detection. *J Obstet Gynaecol.* 2004;24(7):736-41. [abstract]
3. Sahdev A. Imaging the Endometrium in Postmenopausal Bleeding. *BMJ.* 2007; 334(7594):635-36.
4. National Institute for Health and Clinical Excellence. Referral for Suspected Cancer - NICE Guideline. CG27. London: NICE; 2005.
5. Smith-Bindman R, Weiss E, Feldstein V. How Thick is Too Thick? When Endometrial Thickness Should Prompt Biopsy in Postmenopausal Women without Vaginal Bleeding. *Ultrasound Obstet Gynecol.* 2004;24(5):558-65. [abstract]
6. Fleischer AC, Kalemeris GC, Machin JE, Entmann SS, James AF Jr. Sonographic Depiction of Normal and Abnormal Endometrium with Histopathological Correlation. *J Ultrasound Med.* 1986;5:445-52.
7. Goldstein S, Nachtigall M, Snyder J, Nachtigall I. Endometrial Assessment by Vaginal Ultrasonography before Endometrial Sampling in Patients with Postmenopausal Bleeding. *Am J Obstet Gynecol.* 1990;163:11923.
8. Malpani A, Singer J, Wolverson M, Merenda G. Endometrial Hyperplasia: Value of Endometrial Thickness in Ultrasonographic Diagnosis and Clinical Significance. *J Clin Ultrasound.* 1990;18:173-77.
9. Osmers R, Vollson M, Schaner A. Vaginosonography for Early Detection of Endometrial Carcinoma. *Lancet.* 1990;335:1569-71.
10. Rudelstorfer R, Nanz S, Bernaschek G. Vaginography and Its Diagnostic Value in Patients with Postmenopausal Bleeding. *Arch Gynecol Obstet.* 1990;248:37-44.
11. Granberg S, Wikland M, Kulsson B, Norstrom A, Friberg IG. Endometrial Thickness as Measured by Endovaginal Ultrasonography for Identifying Endometrial Abnormalities. *Am J Obstet Gynecol.* 1991;164:17-32.
12. Nasri MN, Shepherd JII, Setchell MF, Lowe DG, Chard T. Sonographic Depiction of Postmenopausal Endometrium with Transabdominal and Transvaginal Scanning. *Ultrasound Obstet Gynecol.* 1991;1:279-83.



13. Bourne TH, Grayford T, Hampson J, Collins WP, Campbell S. The Detection of Endometrial Cancer by Transvaginal Ultrasonography Colour Doppler. *Ultrasound Obstet Gynecol.* 1992;2:75.
14. Abu Hmeidan F, Bilek K, Baier D, Nuwayhid M, Kade R. Das Sonographischebild des Endometrium Karzinoms. *Ultraschall Med.* 1992; 13:178-82.
15. Botsis D, Kassamos D, Pyrgitis E, Zomlas PA. Vaginal Sonography of Endometrium in Postmenopausal Women. *Clin Exp Obstet Gynecol.* 1992;19:189-92.
16. Auslender R, Bornstein J, Dirnfeld M, Kogan O, Atad J, Abramovici H. Vaginal Ultrasonography n Patients with Post Menopausal Bleeding. *Ultrasound Obstet Gynecol.* 1993;30:126-28.
17. Dorum A, Kristensen GB, Langebrekke A, Sornes T, Skarr O. Evaluation of Endometrial Thickness Measured by Endovaginal Ultrasound in Women with Postmenopausal Bleeding. *Acta Obstet Gynecol Scan.* 1993;72:116-19.
18. Bakos O, Smith P, Heimer G. Transvaginal Ultrasonography for Identifying Endometrial Pathology in Postmenopausal Women. *Maturitas.* 1994;20:1819.
19. Sladcevins P, Valentin I, Marsal K. Endometrial thickness and Doppler Velocimetry of the Uterine Arteries as Discriminators of Endometrial Status in Women with Postmenopausal Bleeding: A Comparative Study. *Am J Obstet Gynecol.* 1994;171:722-28.
20. Karlsson B, Granberg S, Wikland M, Ylostalo P, Kisernd T, Marsal K, et al. Transvaginal Ultrasonography of the Endometrium in Women with Postmenopausal Bleeding - A Nordic Multicenter Study. *Am J Obstet Gynecol.* 1995;172:1488-94.
21. Ferrazzi E, Torri V, Trio D, Zannoni F, Filiberto S, Dordoni D. Sonographic Endometrial Thickness a Useful Test to Predict Atrophy in Patients with Postmenopausal Bleeding: An Italian Multicenter Study. *Ultrasound Obstet Gynecol.* 1996;7:31521.
22. Kufahl J, Pedersen I, Sindberg Eriksen P, Helkjaer PE, Larsen LG, Jensen KL, et al. Transvaginal Ultrasound, Endometrial Cytology Sampled by Gynoscann and Histology Obtained by Uterine Explora Curette Compared to the Histology of the Uterine Specimen: A Prospective Study in Pre and Postmenopausal Women Undergoing Elective Hysterectomy. *Acta Obstet Gynecol Scand.* 1997;76:7 90-96.
23. Mateos F, Zarauz R, Seco C, Rayward JR, del Barrio P, Aguirre J, et al. Assessment with Transvaginal Ultrasonography of Endometrial Thickness in Women with Postmenopausal Bleeding. *Eur J Gynaecol Oncol.* 1997;18:501-507.
24. Briley M, Lindsell D. The Role of Transvaginal Ultrasound in the Investigation of Women with Postmenopausal Bleeding. *Clin Radiol.* 1998;53:502-505.
25. Weber G, Merz F, Bahhmann E, Roseh B. Evaluation of Different Transvaginal Sonographic Diagnostic Parameters in Women with Postmenopausal Bleeding. *Ultrasound Obstet Gynecol.* 1998;12:265-70.
26. Granberg S, Friberg LG, Norstorm A, Wikland M. Endovaginal Ultrasound Scanning of Women with Postmenopausal Bleeding. *J Ultrasound Med.* 1998;7:283.
27. Stock RJ, Kanbour A. Prehysterectomy Curettage. *Obstet Gynecol.* 1975;15:53711.
28. Mackenzie IZ, Bibby JG. Critical Assessment of Dilatation and Curettage 1029 Women. *Lancet.* 1978;2:566-68.
29. Stowall TG, Solomon SK, Ling FW. Endometrial Sampling Prior to Hysterectomy. *Obstet Gynecol.* 1989;73:105-109.
30. Gampleson RJ, Rappold HO. A Comparative Study between Panoramic Hysteroscopy with Directed Biopsies and Dilatation and Curettage. *Am J Obstet Gynecol.* 1988;158:189-92.
31. Parsons A, Lens II. Sonography for Endometrial Abnormalities Preliminary Results. *J Clin Ultrasound.* 1993;21:87-95.
32. Hoist J, Koskela O, Von Schonltz B. Endometrial Findings Following Curettage in 2018 Women According to Age and Indications. *Ann Chin Gynecol.* 1983;72:271-77.
33. Choo YG, Mak KG, Iisu G, Wong TS, Ma HK. Postmenopausal Uterine Bleeding of Nonorganic Cause. *Obstet Gynecol.* 1986;66:225-28.